POSTGRADDC

EVIDENCE BASED, CLINICALLY INTUITIVE CE

The PostGradDC CeAD Certification ©

James Demetrious, DC, DABCO

Diplomate, American Board of Chiropractic Orthopedists

www.PostGradDC.com

1

NCMIC

WE TAKE CARE OF **OUR OWN**.



James Demetrious, DC, DABCO

NCMIC Speakers' Bureau

2

WE TAKE CARE OF OUR OWN®

DISCLAIMER

- The views and opinions expressed in this presentation are those of the author and do not necessarily reflect the views or policies of NCMIC.
- This educational activity is supported by NCMIC. NCMIC does not establish or dictate clinical practice standards, nor do they dictate the contents of this presentation.
- The information presented is intended solely for educational purposes and is not a substitute for independent clinical judgement, professional training, or applicable regulations.

3

James Demetrious, DC, DABCO

Clinician
- Actively Practiced 40 years
- Diplomate, American Board of Chiropractic Orthopedists
- Diplomate, International Academy of Neuromusculoskeletal Medicine

Publications
- 35 Peer-reviewed chiropractic journal articles.
- Many Contributions to NCMIC Examiner and Podcast

Educator
- Post-Grad. > 26 years
- NCMIC Speakers' Bureau for 14 years
- Northeast College of Health Sciences
- **PostGradDC**

Editorial
- Editorial Reviewer for journals *Spine*, *Annals of Internal Medicine*, and *Clinical Anatomy*
- Former Managing Editor of *Journal of Chiropractic Orthopedists*

Honors
- Academy of Chiropractic Orthopedists Distinguished Service and Fellow Awards
- American College of Chiropractic Orthopedists Outstanding Achievement Award

Community
- Lower Cape Fear Hospice, Board Member
- Founder, Past-President Wilmington Autism Society
- Optimists Club – Safety Officer

4

Disclosures

- Dr. Demetrious owns and operates **PostGradDC.com**, a company that offers advanced online post-graduate continuing education.
- Dr. Demetrious is an independent member of the **NCMIC** Speakers' Bureau. He teaches advanced continuing education course work throughout the United States.
- Text and graphics on the following slides are presented for educational purposes. Meticulous references and attribution have been made to respective authors and copyright holders.

POSTGRADDC
EVIDENCE BASED, CLINICALLY INTUITIVE CE

5

Disclaimer

- The views and opinions expressed in this presentation are solely those of the author.
- **Dr. Demetrious and PostGradDC do not set practice standards.**
- **NCMIC does not set practice standards.**
- We offer this only to educate and inform.

POSTGRADDC
EVIDENCE BASED, CLINICALLY INTUITIVE CE

6

NCMIC

Earn NCMIC Premium Discounts

Full-time D.C.s can attend an 8-hour qualifying seminar and receive a 5% discount for 3 consecutive years on the renewal of their malpractice insurance premium (2.5% discount for part-time D.C.s).

To receive the discount, the DC can email or fax a copy of their CE form to NCMIC.

7

Qualified?



8

Qualified?

Demetrious *Chiropractic & Manual Therapies* (2018) 26:22
https://doi.org/10.1186/s12998-018-0193-z

Chiropractic & Manual Therapies

HYPOTHESIS | Open Access

Spontaneous cervical artery dissection: a fluoroquinolone induced connective tissue disorder?

James S. Demetrious

Dr. Demetrious was the first person to ever publish that medication can weaken the cervical arteries and cause strokes. His hypothesis has been initially confirmed by three independent researchers.

> Eur J Neurol. 2019 Jul;26(7):1028-1031. doi: 10.1111/ene.13917. Epub 2019 Mar 5.

Use of fluoroquinolones and the risk of spontaneous cervical artery dissection

E Del Zotto [1], A Pezzini [1 2]

Case Reports > Intern Med. 2021 Sep 1;60(17):2863-2865.
doi: 10.2169/internalmedicine.6736-20. Epub 2021 Mar 22.

Vertebral Artery Dissection after Exposure to Levofloxacin: A Report of Two Cases

Taku Harada [1 2], Yukinori Harada [2], Taro Shimizu [2]

Archives of Cardiovascular Diseases Supplements

Fluoroquinolone use preceding medium-size artery dissection: A case series

POSTGRADDC
EVIDENCE BASED, CLINICALLY INTUITIVE CE

James Demetrious, DC, DABCO - PostGradDC.com

7

9

Spaced Repetition and Retrieval-Based Learning

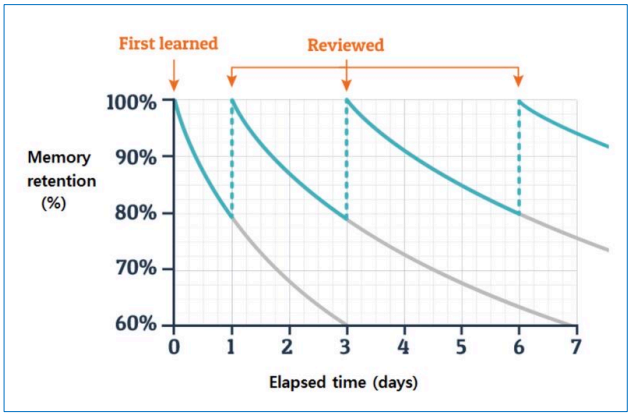

JACR | Journal of the American College of Radiology

ORIGINAL ARTICLE · Volume 22, Issue 1, P15-21, January 2025

Download Full Issue

Spaced Repetition Learning in Radiology Education: Exploring Its Potential and Practical Application

Kaelan Yao, MS [a] · Jeffers Nguyen, MD [b] · Mahan Mathur, MD [c]

Affiliations & Notes | Article Info | Linked Articles (1)

a Yale School of Medicine, New Haven, Connecticut
b Yale Department of Radiology and Biomedical Imaging, New Haven, Connecticut
c Associate Professor of Radiology and Biomedical Imaging, Vice Chair of Education, Director of Medical Education in Radiology, Yale Department of Radiology and Biomedical Imaging, Yale School of Medicine, New Haven, Connecticut, Editor-in-Chief, Standardized Tool for the Assessment of Radiology Students (STARS), American College of Radiology

Abstract

In today's medical landscape, rapidly learning vast amounts of information requires innovative learning methods. Spaced repetition tools (like Anki) aid efficient knowledge absorption and retention among medical trainees. Yet,

POSTGRADDC
EVIDENCE BASED, CLINICALLY INTUITIVE CE

James Demetrious, DC, DABCO

10

10

Certification Examination

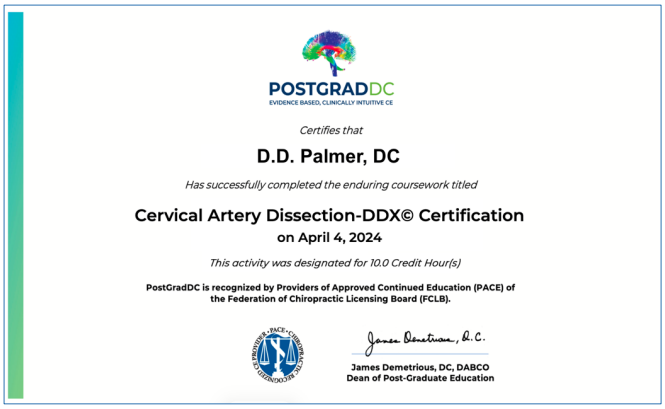

POSTGRADDC
EVIDENCE BASED, CLINICALLY INTUITIVE CE

Certifies that

D.D. Palmer, DC

Has successfully completed the enduring coursework titled

Cervical Artery Dissection-DDX© Certification
on April 4, 2024

This activity was designated for 10.0 Credit Hour(s)

PostGradDC is recognized by Providers of Approved Continued Education (PACE) of the Federation of Chiropractic Licensing Board (FCLB).

James Demetrious, DC, DABCO
Dean of Post-Graduate Education

- Upon completion of the 10 hours of certification coursework, the ACCO will verify your attendance and eligibility for our PostGradDC Cervical Artery Dissection certification examination.
- An email with a hyperlink will be sent to eligible doctors to purchase the certification examination through PostGradDC.
- The fee for the examination is $150 (normally $250 but discounted for this event).
- Upon successful completion of the examination, your certificate will be available for download and maintained at PostGradDC.com.

11

Epidemiology



Stroke

CLINICAL AND POPULATION SCIENCES

Epidemiology of Spontaneous Cervical Artery Dissection: Population-Based Study

Kim J. Griffin, MD; William S. Harmsen, MS; Jay Mandrekar, PhD; Robert D. Brown Jr, MD; Zafer Keser, MD

BACKGROUND: Cervical artery dissection (CeAD) represents up to 15% to 25% of ischemic strokes in people under the age of 50 years. Noninvasive vessel imaging is increasingly used in clinical practice, but the impact on the frequency of detection of CeAD is unknown. In 2006, the yearly incidence rate of CeAD was estimated at 2.6 per 100 000 person-years, but the current incidence is unknown.

METHODS: In this population-based retrospective observational cohort study, we utilized the resources of the Rochester Epidemiology Project to ascertain all adult residents of Olmsted County, MN, diagnosed with internal carotid artery dissection and common carotid artery dissection or vertebral artery dissection from 2002 to 2020. Patients with only intracranial involvement or CeAD following major trauma were excluded. Age-adjusted sex-specific and age- and sex-adjusted incidence rates were estimated using the US White 2010 decennial census, with rates expressed per 100 000 person-years. We assessed longitudinal trends by dividing the data into 5-year time intervals, with the last being a 4-year interval.

RESULTS: We identified 123 patients with a diagnosis of CeAD. There were 63 patients with internal carotid artery dissection, 54 with vertebral artery dissection, 2 with concurrent internal carotid artery dissection and vertebral artery dissection, and 4 with common carotid artery dissection. There were 63 (51.2%) female patients and 60 (48.8%) male patients. The average age at diagnosis was 50.2 years (SD, 15.1 [95% CI, 20.1–90.5] years). The incidence rate of spontaneous CeAD encompassing all locations was 4.69 per 100 000 person-years (2.43 for internal carotid artery dissection and 2.01 for vertebral artery dissection). The incidence rate increased from 2.30 per 100 000 person-years from 2002 to 2006 to 8.93 per 100 000 person-years from 2017 to 2020 (P<0.0001). The incidence rate for female patients rose from 0.81 per 100 000 person-years from 2002 to 2006 to 10.17 per 100 000 person-years from 2017 to 2020.

CONCLUSIONS: The incidence rate of spontaneous CeAD increased nearly 4-fold over a 19-year period from 2002 to 2020. The incidence rate in women rose over 12-fold. The increase in incidence rates likely reflects the increased use of noninvasive vascular imaging.

GRAPHIC ABSTRACT: A graphic abstract is available for this article.

Key Words: adult ■ arteries ■ dissection ■ epidemiologic studies ■ incidence ■ neck pain ■ stroke

Cervical artery dissection (CeAD) is an uncommon cause of ischemic stroke. However, in adults under the age of 50 years, CeADs represent up to 15% to 25% of ischemic strokes.[1] CeAD often presents with local compressive symptoms, such as headache/neck pain and Horner syndrome, but many remain asymptomatic.[2]

This diversity in presentations contributes to a scarcity of epidemiological data for CeAD. A study from the Dijon Stroke Registry noted a raw incidence rate of ≈2.97 per 100 000/y, but there are otherwise limited recent data.[3,4] Many key epidemiological studies are decades old. Our institution previously reported the incidence of spontaneous internal carotid artery dissections (ICADs) in 1965,

Correspondence to Zafer Keser, MD, Department of Neurology, Cerebrovascular Division Mayo Clinic, 200 First St, SW, Rochester, MN 55902. Email keser.zafer@mayo.edu

This manuscript was sent to Emmanuel Touzé, Guest Editor, for review by expert referees, editorial decision, and final disposition.

Supplemental Material is available at https://www.ahajournals.org/doi/suppl/10.1161/STROKEAHA.123.043647.

For Sources of Funding and Disclosures, see page 676.

© 2024 American Heart Association, Inc.

Stroke is available at www.ahajournals.org/journal/str

670 March 2024 *Stroke*. 2024;55:670–677. DOI: 10.1161/STROKEAHA.123.043647

Downloaded from http://ahajournals.org by on March 14, 2024

- The incidence rate increased from 2.30 per 100 000 person-years from 2002 to 2006 to 8.93 per 100 000 person-years from 2017 to 2020 (P<0.0001).

12

Epidemiology

RESEARCH ARTICLE

Incidence Trends and Risk of Recurrent Stroke of Cervical Artery Dissections in the United States Between 2005 and 2019

Liqi Shu, MD,* Lukas Sinekrby, MD,* Adam de Havenon, MD, Thanh N. Nguyen, MD, Nils Henninger, MD, Zafer Keser, MD, Muhib Khan, MD, James Ernest Siegler, MD, Mary Penckofer, PhD, Setareh Salehi Omran, MD, Thalia S. Field, MD, Lily Zhou, MD, Han Xiao, MD, Austin Jacobsen, BS, Eric D. Goldstein, BS, Christoph Stretz, BS, Farhan Khan, BS, Elisabeth Perelstein, BS, Karen Furie, MD, and Shadi Yaghi, MD

Correspondence
Dr. Yaghi
shadiyaghi@yahoo.com

Neurology® 2025;104:e213548. doi:10.1212/WNL.0000000000213548

MORE ONLINE
Supplementary Material

Abstract

Background and Objectives
Cervical artery dissection (CeAD) is a common cause of acute ischemic stroke (AIS), especially in patients younger than 55 years, but data regarding trends and subsequent AIS risk after CeAD remain scarce. We aimed to determine national trends in CeAD admissions and examine post-CeAD risk of ischemic stroke.

Methods
We used the National Inpatient Sample (2005–2019), National Readmission Database (2015–2019), and State Inpatient Database for New York (2011–2017) and Florida (2011–2019). Adult patients with spontaneous CeAD were identified using *International Classification of Diseases, Ninth Revision, Clinical Modification* and *International Classification of Diseases, Tenth Revision, Clinical Modification* codes. Survey-weighted annual CeAD cases were combined with US census data to estimate annual incidence. National estimates were verified with state-level data, which allows for the removal of duplicate admissions for a single patient through a unique patient identifier. Joinpoint regression was used to quantify the average annual percent change (AAPC) of CeAD incidence. AIS readmission risk after CeAD without concurrent AIS was assessed with death as a competing risk using Fine and Gray competing risk methodology.

Results
From 2005 to 2019, we identified 125,102 patients (46.09% female, mean age 51.4 years) with spontaneous CeAD. CeAD incidence increased from 10.7 cases per million population in 2005 to 43.6 cases per million population in 2019, revealing an AAPC of 10.21% (95% CI 9.67%–10.76%). This substantial increase in CeAD admissions was particularly high in the older, Black, and Hispanic populations. Statewide data corroborated this upward trend with an AAPC of 8.47% (95% CI 7.97%–8.48%). Among patients with CeAD without AIS, vertebral artery dissection was the sole major predictor of subsequent ischemic stroke risk within 90 days (adjusted subdistributed hazard ratio 1.77, 95% CI 1.18–2.64, $p = 0.006$). Interaction and subgroup analyses were performed and demonstrated similar results.

Discussion
There was an almost 5-fold increase in CeAD hospitalizations and an upward incidence trend from 2005 to 2019, particularly in racial minorities, which may be attributed to increased imaging and awareness of CeAD. Our study also revealed a small but significant risk of AIS in patients with vertebral artery dissection without concurrent ischemic stroke. These findings underscore the importance of studying acute treatment and secondary prevention strategies in patients with CeAD.

*These authors contributed equally to this work.

†Department of Neurology, The Warren Alpert Medical School of Brown University, Providence, RI, ‡Department of Neurology, Center for Brain and Mind Health, Yale School of Medicine, New Haven, CT, §Department of Neurology, Harvard Medical School, University School of Medicine, MA, ¶Department of Neurology, University of Massachusetts Chan Medical School, Worcester, #Department of Psychiatry, University of Massachusetts Chan Medical School, Worcester, **Department of Neurology, Mayo Clinic, Rochester, MA, ††Department of Neurology, University of Chicago, IL, ‡‡Department of Neurology, University of Colorado, Aurora, §§Division of Neurology, Vancouver Stroke Program, University of British Columbia, Vancouver, Canada, and ¶¶University of California, Santa Barbara.

Copyright © 2025 American Academy of Neurology

Figure 1 Estimated Incidence of CeAD in the United States From 2005 to 2019

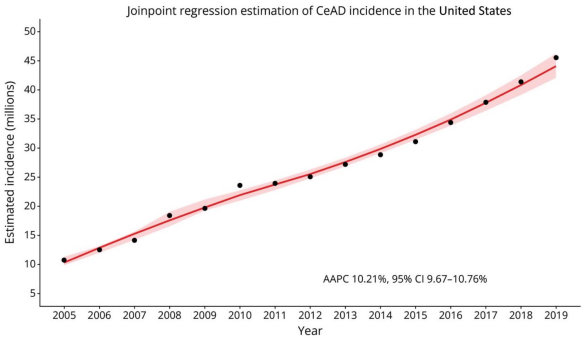

A regression line was fit using joinpoint regression and displayed with 95% CIs. AAPC = average annual percent change; CeAD = cervical artery dissection.

13

Epidemiology

RESEARCH ARTICLE

Incidence Trends and Risk of Recurrent Stroke of Cervical Artery Dissections in the United States Between 2005 and 2019

Liqi Shu, MD,* Lukas Sinekrby, MD,* Adam de Havenon, MD, Thanh N. Nguyen, MD, Nils Henninger, MD, Zafer Keser, MD, Muhib Khan, MD, James Ernest Siegler, MD, Mary Penckofer, PhD, Setareh Salehi Omran, MD, Thalia S. Field, MD, Lily Zhou, MD, Han Xiao, MD, Austin Jacobsen, BS, Eric D. Goldstein, BS, Christoph Stretz, BS, Farhan Khan, BS, Elisabeth Perelstein, BS, Karen Furie, MD, and Shadi Yaghi, MD

Correspondence
Dr. Yaghi
shadiyaghi@yahoo.com

Neurology® 2025;104:e213548. doi:10.1212/WNL.0000000000213548

MORE ONLINE
Supplementary Material

Abstract

Background and Objectives
Cervical artery dissection (CeAD) is a common cause of acute ischemic stroke (AIS), especially in patients younger than 55 years, but data regarding trends and subsequent AIS risk after CeAD remain scarce. We aimed to determine national trends in CeAD admissions and examine post-CeAD risk of ischemic stroke.

Methods
We used the National Inpatient Sample (2005–2019), National Readmission Database (2015–2019), and State Inpatient Database for New York (2011–2017) and Florida (2011–2019). Adult patients with spontaneous CeAD were identified using *International Classification of Diseases, Ninth Revision, Clinical Modification* and *International Classification of Diseases, Tenth Revision, Clinical Modification* codes. Survey-weighted annual CeAD cases were combined with US census data to estimate annual incidence. National estimates were verified with state-level data, which allows for the removal of duplicate admissions for a single patient through a unique patient identifier. Joinpoint regression was used to quantify the average annual percent change (AAPC) of CeAD incidence. AIS readmission risk after CeAD without concurrent AIS was assessed with death as a competing risk using Fine and Gray competing risk methodology.

Results
From 2005 to 2019, we identified 125,102 patients (46.09% female, mean age 51.4 years) with spontaneous CeAD. CeAD incidence increased from 10.7 cases per million population in 2005 to 43.6 cases per million population in 2019, revealing an AAPC of 10.21% (95% CI 9.67%–10.76%). This substantial increase in CeAD admissions was particularly high in the older, Black, and Hispanic populations. Statewide data corroborated this upward trend with an AAPC of 8.47% (95% CI 7.97%–8.48%). Among patients with CeAD without AIS, vertebral artery dissection was the sole major predictor of subsequent ischemic stroke risk within 90 days (adjusted subdistributed hazard ratio 1.77, 95% CI 1.18–2.64, $p = 0.006$). Interaction and subgroup analyses were performed and demonstrated similar results.

Discussion
There was an almost 5-fold increase in CeAD hospitalizations and an upward incidence trend from 2005 to 2019, particularly in racial minorities, which may be attributed to increased imaging and awareness of CeAD. Our study also revealed a small but significant risk of AIS in patients with vertebral artery dissection without concurrent ischemic stroke. These findings underscore the importance of studying acute treatment and secondary prevention strategies in patients with CeAD.

*These authors contributed equally to this work.

†Department of Neurology, The Warren Alpert Medical School of Brown University, Providence, RI, ‡Department of Neurology, Center for Brain and Mind Health, Yale School of Medicine, New Haven, CT, §Department of Neurology, Harvard Medical School, University School of Medicine, MA, ¶Department of Neurology, University of Massachusetts Chan Medical School, Worcester, #Department of Psychiatry, University of Massachusetts Chan Medical School, Worcester, **Department of Neurology, Mayo Clinic, Rochester, MA, ††Department of Neurology, University of Chicago, IL, ‡‡Department of Neurology, University of Colorado, Aurora, §§Division of Neurology, Vancouver Stroke Program, University of British Columbia, Vancouver, Canada, and ¶¶University of California, Santa Barbara.

Copyright © 2025 American Academy of Neurology

Figure 2 Cumulative Incidence of Acute Ischemic Stroke

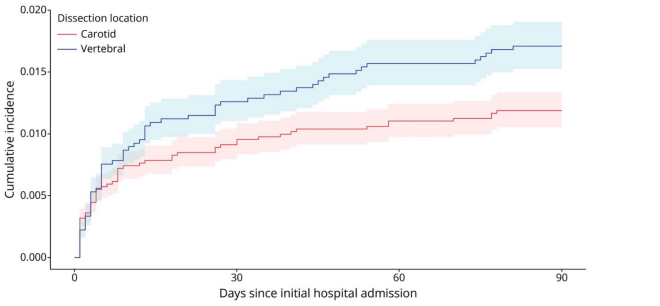

Cumulative incidence graph illustrating acute ischemic stroke risk after cervical artery dissection in patients with carotid versus vertebral dissection and without concurrent ischemic stroke. Patients with vertebral artery dissection without concurrent ischemic stroke demonstrated a higher cumulative incidence of acute ischemic stroke across the entire 90-day follow-up period.

14

Epidemiology – VA v. CA



Stroke

CLINICAL AND POPULATION SCIENCES

Epidemiology of Spontaneous Cervical Artery Dissection: Population-Based Study

Kim J. Griffin, MD; William S. Harmsen, MS; Jay Mandrekar, PhD; Robert D. Brown Jr, MD; Zafer Keser, MD

BACKGROUND: Cervical artery dissection (CeAD) represents up to 15% to 25% of ischemic strokes in people under the age of 50 years. Noninvasive vessel imaging is increasingly used in clinical practice, but the impact on the frequency of detection of CeAD is unknown. In 2006, the yearly incidence rate of CeAD was estimated at 2.6 per 100 000 person-years, but the current incidence is unknown.

METHODS: In this population-based retrospective observational cohort study, we utilized the resources of the Rochester Epidemiology Project to ascertain all adult residents of Olmsted County, MN, diagnosed with internal carotid artery dissection and common carotid artery dissection or vertebral artery dissection from 2002 to 2020. Patients with only intracranial involvement or CeAD following major trauma were excluded. Age-adjusted sex-specific and age- and sex-adjusted incidence rates were estimated using the US White 2010 decennial census, with rates expressed per 100 000 person-years. We assessed longitudinal trends by dividing the data into 5-year time intervals, with the last being a 4-year interval.

RESULTS: We identified 123 patients with a diagnosis of CeAD. There were 63 patients with internal carotid artery dissection, 54 with vertebral artery dissection, 2 with concurrent internal carotid artery dissection and vertebral artery dissection, and 4 with common carotid artery dissection. There were 63 (51.2%) female patients and 60 (48.8%) male patients. The average age at diagnosis was 50.2 years (SD, 15.1 [95% CI, 20.1–80.3] years). The incidence rate of spontaneous CeAD encompassing all locations was 4.59 per 100 000 person-years (2.43 for internal carotid artery dissection and 2.01 for vertebral artery dissection). The incidence rate increased from 2.20 per 100 000 person-years from 2002 to 2006 to 8.33 per 100 000 person-years from 2017 to 2020 (P<0.0001). The incidence rate for female patients rose from 0.81 per 100 000 person-years from 2002 to 2006 to 10.17 per 100 000 person-years from 2017 to 2020.

CONCLUSIONS: The incidence rate of spontaneous CeAD increased nearly 4-fold over a 19-year period from 2002 to 2020. The incidence rate in women rose over 12-fold. The increase in incidence rates likely reflects the increased use of noninvasive vascular imaging.

GRAPHIC ABSTRACT: A graphic abstract is available for this article.

Key Words: adult ■ arteries ■ dissection ■ epidemiologic studies ■ incidence ■ neck pain ■ stroke

Cervical artery dissection (CeAD) is an uncommon cause of ischemic stroke. However, in adults under the age of 50 years, CeADs represent up to 15% to 25% of ischemic strokes.[1,2] CeAD often presents with local compressive symptoms, such as headache/neck pain and Horner syndrome, but many remain asymptomatic.[3]

This diversity in presentations contributes to a scarcity of epidemiological data for CeAD. A study from the Dijon Stroke Registry noted a raw incidence rate of ≈2.97 per 100 000/y, but there are otherwise limited recent data.[4] Many key epidemiological studies are decades old. Our institution previously reported the incidence of spontaneous internal carotid artery dissections (ICADs) in 1993,

Correspondence to: Zafer Keser, MD, Department of Neurology, Cerebrovascular Division Mayo Clinic, 200 First St, SW, Rochester, MN 55903. Email

This manuscript was sent to Emmanuel Touzé, Guest Editor, for review by expert referees, editorial decision, and final disposition.

Supplemental Material is available at https://www.ahajournals.org/doi/suppl/10.1161/STROKEAHA.123.043647.

For Sources of Funding and Disclosures, see page 678.

© 2024 American Heart Association, Inc.

Stroke is available at www.ahajournals.org/journal/str

670 March 2024 Stroke. 2024;55:670–677. DOI: 10.1161/STROKEAHA.123.043647

- The predilection for thrombus formation in VAD may be attributed to the distinctive hemodynamic stress induced by the anatomical and physiologic attributes of the vertebral arteries.
- The relatively diminutive caliber of these vessels, their intricate trajectory, and susceptibility to turbulent flow collectively heighten the risk of thrombus development after dissection.27,28
- Furthermore, the posterior circulation's compact architecture, responsible for numerous critical functions, indicates that even minor embolic events can result in significant clinical manifestations.
- By contrast, the anterior circulation, which encompasses extensive cognitive domains, may harbor silent embolic strokes after carotid dissection, leading to underdiagnosis.29
- Notably, carotid artery dissection typically necessitates thrombus embolization or complete occlusion to result in a stroke.
- However, VAD can precipitate stroke by obstructing perforating arteries, potentially causing infarctions in the pontomedullary region or even the spinal cord, independently of thromboembolic events. 30

15

Perspective?



16

Risk Factors for CeAD and Related Stroke



Trager et al. Chiropractic & Manual Therapies (2026) 34:53
https://doi.org/10.1186/s12998-026-00678-4

Chiropractic & Manual Therapies

RESEARCH Open Access

Association between spinal manipulative therapy and cervical artery dissection in patients with neck pain or headache: a retrospective cohort study

Robert J. Trager[1,2,3*], Anthony N. Baumann[4,5], Collin M. Labak[6], Kelsey L. Lewis[1], Jaime Abraham Perez[7], Christine M. Goertz[8,9] and Andres Schuster[10]

Abstract

Objectives Cervical artery dissection (CeAD) has been proposed as a sequela of spinal manipulative therapy (SMT); however, protopathic bias arising from care-seeking for CeAD symptoms (e.g., neck pain/headache) may overestimate observed associations. Among adults experiencing new neck pain/headache, we tested the null hypothesis of no significant CeAD risk within 30 days following SMT compared to matched ibuprofen-prescribed controls.

Methods We searched United States TriNetX Linked health records/claims data (2010–2025) for adults seeking care for new episodes of neck pain/headache receiving (1) chiropractor-administered cervical SMT or (2) outpatient visit with ibuprofen prescription, excluding those with previous cerebrovascular disease and/or CeAD, using propensity matching to minimize confounding. We examined the risk ratio (RR) of CeAD (primary outcome), exploring cumulative incidence, CeAD subtypes, absolute risk difference (RD), and negative control outcomes.

Results After matching, there were 431,492 patients per cohort. In the SMT cohort, compared with the ibuprofen cohort, CeAD risk was lower while RD was minimal [95% CI] (RR = 0.53 [0.35, 0.83], RD=−6.3 [−10.8, -2.0] events per 100,000 patients; $P = 0.004$). Carotid artery dissection risk was lower; vertebral artery dissection risk was not significantly different. Data-quality supported balanced confounders and minimal follow-up loss (< 3%). Negative control outcomes were partially balanced.

Conclusions This study found no evidence of an increased risk of CeAD after chiropractor-administered cervical SMT compared with ibuprofen prescription in adults seeking care for new episodes of neck pain or headache. Despite the rarity of these events, all clinicians, including chiropractors, should maintain vigilance for CeAD symptoms. Additional multidisciplinary research is warranted to further address potential confounding and examine patient subgroups (e.g., migraine) and stroke.

Keywords Chiropractic, Spinal manipulation, Adverse outcome pathways, Safety, Vertebral artery dissection

*Correspondence:
Robert J. Trager
Robert.Trager@UHhospitals.org

Full list of author information is available at the end of the article

BMC

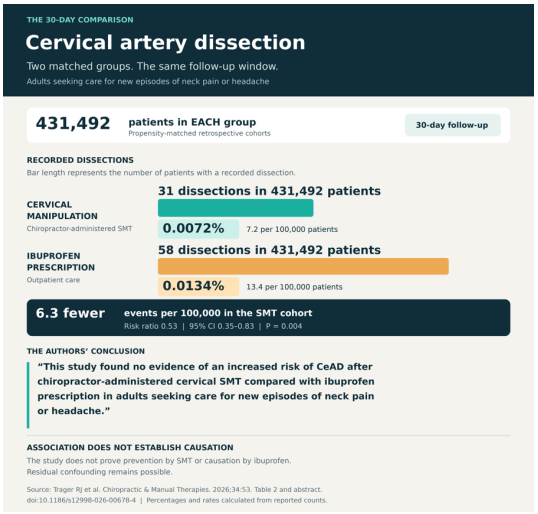

THE 30-DAY COMPARISON

Cervical artery dissection

Two matched groups. The same follow-up window.

Adults seeking care for new episodes of neck pain or headache

431,492 patients in EACH group
Propensity-matched retrospective cohorts

30-day follow-up

RECORDED DISSECTIONS
Bar length represents the number of patients with a recorded dissection.

CERVICAL MANIPULATION
Chiropractor-administered SMT
31 dissections in 431,492 patients
0.0072%
7.2 per 100,000 patients

IBUPROFEN PRESCRIPTION
Outpatient care
58 dissections in 431,492 patients
0.0134%
13.4 per 100,000 patients

6.3 fewer events per 100,000 in the SMT cohort
Risk ratio 0.53 | 95% CI 0.35–0.83 | P = 0.004

THE AUTHORS' CONCLUSION

"This study found no evidence of an increased risk of CeAD after chiropractor-administered cervical SMT compared with ibuprofen prescription in adults seeking care for new episodes of neck pain or headache."

ASSOCIATION DOES NOT ESTABLISH CAUSATION

The study does not prove prevention by SMT or causation by ibuprofen.
Residual confounding remains possible.

Source: Trager RJ et al. Chiropractic & Manual Therapies. 2026;34:53. Table 2 and abstract.
doi:10.1186/s12998-026-00678-4 | Percentages and rates calculated from reported counts.

Do DC's Have the Horses to DX CAD, Ischemia, Infarct?



Purpose?



19

Duty and Diligence



20

Bottom Line?



- **Scott Haldeman, DC, MD, PhD**
  - Questioner [00:00]:
    "Dr. Haldeman, what would you advise national associations to advise their members about informed consent and how to go about that?"
  - **Haldeman [00:11]:**
    "I think we all have to do informed consent, but **I wouldn't even put stroke on the informed consent because I don't think it's a complication of it.** You're not at higher risk to get a stroke."

    "But at the same time, I would add a sentence saying, 'Strokes have been known to occur in patients who have a sudden onset of **severe neck pain plus neurological symptoms**. If you find this, let me know immediately.'"

21

Purpose



22

Consequences of Fear?



Lambert et al. Chiropractic & Manual Therapies (2026) 34:46
https://doi.org/10.1186/s12998-026-00675-7

Chiropractic & Manual Therapies

RESEARCH Open Access

Educational approaches to the relationship between cervical adjusting and risk of cervical artery dissection; a survey of chiropractic faculty

Chad Lambert[1*], Kathryn Ross[1], Christine Major[1,2], Kara Burnham[1], Shawn Hatch[1] and Brian Anderson[2]

Abstract

Background Cervical artery dissection (CeAD) remains a rare but clinically important condition that has generated longstanding debate regarding its potential association with cervical spinal manipulative therapy (cSMT). Although biomechanical and epidemiologic studies have examined this relationship, little is known about how chiropractic educational programs address CeAD or how individual faculty member's perceptions shape instructional practices. This study surveyed chiropractic faculty members who actively teach cervical manipulation to understand how educators conceptualize CeAD risk and incorporate safety considerations into curricula.

Methods An anonymous twelve-item electronic survey was distributed via Qualtrics to institutional gatekeepers from 28 English-speaking chiropractic programs between February and March 2025. Gatekeepers then distributed the survey to instructors with hands-on experience teaching cervical manipulation within the prior five years. Survey items assessed teaching setting, beliefs about the cSMT–CeAD relationship, and whether perceived risk influenced screening procedures and technique modification. Quantitative data were analyzed using descriptive statistics, Pearson's chi-square tests, and Fisher's exact test; qualitative free-text responses underwent keyword extraction and keyword-based thematic analysis.

Results Individual faculty members from 17 of the 28 invited chiropractic programs participated (61% program response rate), yielding 103 responses with 85 meeting inclusion criteria (46 classroom, 38 clinical, 1 undisclosed). Teaching setting was significantly associated with faculty perspectives of CeAD causation ($p = 0.013$); classroom faculty more frequently characterized the cSMT – CeAD relationship as associational (73% vs. 27%), while clinical faculty more frequently endorsed a causal relationship mediated by modifiable risk factors (63% vs. 33%). Most respondents (72%) reported that CeAD risk influenced their instructional approach, primarily through pretreatment screening and technique modification. Qualitative analysis of free-text responses (n = 19) identified four themes: Clinical Assessment & Management (89.5% of responses), Risk & Safety (52.6%), Education & Training (31.6%), and Evidence Base (21.1%).

*Correspondence:
Chad Lambert
chlambert@uwstout.edu

Full list of author information is available at the end of the article

BMC

© The Author(s) 2026 **Open Access** This article is licensed under a Creative Commons Attribution 4.0 International License, which permits use, sharing, adaptation, distribution and reproduction in any medium or format, as long as you give appropriate credit to the original author(s) and the source, provide a link to the Creative Commons licence, and indicate if changes were made. The images or other third party material in this article are included in the article's Creative Commons licence, unless indicated otherwise in a credit line to the material. If material is not included in the article's Creative Commons licence and your intended use is not permitted by statutory regulation or exceeds the permitted use, you will need to obtain permission directly from the copyright holder. To view a copy of this licence, visit http://creativecommons.org/licenses/by/4.0/. The Creative Commons Public Domain Dedication waiver (http://creativecommons.org/publicdomain/zero/1.0/) applies to the data made available in this article, unless otherwise stated in a credit line to the data.

23

Syllabus

- Vertebral artery strain
- Risk factors
- Diagnosis
- FQs
- Neurologic deficits
- Defense to protect patients, doctors and our profession
- Bad Science
- CeAD Algorithm
- Standard of Care
- IC and Documentation

24

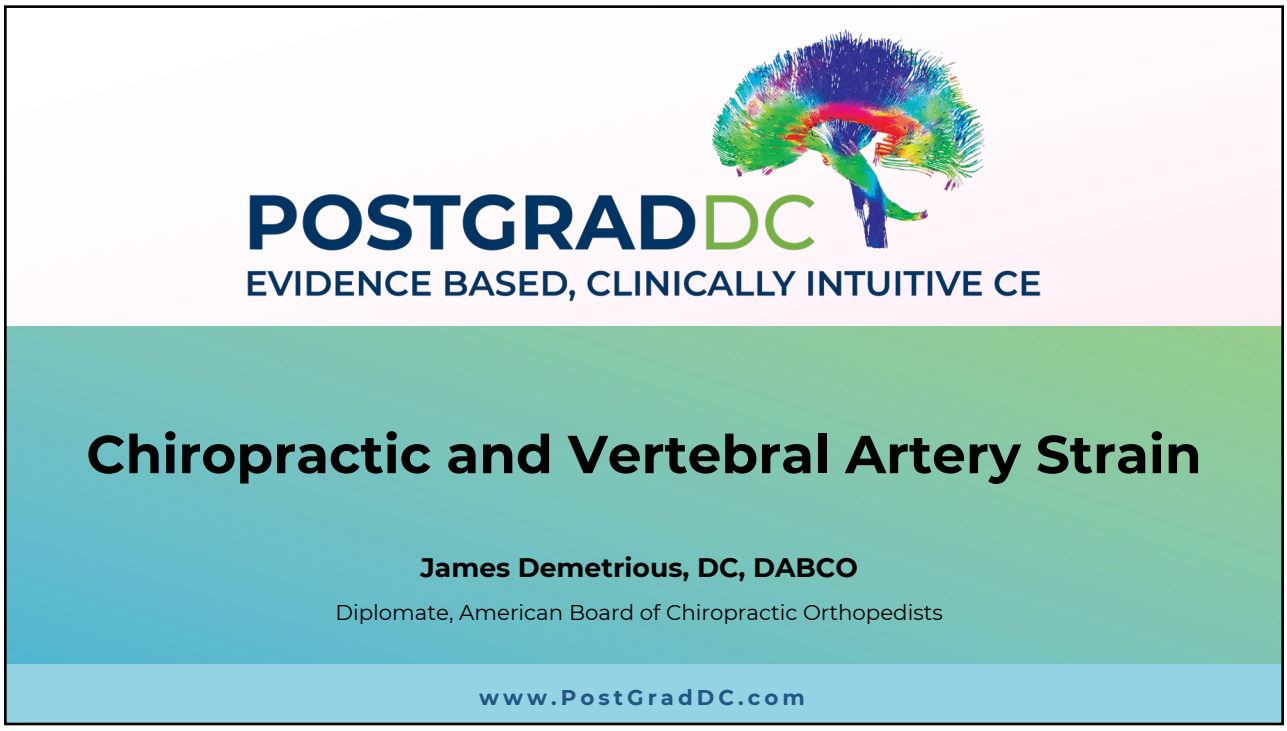
POSTGRADDC
EVIDENCE BASED, CLINICALLY INTUITIVE CE
Chiropractic and Vertebral Artery Strain
James Demetrious, DC, DABCO
Diplomate, American Board of Chiropractic Orthopedists
www.PostGradDC.com

25

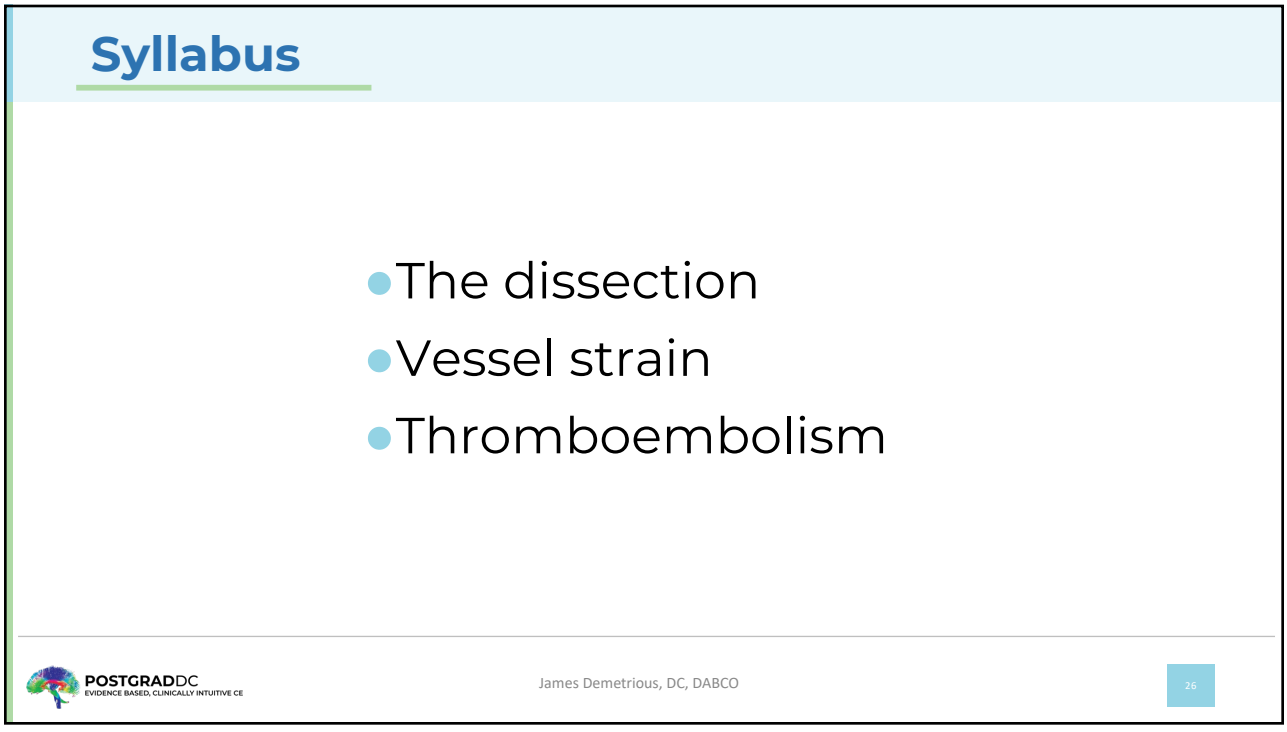
Syllabus
The dissection
Vessel strain
Thromboembolism
POSTGRADDC
EVIDENCE BASED, CLINICALLY INTUITIVE CE
James Demetrious, DC, DABCO
26

26

The Dissection



Cureus

Open Access Case Report

Recognition of Vertebral Artery Dissection in a High-Risk Postpartum Patient by a Chiropractic Physician

James Demetrious, Robert J. Trager, Stephen Weigh, Peter Tuchin, David Gruber

Abstract

We report a case of vertebral artery dissection (VAD) in a patient with postpartum preeclampsia and underscore the contribution of chiropractic assessment to recognizing vascular pathology, facilitating timely diagnosis, and reducing the risk of stroke. A 32-year-old G3P3 female with a history of mixed connective tissue disease presented to the emergency department five days postpartum with facial and peripheral edema, recent onset of hypertension, acute severe neck pain, headache, lightheadedness, confusion, and gait instability. Magnetic resonance angiography (MRA) and magnetic resonance venography of the head were performed. Small, unruptured bilateral internal carotid artery aneurysms were visualized. The patient was admitted and treated for postpartum preeclampsia. Upon discharge, she followed up with a neurovascular specialist. Although the patient improved with preeclampsia management, concerning neurologic symptoms persisted. The patient later consulted a chiropractor, who suspected VAD. Emergent neck MRA was recommended and performed, confirming VAD 12 days after the initial emergency department visit. The patient underwent conservative management with full resolution of symptoms and no evidence of ischemic stroke. This case underscores the importance of maintaining a high index of suspicion for VAD in postpartum patients presenting with new-onset neurological symptoms, particularly in the context of hypertensive disorders of pregnancy and underlying connective tissue disease. It further illustrates the potential role of chiropractic evaluation in the early clinical recognition of vascular pathology, which may facilitate timely diagnosis and intervention, and reduce the risk of stroke.

Introduction

Vertebral artery dissection (VAD) is a type of cervical artery dissection (CeAD) involving a tear in the wall of the vertebral artery, resulting in hematoma formation. It may cause ischemic stroke, particularly in young adults, and has an incidence rate of approximately two per 100,000 person-years [1]. The clinical presentation of VAD may include occipital headache, neck pain, and other potential features such as visual disturbances, dizziness, and gait abnormalities [2] that can be indicative of brain ischemia. Risk factors for VAD are increasingly understood, such as hypertension, migraine, and connective tissue disorders [3–5].

There is often a delay in the diagnosis of CeAD, with one study reporting a mean time to diagnosis for VAD of 9.0 days (standard deviation of 15.5 days) [6]. CeAD may also be misdiagnosed in the emergency department, with rates of misdiagnosis estimated from 1.2% to 5.4% [7]. Potential reasons for misdiagnoses or delays of VAD include the potentially nonspecific and variable clinical presentation, a low index of suspicion in young patients, cognitive error (e.g., anchoring, premature closure), and diagnostic overshadowing by more common conditions (e.g., migraine, musculoskeletal neck pain, or tension headache) [4,6,7].

Pregnancy is an increasingly recognized risk factor for CeAD and VAD. One study reported that pregnant women had approximately two times the risk of VAD compared to non-pregnant controls, with an elevated incidence of VAD during a one-year observation window (incidence rate ratio = 1.9 [95% confidence intervals (CI): 1.7–6.1] per 100,000 person-years [7]. Similarly, a case-control study identified a two-fold increase in CeAD risk associated with pregnancy [8]. In that study, the risk of CeAD was greatest during the postpartum period, with an incidence rate ratio of 5.2 (95% CI: 2.6–11.7) [9]. Despite this increased risk, CeAD and VAD may be particularly underrecognized in postpartum women, given the nonspecific symptoms such as headache and neck pain [10].

Patients often present to chiropractic physicians for evaluation of head and neck pain. Accordingly, these clinicians may be positioned to identify red flags suggestive of vascular pathology [11]. In this case report,

How to cite this article
Demetrious J, Trager R J, Weigh S, et al. (August 18, 2025) Recognition of Vertebral Artery Dissection in a High-Risk Postpartum Patient by a Chiropractic Physician. Cureus 17(8): e901389. DOI 10.7759/cureus.901389



FIGURE 1: Post-contrast high-resolution coronal magnetic resonance angiography sequence.

This shows a long hyperintense signal abnormality located in the V2 segment of the left vertebral artery, contributing to varying degrees of significant luminal narrowing consistent with vertebral artery dissection (white arrows).

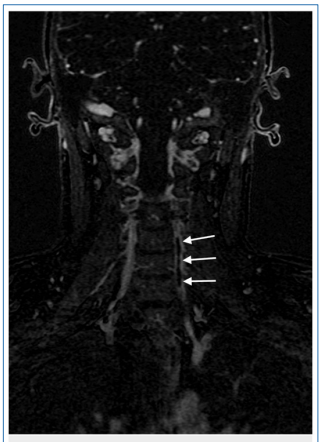

FIGURE 2: Post-contrast high-resolution coronal magnetic resonance angiographic imaging sequence.

This shows an intra-arterial filling defect located in the V2 segment of the left vertebral artery, consistent with VAD (white arrows).

27

The Dissection



FIGURE 3: Axial T1-weighted fat-saturated non-contrast magnetization-prepared rapid gradient echo (MPRAGE) image.

This shows a hyperintense crescent sign in the V2 segment of the left vertebral artery (white arrow), indicating an acute intramural hematoma within the arterial wall. There is approximately 70–80% stenosis of the arterial lumen present.

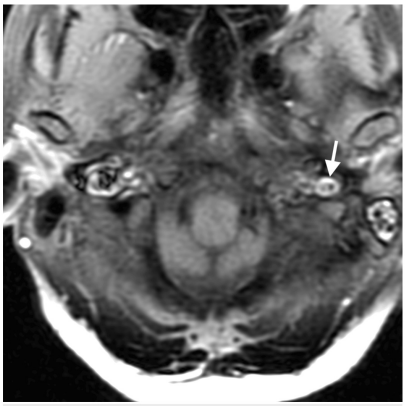

FIGURE 4: Axial T1-weighted fat-saturated non-contrast magnetization-prepared rapid gradient echo (MPRAGE) image.

This shows a hyperintense crescent sign surrounding the V3 segment of the left vertebral artery with central true and false lumens (white arrow), indicating an acute intramural vertebral artery dissection based on differential arterial flow dynamics.

28

Susceptibility and Compounded Factors/Clues in My Case

- Age: 25-45
- Pregnancy
- Post-partum
- Past history of migraines
- Past history of Lupus or Connective tissue disorder
- MTHFR polymorphism
- ?...

+

- Severe atraumatic head and neck pain
- Distribution of pain
- **Neurologic signs/symptoms:**
  - Transient ischemia
  - Unrelated to anchored DX
- ?...

→ VAD

29

Susceptibility and Compounded Factors/Clues



genes

MDPI

Review

MTHFR Gene Polymorphisms: A Single Gene with Wide-Ranging Clinical Implications—A Review

Antoni F. Arasekiewicz [1,*], Krzysztof Jałczak [1,*], Paweł Wójcik [1], Bartłomiej Białecki [1], Szymon Kubiak [1], Michał Szczechowski [1] and Danuta Januszkiewicz-Lewandowska [2,*]

[1] Faculty of Medicine, Poznan University of Medical Sciences, ul. Fredry 10, 61-701 Poznan, Poland; 91670@student.ump.edu.pl (A.F.A.); 91266@student.ump.edu.pl (K.J.); 91470@student.ump.edu.pl (P.W.); 91175@student.ump.edu.pl (B.B.); 91298@student.ump.edu.pl (S.K.); 91458@student.ump.edu.pl (M.S.)
[2] Clinic of Oncology, Hematology and Pediatric Transplantology, Poznan University of Medical Sciences, ul. Fredry 10, 61-701 Poznan, Poland
* Correspondence: danuta.januszkiewicz@ump.edu.pl
† These authors contributed equally to this work.

Abstract: The enzyme 5,10-methylenetetrahydrofolate reductase (MTHFR) catalyzes the conversion of 5,10-methylenetetrahydrofolate to 5-methyltetrahydrofolate, a process essential for the methylation of homocysteine to methionine. Polymorphisms in the MTHFR gene can reduce enzyme activity, disrupting the folate cycle and leading to hyperhomocysteinemia. The two most common polymorphisms associated with this gene are 665C>T (rs1801133) and 1298A>C (rs1801131). **Background:** This review provides a comprehensive summary of the current knowledge regarding MTHFR polymorphisms, with a particular focus on their potential impact on disease susceptibility. We hope this review will serve as a valuable resource for understanding the significance of MTHFR polymorphisms and their complex relationships with various diseases. **Methods:** For this review, we prioritized recent evidence, focusing on reviews and meta-analyses published between 2015 and 2025, sourced from PubMed and Google Scholar. **Results:** We explore the connection between these polymorphisms and a broad spectrum of medical conditions, including cardiovascular diseases and oxidative stress pathology; neurological and psychiatric disorders, such as Autism Spectrum Disorder, Alzheimer's disease, Schizophrenia, and Major Depressive Disorder; fertility, pregnancy, and neonatal complications, including recurrent pregnancy loss, pre-eclampsia, preterm birth, low birth weight, and neural tube defects; metabolic disorders, such as diabetes mellitus, inflammatory bowel disease, and non-alcoholic fatty liver disease; and oncological conditions, including breast, prostate, and ovarian cancers; as well as leukemia, and autoimmune diseases, particularly rheumatoid arthritis. **Conclusions:** While some diseases have a well-established association with MTHFR polymorphisms, others require further investigation. Our analysis highlights the crucial role of environmental factors, such as ethnic background and dietary folate intake, in influencing study outcomes.

Keywords: MTHFR; mutations; polymorphisms; homocysteine; folate; atherosclerosis; cancerogenesis; Alzheimer's disease; diabetes; NTDs

1. Introduction

Methylenetetrahydrofolate reductase (MTHFR) is an enzyme responsible for converting 5,10-methylenetetrahydrofolate (5,10-methylene-THF) to 5-methyltetrahydrofolate (5-methyl-THF). MTHFR is a flavoprotein that facilitates NADPH-dependent reduction, utilizing FAD as a cofactor [1]. This conversion is a critical step in the folate cycle [Figure 1],

Genes 2025, 16, 441 https://doi.org/10.3390/genes16040441

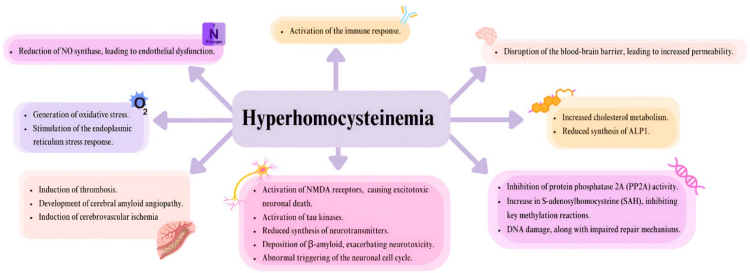

30

Susceptibility and Compounded Factors/Clues



genes

MDPI

Review

MTHFR Gene Polymorphisms: A Single Gene with Wide-Ranging Clinical Implications—A Review

Antoni F. Araszkiewicz [1,*], Krzysztof Jańczak [1,*], Paweł Wójcik [1], Bartłomiej Białecki [1], Szymon Kubiak [1], Michał Szczechowski [1] and Danuta Januszkiewicz-Lewandowska [1,*]

1 Faculty of Medicine, Poznan University of Medical Sciences, ul. Fredry 10, 61-701 Poznan, Poland; 91670@student.ump.edu.pl (A.F.A.); 91268@student.ump.edu.pl (K.J.); 91670@student.ump.edu.pl (P.W.); 91270@student.ump.edu.pl (B.B.); 91299@student.ump.edu.pl (S.K.); 91058@student.ump.edu.pl (M.S.)
2 Clinic of Oncology, Hematology and Pediatric Transplantology, Poznan University of Medical Sciences, ul. Fredry 10, 61-701 Poznan, Poland
* Correspondence: danuta.januszkiewicz@ump.edu.pl
† These authors contributed equally to this work.

Abstract: The enzyme 5,10-methylenetetrahydrofolate reductase (MTHFR) catalyzes the conversion of 5,10-methylenetetrahydrofolate to 5-methyltetrahydrofolate, a process essential for the methylation of homocysteine to methionine. Polymorphisms in the MTHFR gene can reduce enzyme activity, disrupting the folate cycle and leading to hyperhomocysteinemia. The two most common polymorphisms associated with this gene are 667C>T (rs1801133) and 1298A>C (rs1801131). **Background:** This review provides a comprehensive summary of the current knowledge regarding MTHFR polymorphisms, with a particular focus on their potential impact on disease susceptibility. We hope this review will serve as a valuable resource for understanding the significance of MTHFR polymorphisms and their complex relationships with various diseases. **Methods:** For this review, we prioritized recent evidence, focusing on reviews and meta-analyses published between 2015 and 2025, sourced from PubMed and Google Scholar. **Results:** We explore the connection between these polymorphisms and a broad spectrum of medical conditions, including cardiovascular diseases and oxidative stress pathology; neurological and psychiatric disorders, such as Autism Spectrum Disorder, Alzheimer's disease, Schizophrenia, and Major Depressive Disorder; fertility, pregnancy, and neonatal complications, including recurrent pregnancy loss, pre-eclampsia, preterm birth, low birth weight, and neural tube defects; metabolic disorders, such as diabetes mellitus, inflammatory bowel disease, and non-alcoholic fatty liver disease; and oncological conditions, including breast, prostate, and ovarian cancers, as well as leukemia, and autoimmune diseases, particularly rheumatoid arthritis. **Conclusions:** While some diseases have a well-established association with MTHFR polymorphisms, others require further investigation. Our analysis highlights the crucial role of environmental factors, such as ethnic background and dietary folate intake, in influencing study outcomes.

Keywords: MTHFR; mutations; polymorphisms; homocysteine; folate; atherosclerosis; cancerogenesis; Alzheimer's disease; diabetes; NTDs

1. Introduction

Methylenetetrahydrofolate reductase (MTHFR) is an enzyme responsible for converting 5,10-methylenetetrahydrofolate (5,10-methylene-THF) to 5-methyltetrahydrofolate (5-methyl-THF). MTHFR is a flavoprotein that facilitates NADPH-dependent reduction, utilizing FAD as a cofactor [1]. This conversion is a critical step in the folate cycle [Figure 1].

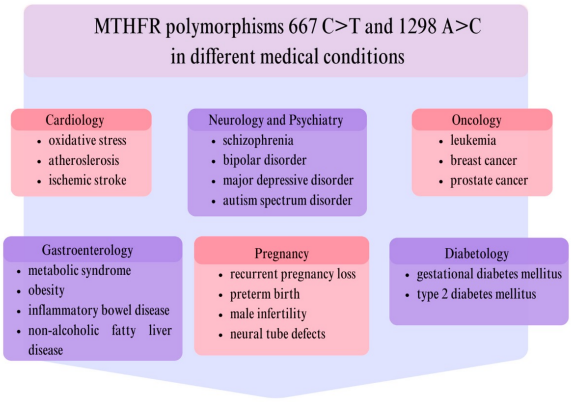

31

The Dissection

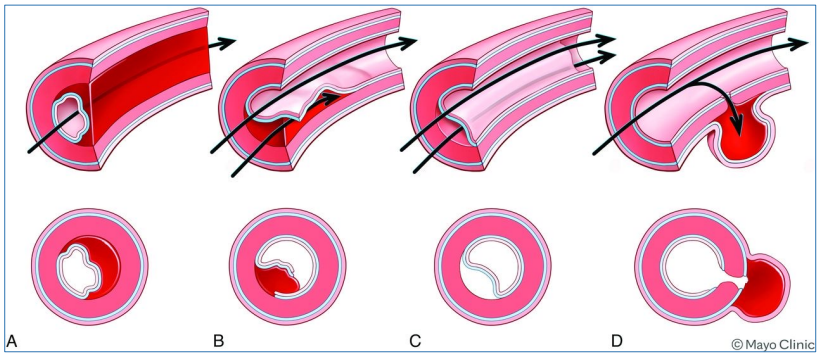

An Updated Review on Cervical Artery Dissections: Evolution of Imaging Findings, Medical and Endovascular Management, and New Imaging Frontiers

Benson et al. American Journal of Neuroradiology November 2025, DOI: https://doi.org/10.3174/ajnr.A8874

- Schematic of dissection types, based on both the involvement of specific arterial layers and associated findings. ***A***, Primary intramural hematoma without intimal tear. ***B***, Intramural hematoma secondary to an intimal tear with associated luminal stenosis. ***C***, Intimal tear with a dual lumen, but no intramural hematoma. ***D***, Dissection into the deeper aspects of the arterial wall, causing a pseudoaneurysm.

32

The Dissection



frontiers Frontiers in Neurology

TYPE Review
PUBLISHED 19 April 2024
DOI 10.3389/fneur.2024.1364218

Check for updates

OPEN ACCESS

EDITED BY
Anna Bersano,
IRCCS Carlo Besta Neurological Institute Foundation, Italy

REVIEWED BY
Jeremy Southmayd,
University of Virginia Health System, United States
Peggy Renier,
Assistance Publique Hopitaux De Paris, France

*CORRESPONDENCE
Lukas Mayer-Suess
lukas.mayer@i-med.ac.at

RECEIVED 01 January 2024
ACCEPTED 02 April 2024
PUBLISHED 19 April 2024

CITATION
Dejaikum B, Kiechl S, Knoflach M and Mayer-Suess L (2024) A narrative review on cervical artery dissection-related cranial nerve palsies.
Front. Neurol. 15:1364218.
doi: 10.3389/fneur.2024.1364218

COPYRIGHT
© 2024 Dejaikum, Kiechl, Knoflach and Mayer-Suess. This is an open-access article distributed under the terms of the Creative Commons Attribution License (CC BY). The use, distribution or reproduction in other forums is permitted, provided the original author(s) and the copyright owner(s) are credited and that the original publication in this journal is cited, in accordance with accepted academic practice. No use, distribution or reproduction is permitted which does not comply with these terms.

A narrative review on cervical artery dissection-related cranial nerve palsies

Benjamin Dejaikum[1], Stefan Kiechl[1,2], Michael Knoflach[1,2] and Lukas Mayer-Suess[1]*

[1]Department of Neurology, Medical University of Innsbruck, Innsbruck, Austria, [2]VASCage – Research Centre on Clinical Stroke Research, Innsbruck, Austria

Introduction: This study aimed to emphasize the importance of cranial nerve (CN) palsies in spontaneous cervical artery dissection (sCeAD).

Methods: A search term-based literature review was conducted on "cervical artery dissection" and "cranial nerve palsy." English and German articles published until October 2023 were considered.

Results: Cranial nerve (CN) palsy in sCeAD is evident in approximately 10% of cases. In the literature, isolated palsies of CN II, III, VII, IX, X, and XII have been reported, while CN IV palsy only occurs in combination with other lower cranial nerve palsies. Dissection type and mural hematoma localization are specific to affected CN as CN palsies of II or III are solely evident in those with stenotic-occlusive vessel pathologies located at more proximal segments of ICA, while those with CN palsies of IX, X, XI, and XII occur in expansive sCeAD at more distal segments. This dichotomization emphasizes the hypothesis of a different pathomechanism in CN palsy associated with sCeAD, one being hypoperfusion or microembolism (CN II, III, and VI) and the other being a local mass effect on surrounding tissue (CN IX, X, XI, and XII). Clinically, the distinction between peripheral palsies and those caused by brainstem infarction is difficult. This differentiation is key, as, according to the reviewed cases, peripheral cranial nerve palsies in sCeAD patients mostly resolve completely over time, while those due to brainstem stroke do not, making cerebrovascular imaging appraisal essential.

Discussion: It is important to consider dissections as a potential cause of peripheral CN palsies and to be aware of the appropriate diagnostic pathways. This awareness can help clinicians make an early diagnosis, offering the opportunity for primary stroke prevention.

KEYWORDS
cranial nerve palsy, vertebral artery dissection, internal carotid artery dissection, cervical artery dissection, intramural hematoma

Introduction

Cervical artery dissection (CeAD) is defined by the evidence of a mural hematoma within the arterial wall of either the carotid or vertebral arteries and can occur spontaneously (sCeAD) or in timely association with trauma. In the general stroke population, a sCeAD is rare and attributes for 1–2% of all strokes. In young individuals (i.e., under the age of 50 years of age) however, sCeAD accounts for 10–25% of ischemic strokes, making it one of the primary causes in this age group (1–3). The clinical presentation of sCeAD varies considerably with local signs

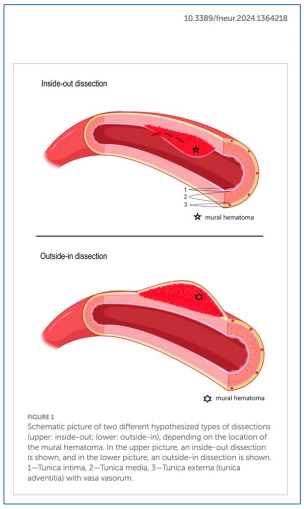

10.3389/fneur.2024.1364218

FIGURE 1
Schematic picture of two different hypothesized types of dissections (upper: inside-out; lower: outside-in), depending on the location of the mural hematoma. In the upper picture, an inside-out dissection is shown, and in the lower picture, an outside-in dissection is shown. 1—Tunica intima, 2—Tunica media, 3—Tunica externa (tunica adventitia) with vasa vasorum.

33

The Dissection



www.surgicalneurologyint.com
Surgical Neurology International
Editor-in-Chief: Nancy E. Epstein, MD, Professor of Clinical Neurosurgery, School of Medicine, Stony Brook, NY, USA
SNI: Neurovascular
Editor
Kazuhiro Hongo, MD
Shinshu University, Matsumoto, Japan
SNI Open Access

Review Article

Vasa vasorum: The role in intracranial physiology and pathophysiology

Kosei Yamamoto, Katsuhiro Mizutani, Takenori Akiyama, Hirotsugu Nogawa, Masahiro Toda

Department of Neurosurgery, Keio University, School of Medicine, Shinjuku, Japan.

E-mail: Kosei Yamamoto - y.kosei0109@gmail.com; *Katsuhiro Mizutani - m.corazon@keio.jp; Takenori Akiyama - akiyamanori@keio.jp; Hirotsugu Nogawa - hirotsugu0823@gmail.com; Masahiro Toda - todam@keio.jp

*Corresponding author:
Katsuhiro Mizutani,
Department of Neurosurgery,
Keio University, School of Medicine, Shinjuku, Japan.
m.corazon@keio.jp

Received: 23 March 2024
Accepted: 04 May 2024
Published: 07 June 2024

DOI
10.25259/SNI_214_2024

Quick Response Code:

ABSTRACT

Background: Vasa vasorum (VVs) is a Latin word representing vessels of vessels. VVs are usually found on the adventitia of the parent vessel and infrequently reach the media and intima, depending on the size and type of the parent vessels and physiological and pathological conditions. The VVs include arteries, capillaries, venules, and, rarely, lymphatics, forming the exquisite microvascular network in the vessel wall in normal or healthy state. Accumulated studies have revealed that VVs are involved in various intracranial diseases, including atherosclerotic diseases, aneurysms, and shunt diseases. The current review aims to review and integrate past and recent findings and knowledge on VVs and to facilitate our understanding of VVs and intracranial pathology involving VVs.

Methods: A literature review was carried out with a focus on the role of VVs by searching the Pubmed database.

Results: We identified 71 articles that discuss the role of VVs. We discussed the anatomical structure, physiological significance, and pathological significance of the VV.

Conclusion: VV is not only involved in the nutrition and metabolism of the vascular wall but is also deeply involved in the pathogenesis of inflammation, ischemia, and thrombosis of the vascular wall. In addition, in the central nervous system, intracranial vascular wall nutrient particularities and VVs are closely related to the pathogenesis of cerebral aneurysms, subarachnoid hemorrhage, arteriovenous shunt disease, atherosclerotic lesions, and other conditions.

Keywords: Cerebral aneurysms, Intracranial vessels, Vasa vasorum

INTRODUCTION (HISTORY OF VASA VASORUM [VV])

VVs are a Latin word representing vessels of vessels. It is also called vasa nutria[97] due to its role in the nutritional supply of the vessel wall. Thomas Willis first described its existence (1621–1675).[89] He was an English anatomist famous for the intracranial arterial rings that bear his name. The term "Vasa vasorum" was first coined by the German anatomist Christian Gottlieb Ludwig (1709–1773).[34] Since microscopes were unavailable in their time, their observation was conducted with the naked eye. They found tiny vessels on the wall and named them "vasa vasorum." Later, Gimbert[22] first reported the detailed anatomy and function of VVs. He observed VVs in detail in autopsy cases using microscopes, which developed rapidly in the 19th century. He noted that VVs are distributed in the tunica adventitia of blood vessels,

This is an open-access article distributed under the terms of the Creative Commons Attribution-Non Commercial-Share Alike 4.0 License, which allows others to remix, transform, and build upon the work non-commercially, as long as the author is credited and the new creations are licensed under the identical terms.
©2024 Published by Scientific Scholar on behalf of Surgical Neurology International

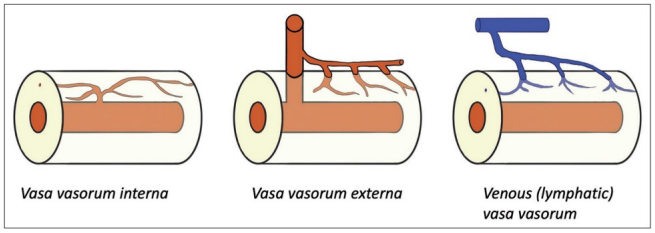

Figure 2: Types of vasa vasorum.

34

The Dissection



www.surgicalneurologyint.com

Surgical Neurology International

Editor-in-Chief: Nancy E. Epstein, MD, Professor of Clinical Neurosurgery, School of Medicine, State U. of NY at Stony Brook.

SNI: Neurovascular

Editor: Kazuhiro Hongo, MD, Shinshu University, Matsumoto, Japan

SNI Open Access

Review Article

Vasa vasorum: The role in intracranial physiology and pathophysiology

Kosei Yamamoto, Katsuhiro Mizutani, Takenori Akiyama, Hirotsugu Nogawa, Masahiro Toda

Department of Neurosurgery, Keio University, School of Medicine, Shinjuku, Japan.

E-mail: Kosei Yamamoto – yksosei0504@gmail.com; *Katsuhiro Mizutani – m.corairne@keio.jp; Takenori Akiyama – akiyamanor@keio.jp; Hirotsugu Nogawa – hirotsugu0823@gmail.com; Masahiro Toda – todam@keio.jp

*Corresponding author: Katsuhiro Mizutani, Department of Neurosurgery, Keio University, School of Medicine, Shinjuku, Japan.

m.corairne@keio.jp

Received: 23 March 2024
Accepted: 04 May 2024
Published: 07 June 2024

DOI
10.25259/SNI_214_2024

Quick Response Code:

ABSTRACT

Background: Vasa vasorum (VV(s)) is a Latin word representing vessels of vessels. VVs are usually found on the adventitia of the parent vessel and infrequently reach the media and intima, depending on the size and type of the parent vessels and physiological and pathological conditions. The VVs include arteries, capillaries, veins, and lymphatic vessels, involving the oxygenation and nourishment of the vessel's wall to sustain its healthy state. Accumulated studies have revealed that VVs are involved in various intracranial lesions, including atherosclerotic diseases, aneurysms, and shunt diseases. The current review aims to review and integrate past and recent findings and knowledge on VVs and to facilitate our understanding of VVs and intracranial pathology involving VVs.

Methods: A literature review was carried out with a focus on the role of VVs by searching the Pubmed database.

Results: We identified 71 articles that discuss the role of VVs. We discussed the anatomical structure, physiological significance, and pathological significance of the VV.

Conclusion: VV is not only involved in the nutrition and metabolism of the vascular wall but is also deeply involved in the pathogenesis of inflammation, ischemia, and thrombosis of the vascular wall. In addition, in the central nervous system, intracranial vascular wall nutrient particularities and VVs are closely related to the pathogenesis of cerebral aneurysms, subarachnoid hemorrhage, arteriovenous shunt disease, atherosclerotic lesions, and other conditions.

Keywords: Cerebral aneurysms, Intracranial vessels, Vasa vasorum

INTRODUCTION (HISTORY OF VASA VASORUM [VV])

VVs are a Latin word representing vessels of vessels. It is also called vasa nutria[67] due to its role in the nutritional supply of the vessel wall. Thomas Willis first described its existence (1621–1675).[66] He was an English anatomist famous for the intracranial arterial rings that bear his name. The term "Vasa vasorum" was first coined by the German anatomist Christian Gottlieb Ludwig (1709–1773).[31] Since microscopes were unavailable in their time, their observation was conducted with the naked eye. They found tiny vessels on the wall and named them "vasa vasorum." Later, Gimbert[23] first reported the detailed anatomy and function of VVs. He observed VVs in detail in autopsy cases using microscopes, which developed rapidly in the 19th century. He noted that VVs are distributed in the tunica adventitia of blood vessels,

This is an open-access article distributed under the terms of the Creative Commons Attribution-Non Commercial-Share Alike 4.0 License, which allows others to remix, transform, and build upon the work non-commercially, as long as the author is credited and the new creations are licensed under the identical terms.
©2024 Published by Scientific Scholar on behalf of Surgical Neurology International

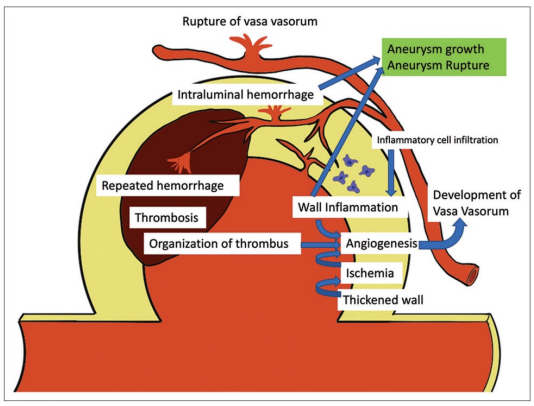

Figure 4: Vasa vasorum (VV) and cerebral aneurysms. The development of the VV is associated with unstable aneurysms.

35

The Dissection

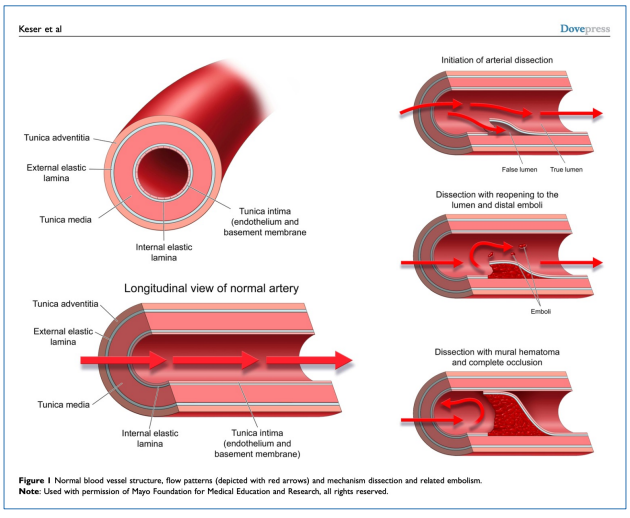

Figure 1 Normal blood vessel structure, flow patterns (depicted with red arrows) and mechanism dissection and related embolism.
Note: Used with permission of Mayo Foundation for Medical Education and Research, all rights reserved.

36

The Dissection

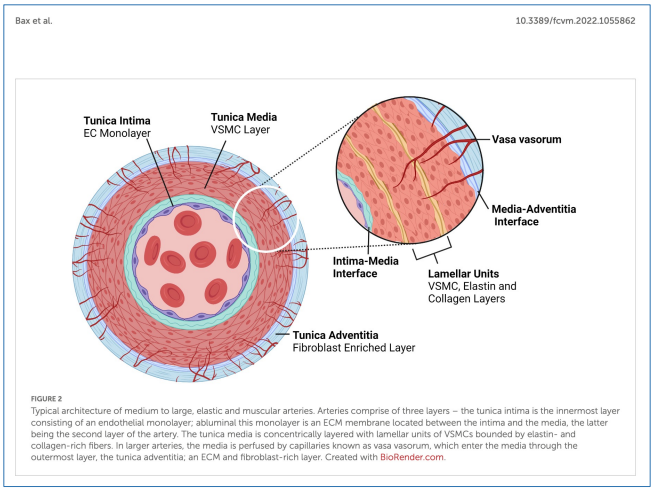

37

The Dissection

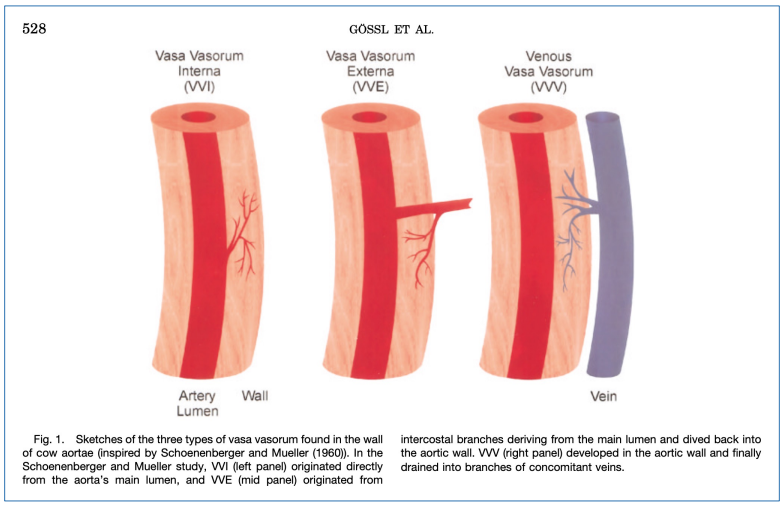

38

The Dissection

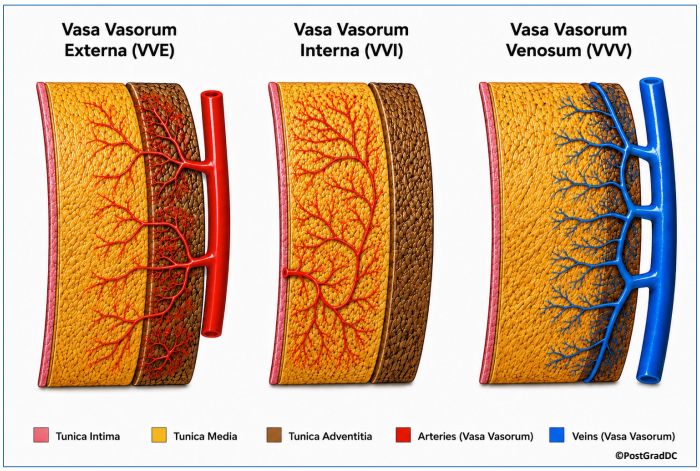

39

The Dissection

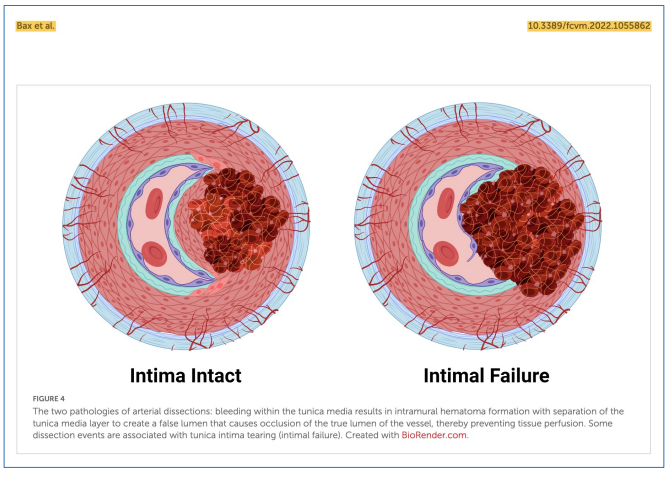



40

The Dissection

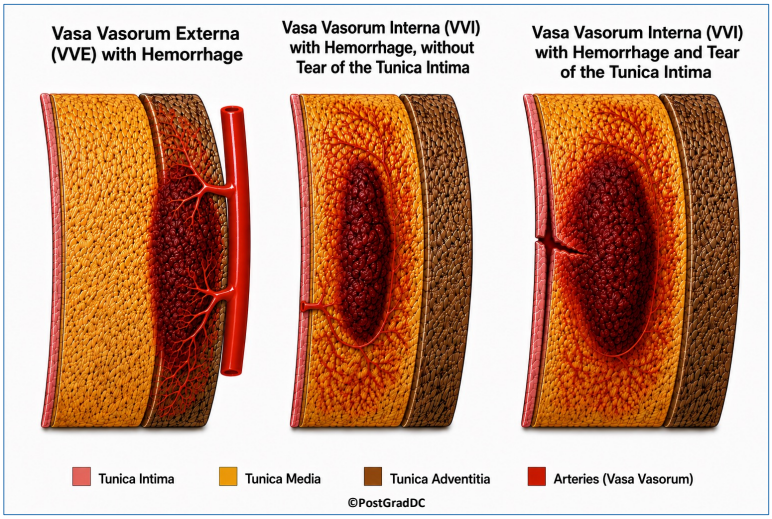

41

The Dissection



Case Report

Clinically Unidentified Dissection of Vertebral Artery as a Cause of Cerebellar Infarction

Hirotaro Iwase, MD; Masahiko Kobayashi, MD; Atsushi Kurata, MD; Shinya Inoue, MD

Background and Purpose—Dissection of vertebral arteries has been reported in association with minor neck movements without signs of trauma on the surface of the neck. In addition, injury of a vertebral artery can cause brain infarctions. However, few cases have been reported in which fatal brain infarction was due to nonocclusive, clinically undetected, traumatic thrombus formation in a vertebral artery.

Case Description—A 62-year-old man was hit by a car, and a right cerebellar infarction was found the day after the accident. The cause of the infarction could not be detected by angiography. Although the patient recovered favorably after surgical removal of the right lateral hemisphere of the cerebellum, he died suddenly 2 weeks after the accident. An autopsy and a microscopic study revealed pulmonary thromboembolism and organizing traumatic lesions of the right vertebral artery without occlusion or noteworthy stenosis of the artery.

Conclusions—We concluded that the patient sustained traumatic lesions of the right vertebral artery during the traffic accident 2 weeks before death and that his cerebellar infarction was due to a thrombus resulting from these traumatic lesions. (Stroke. 2001;32:1423-1424.)

Key Words: cerebellar infarction ■ dissection ■ trauma ■ vertebral artery

Extracranial dissection of the vertebral arteries is increasingly being recognized as a cause of stroke. Dissection of the vertebral arteries frequently occurs in association with abnormal neck movements.[1–6] However, injuries to the extracranial vertebral arteries are commonly ignored or overlooked, because the relative inaccessibility of the arteries makes them difficult to examine at autopsy.

Potsch and Bohl[1] reported on some cases in which the autopsy findings revealed fatal dissection of the vertebral arteries. In such cases, the cause of sudden death was brain stem ischemia, which was caused by occlusion of the vertebral or basilar arteries from thromboembolism or dissection.[1] Given that brain infarction can be caused by thrombi from traumatic lesions in the vertebral arteries,[1–4,6–12] even small traumatic lesions in the vertebral arteries could cause brain infarction in the absence of occlusion of the vertebral or basilar arteries; subsequent death would occur from complications. The present study may be the first report in which postmortem microscopic examination has revealed clinically undetected, nonocclusive, traumatic lesions of a vertebral artery as a cause of cerebellar infarction.

Case Report

A 62-year-old man on a bicycle was hit by a car on his left side. Because he had sustained a fracture of the left clavicle, he was admitted to the hospital. On admission he was fully conscious, with no arrhythmia on ECG and no neurological symptoms. The white blood cell count was 18 730/μL, the red blood cell count was 499×10^4/μL, and the platelet count was 27.0×10^4/μL. Vertigo, nausea, and vomiting appeared 10 hours after the accident, indicating a cerebellar disorder. The patient lost consciousness approximately 21 hours after the accident. CT and MRI indicated infarctions of the right cerebellum in the area of the posterior inferior cerebellar artery (Figure 1) and of the right occipital lobe in the area of the posterior cerebral artery. Angiography of the right vertebral artery was unsuccessful because the contrast medium could not flow into it, perhaps because of severe brain herniation. An endotracheal intubation was performed, and for cerebral decompression, the right lateral hemisphere of the cerebellum was surgically removed without delay. After the surgery, extubation was performed after the patient was weaned from oxygen. The patient recovered favorably and was able to follow his doctors' instructions 6 days after the accident. However, 14 days after the accident, he suddenly collapsed without symptoms of chest pain or dyspnea and died before treatment could be initiated.

Postmortem and Pathological Findings

The patient was 165 cm tall and weighed 62 kg. A laceration that had been sutured and was in the process of healing was

Received October 4, 2000; final revision received February 1, 2001; accepted February 8, 2001.
From the Departments of Forensic Medicine (H.I., M.K.), Human Pathology (A.K.), and Vascular Surgery (S.I.), Graduate School of Medicine, University of Tokyo, Tokyo, Japan.
Drs Iwase and Kobayashi contributed equally to this study.
Correspondence to Dr Hirotaro Iwase, Department of Forensic Medicine, University of Tokyo, 7-3-1 Hongo, Bunkyo-ku, Tokyo 113-0033, Japan. E-mail iwase@m.u-tokyo.ac.jp
© 2001 American Heart Association, Inc.
Stroke is available at http://www.strokeaha.org

1422

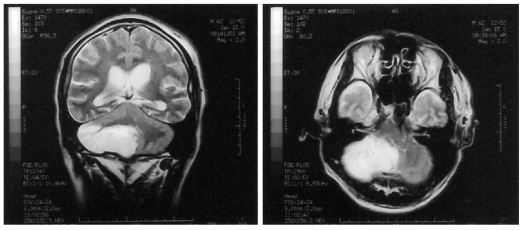

Iwase et al Cerebellar Infarction and Vertebral Artery Injury 1423

Figure 1. T2-weighted MRI of the cerebellum. Infarct is visible in the area of the right posterior inferior cerebellar artery.

42

The Dissection

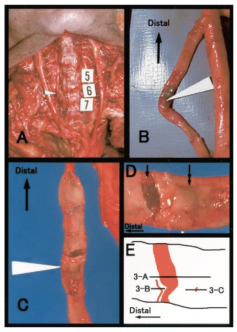

Figure 2. Intramural hemorrhage and tear in the intima of the right vertebral artery. A and B, In the right vertebral artery at the level of the sixth cervical vertebra, a red spot was observed (white arrowheads). The fifth through seventh vertebrae are numbered. C, The right vertebral artery was opened. There was an intramural hemorrhage (white arrowhead). No obstruction or noteworthy stenosis of the artery was observed. D, Magnification revealed a tear of the intima (single black arrow) in the distal margin of the subendothelial hemorrhagic spot (double black arrow). E, Schematic diagram of the traumatic lesions of the artery is shown. Red regions indicate tears of the intima. In addition to the grossly apparent intimal injury were several small tears of the intima.

43

The Dissection

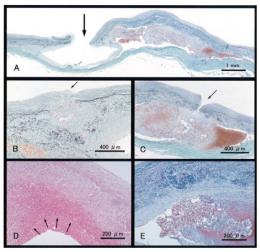

Figure 3. Photomicrographs of traumatic lesions in right vertebral artery. A, Photomicrograph of section 3A depicted in Figure 2E. There was a tear of the intima (arrow). The inner portion of the media was covered by collagen fibers and endothelial cells. The dissection in the tunica media appeared to extend proximally from the injury. Elastica Masson-Goldner stain was used. B, Photomicrograph of section 3B depicted in Figure 2E. There was a microscopic tear of the intima (arrow), to which an organizing thrombus had adhered. Granulation tissues containing collagen fibers and capillary growth were seen. Elastica Masson-Goldner stain was used. C, Photomicrograph of section 3C depicted in Figure 2E, showing another microscopic intimal tear (arrow). Elastica Masson-Goldner stain was used. D, Proliferating endothelial cells (arrows) surrounding the false lumen of the dissection. Hematoxylin and eosin stain was used. E, Granulation tissue in a clot that had adhered to the revealed media at the margin of the grossly visible tear of the intima. Elastica Masson-Goldner stain was used.

44

The Dissection

Table 4

History of trauma associated with VAD

	# Studies	Total sample size (N)	Number of subjects with symptom	Pooled proportion (pooled SE)	Range of proportions
Major trauma (primarily MVA)	6 [1, 8, 27, 31, 53, 69]	103	15	0.15 (0.22)	10-25%
Minor trauma*	16 [1, 6, 9, 16, 21, 28, 30-32, 35, 43, 57, 62, 65, 66, 69]	371	150	0.40 (0.47)	15-70%
Sporting injuries	13 [1, 6, 8, 16, 25, 30-32, 35, 57, 62, 65, 66]	261	40	0.15 (0.33)	3-42%
Chiropractic injury	14 [1, 8, 14, 21, 24, 30, 35, 42, 43, 53, 57, 65, 66, 69]	283	46	0.16 (0.36)	7-30%

* Some manuscripts included sports-related injuries or chiropractic manipulation as "minor trauma," so this category likely includes some VAD patients with these exposures.

Neurologist. 2012 September ; 18(5): 245–254.

45

A NARRATIVE REVIEW

Vertebral Artery Strain During Neck Activities, Including Cervical Spinal Manipulation, and Its Relationship to Cervical Artery Dissection

Pre-Publication Approved

Tuchin P · Demetrious J · Symons B · Conway P

Literature searched to October 2026



46

Why Vertebral Artery Strain Matters

- Cervical artery dissection (CeAD) is uncommon, but it is an important cause of stroke in younger and middle-aged adults
- Proposed mechanism: combined cervical rotation and extension over-elongate the VA, especially the V3 segment between C1 and C2
- Mechanically intuitive, but it requires that clinical strains approach damaging levels and differ materially from everyday neck movement

HOW STRAIN IS DEFINED

$$\Delta L \div L_0 \times 100\%$$

Change in artery segment length relative to its reference length, expressed as a percentage

POSTGRADDC
EVIDENCE BASED, CLINICALLY INTUITIVE CE

47

47

What this Review Set Out to Do

1. Summarize quantitative VA strain evidence during passive range of motion, sustained end-range positions and cSMT
2. Summarize hemodynamic evidence
3. Examine what strain data can and cannot imply about dissection
4. Review the epidemiologic, presentation, susceptibility and screening literature
5. Describe interpretive errors common in clinical, regulatory and medicolegal settings

POSTGRADDC
EVIDENCE BASED, CLINICALLY INTUITIVE CE

48

48

Anatomy: The V3 Loop and the Role of Slack

V1

Origin from the subclavian artery to the transverse foramen

V2

Ascends within the transverse foramina (commonly C6 to C1)

V3

Exits at C1 and loops around the atlanto-occipital joint to dural entry; mobile and variably tethered

V4

Intradural; joins its partner to form the basilar artery

Elongation is not tensile loading

Geometric redundancy ("slack") in the vessel path can be taken up during motion without substantial tensile force.

Why in situ measurement matters

Local strain reflects vessel geometry, friction at bony margins and relative vertebral motion, so direct measures beat free-tube models.

POSTGRADDC
EVIDENCE BASED, CLINICALLY INTUITIVE CE

49

49

Cadaveric Strain Studies: Strengths and Limits

Strengths

- Ultrasonic crystals or piezoelectric sensors attached to the arterial wall give continuous segmental length
- High sampling frequency during passive ROM and clinician-delivered manipulation
- Realistic hand contacts and thrust force–time profiles

Limitations

- Tissue tone and hydration differ from living subjects
- No active muscular stabilization
- No luminal blood flow or pressure
- Reference configuration varies across studies, from neutral posture to arbitrary in situ position

POSTGRADDC
EVIDENCE BASED, CLINICALLY INTUITIVE CE

50

50

cSMT Strain is Smaller than Passive Motion

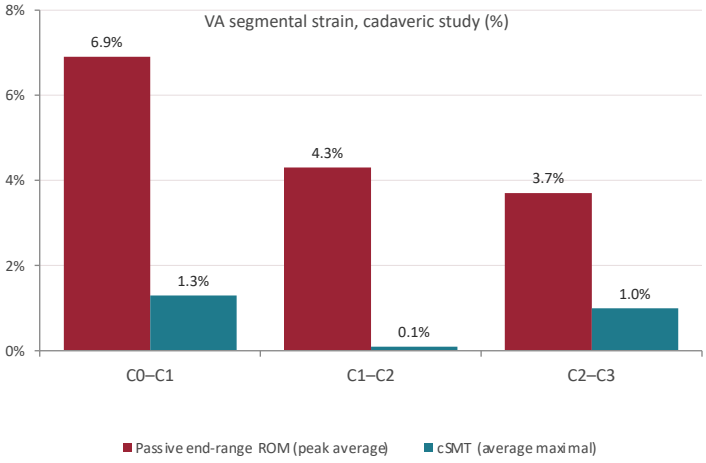

Fagundes & Herzog 2024 (ref 6). Pre-manipulative and thrust-phase maxima: 0.5% and 1.1%.

5.3× greater strain in passive ROM than during cSMT at C0–C1

7.2× greater strain in passive ROM than during cSMT at C1–C2

3.7× greater strain in passive ROM than during cSMT at C2–C3

POSTGRADDC
EVIDENCE BASED, CLINICALLY INTUITIVE CE

51

51

Converging Evidence Points the Same Way

META-ANALYSIS, V3 SEGMENT

3.8%

peak strain during cSMT, versus up to 12.5% during passive ROM

SLACK IN CADAVERIC ARTERIES

33.5%

average elongation before the first measurable tensile force; 51.3% to mechanical failure

ANIMAL TISSUE, IN VITRO

6%

strain for 1000 cycles produced no histologic damage versus sham; 30% strain damaged the wall

In one seven-specimen study, the greatest average length change during manipulation was 5.1% (range 1.1–15.1%), still within the slack available.

POSTGRADDC
EVIDENCE BASED, CLINICALLY INTUITIVE CE

52

52

Hemodynamics: Flow is Not Wall Injury

Sustained end-range rotation

- Can reduce contralateral VA flow in some individuals, but the evidence is heterogeneous and limited
- No significant change in several healthy or asymptomatic cohorts

Cervical manipulation

- Crossover RCT with MRI: no meaningful change in VA flow or velocity, and no change in posterior cerebral or cerebellar perfusion
- V3 Doppler in 25 healthy adults: no significant change after manipulation

Dissection is a structural failure of the wall. It can occur without a flow change, and flow can fall without any structural injury.

POSTGRADDC
EVIDENCE BASED, CLINICALLY INTUITIVE CE

53

53

What Strain Data Can and Cannot Tell Us

The data support

- cSMT does not stretch the VA more than passive end-range movement
- Manipulation strains sit far below elongation to failure
- Elongation stayed within available slack

They cannot establish

- Clinical safety, or that causation is excluded in vulnerable arteries
- Behavior of a pressurized, perfused artery under muscle tone
- Effects of non-tensile loads: shear, torsion, local compression
- Strain in arteries with intrinsic pathology, or in high-energy events such as collisions

POSTGRADDC
EVIDENCE BASED, CLINICALLY INTUITIVE CE

54

54

Epidemiology: Association is Not Causation

2014

AHA/ASA scientific statement

Most population-controlled studies found an association with VAD stroke in younger patients. Biomechanical evidence was insufficient to establish causation, and reverse causation was possible.

2016

Systematic review and meta-analysis

Small association between chiropractic care and dissection, rated very low quality, with no convincing evidence of causation.

2026

Propensity-matched cohort

No increased 30-day CeAD risk after chiropractor-delivered cSMT versus an outpatient visit with an ibuprofen prescription. Residual confounding cannot be excluded.

The 2014 statement predates later evidence and should not be treated as the final epidemiologic assessment.

POSTGRADDC
EVIDENCE BASED, CLINICALLY INTUITIVE CE

55

55

Reverse Causation: Symptoms Come First

Dissection begins → **New head or neck pain** → **Patient seeks care** → **Visit to a chiropractor or medical clinician** → **Stroke follows; the link looks causal**

Care-seeking cuts both ways

Some claims analyses show medical visits precede diagnosis as often as, or more often than, cSMT visits.

Timing is informative, not conclusive

Stroke symptoms within minutes of a manipulation raise the possibility that dissection was already in progress.

Not every case fits

CeAD can be painless with few triggers.

POSTGRADDC
EVIDENCE BASED, CLINICALLY INTUITIVE CE

56

56

Recognition and Susceptibility

Recognizing possible CeAD

- Head or neck pain that is new or unusual for that person (pattern, quality, location, onset, severity) often precedes ischemic symptoms
- No single feature is sufficient, and some patients, especially older adults, have no pain
- Clarify how the pain differs from the usual pattern, and assess progression and neurologic symptoms

Some factors associated with dissection

Connective-tissue disorders	**Fibromuscular dysplasia**
Arterial tortuosity	**Migraine**
Genetic variation (e.g., MTHFR, PHACTR1)	**Pregnancy and postpartum**
Fluoroquinolone exposure	**Recent minor neck trauma**

Screening and decision-support tools aim to flag who needs work-up. None predicts post-manipulation dissection, and none can exclude it.

POSTGRADDC
EVIDENCE BASED, CLINICALLY INTUITIVE CE

57

57

Common Misreading of the Evidence

Pattern	What the evidence supports
Citing a range maximum (e.g., 15.1%) without the slack	Average changes stayed within slack
Equating elongation with tensile force or injury	Elongation, force and tissue damage are distinct
Reading a flow decrease as injury, or no change as safety	Flow data describe patency only
Treating timing or case reports as proof of causation	Association acknowledged; causation unresolved
Treating cadaveric or animal data as proof of safety, or as irrelevant	They inform plausibility, not individual risk
Treating new decision-support tools as established standards	Promising, but validation is incomplete

POSTGRADDC
EVIDENCE BASED, CLINICALLY INTUITIVE CE

58

58

Clinical Implications

Recognition
Consider a vascular cause when head or neck pain is new, unusual, severe, progressive or comes with neurologic symptoms; refer when indicated.

Positioning
Sustained end-range rotation can reduce contralateral VA flow in some people; the clinical significance is uncertain.

Technique selection
No technique, force, vector or positioning strategy has been shown to reduce CeAD risk, so strain gives no basis for choosing one.

Patient factors
Susceptibility factors do not establish causation or contraindicate treatment, but may justify extra history-taking or evaluation.

Screening
Structured approaches can help identify possible dissection; none can exclude it or predict post-manipulation events.

59

Limitations and Future Research

Limitations of current evidence

- Small cadaveric samples; uncertain generalizability
- Inconsistent baseline length and neutral posture
- Combined loading (tension, torsion, shear, compression) poorly characterized
- Little in vivo data on wall mechanics during procedures
- No data from arteries with intrinsic pathology
- Few research groups; independent replication needed

Where research should go

- Susceptibility compounding
- Standardize boundary conditions and use clinically realistic neutral postures
- Report absolute kinematics alongside segment-specific length change
- Test pressurized, perfused preparations
- Combine vessel-wall imaging with careful phenotyping of suspected CeAD
- Prospective registries of symptom onset, care-seeking and neck-activity exposure

60

Conclusion

1. Strain during HVLA cSMT is generally small, and in cadaveric models lower than during passive end-range movement
2. The association with CeAD is confounded by care-seeking for early symptoms, but causation cannot be excluded, especially in susceptible arteries
3. Clinical safety depends on early recognition of CeAD and attention to individual susceptibility

Claims of harm and claims of safety should each be limited to what the study design can support.

61

Vertebral Artery Strain – Cadaveric Studies



Clinical Biomechanics 130 (2025) 106685

Contents lists available at ScienceDirect

Clinical Biomechanics

journal homepage: www.elsevier.com/locate/clinbiomech

Review

STRAIN in vertebral artery during passive cervical range of motion and spinal manipulation therapy: A systematic review and meta-analysis

Caroline Fagundes [a,*], Felipe Coutinho Kullmann Duarte [b], Walter Herzog [c]

[a] Independent Researcher, Taquara, Rio Grande do Sul, Brazil
[b] Canadian Memorial Chiropractic College, Toronto, ON, Canada
[c] University of Calgary, Calgary, Alberta, Canada

ARTICLE INFO

Keywords:
Mechanical stress
Spinal manipulation
Stroke
Strain
Vertebral artery

ABSTRACT

Objective: To identify and synthesize studies examining the strain on the vertebral artery (VA) during cervical spinal manipulation therapy (cSMT). Additionally, we compared VA strains induced by cSMT with passive range of motion (ROM) across different cervical spine levels and VA segments.

Design: A systematic review and meta-analysis were conducted following PRISMA guidelines and registered with PROSPERO (CRD42024593437).

Literature search: The search was performed in May 2025 across SCOPUS, PubMed, MEDLINE, Web of Science, LILACS, SciELO, and the Index to Chiropractic Literature.

Study selection criteria: Studies that focused on VA strain during cSMT and passive ROM. Risk of bias was assessed using the Anatomical Quality Assessment (AQUA) Tool.

Data synthesis: Data extraction included descriptive, methodological, VA strain, and interventional details. Meta-analysis was performed for studies comparing VA strain between cSMT and ROM.

Results: 6 studies met the inclusion criteria, with four providing data for meta-analysis. cSMT consistently produced lower VA strain (up to 3.8 %) compared to passive ROM (up to 12.5 %) in the V3 segment (C0–C2). Meta-analysis revealed greater strain during ROM compared to cSMT, particularly during rotation (standardized mean difference [SMD] = -1.05).

Conclusion: This systematic review and meta-analysis provide consistent evidence that cSMT induces less strain on the VA, particularly within the V3 segment, compared to passive cervical ROM. Although the evidence comes from studies conducted in human cadaveric specimens, the robustness of the methodologies and the consistency of findings across studies contribute to the growing body of biomechanical evidence supporting the relative safety of cSMT with respect to VA strain.

1. Introduction

Neck pain constitutes a highly prevalent musculoskeletal condition, currently affecting over 200 million individuals worldwide, and ranks among the foremost contributors to global disability (GBD 2021 Neck Pain Collaborators, 2024; Kazeminasab et al., 2022; Safiri et al., 2020). Its etiology is inherently multifactorial, arising from the complex interplay of biological, psychological, and environmental determinants. Beyond the immediate impact on individual well-being, neck pain imposes a significant societal and economic burden (Kazeminasab et al., 2022; Mazaheri-Tehrani et al., 2023; Meng et al., 2025). In light of this complexity, contemporary clinical guidelines advocate for multimodal, non-invasive management strategies, encompassing manual therapies, targeted exercise programs, ergonomic modifications, and patient education as core components of first-line care (Côté et al., 2016).

Within this paradigm, cervical spinal manipulative therapy (cSMT) has garnered increasing attention due to its demonstrated clinical efficacy in the management of both acute and chronic neck pain. Recent systematic reviews and meta-analyses have reported moderate to large therapeutic effect sizes, reinforcing the role of cSMT as a valuable adjunct within multidisciplinary pain management frameworks (Chaibi et al., 2023; Liu et al., 2023). However, despite its therapeutic benefits, cSMT has been associated with vertebral artery dissection (VAD), which may culminate in vertebrobasilar stroke (Whedon et al., 2015; Whedon

* Corresponding author at: 1745 Pedro José Muller Street, Taquara, Rio Grande do Sul 95612-120, Brazil.
E-mail address: carolfac@quarcolas.com.br (C. Fagundes).

https://doi.org/10.1016/j.clinbiomech.2025.106685
Received 24 July 2025; Accepted 20 October 2025
Available online 22 October 2025
0268-0033/© 2025 Published by Elsevier Ltd.

- These findings provide robust biomechanical evidence that cSMT, when performed under controlled conditions, induces markedly lower vertebral artery (VA) strain—particularly within the V3 segment—than physiological cervical movements such as contralateral rotation and combined extension-rotation.
- The methodological rigor of the included studies, notably the use of fresh, unembalmed human cadaveric specimens and high-precision, real-time strain measurement via piezoelectric ultrasonic crystals, lends considerable internal validity to these results.

62

Vertebral Artery Strain – Cadaveric Studies

Vertebral Artery Strain During Chiropractic SMT

Study	Model	Measured VA Strain During SMT	Reported/Estimated Failure Threshold	Key Interpretation
Symons et al. 2002	Cadaveric	~1–11% (segment-dependent)	~40–60% elongation	Strain far below injury threshold
Herzog et al. 2012	Cadaveric	~0–13%	~40–60%	No mechanical basis for arterial damage
Wuest et al. 2010	Cadaveric	~2–3%	~40–60%	Minimal strain during manipulation
Piper et al. 2014	Experimental	~15% to +18% (variable)	~40–60%	Even upper range below failure
Gorrell et al. 2022	Cadaveric (high precision)	Well below 20%	~30% (first force), ~50%+ failure	Manipulation does not reach tension threshold
Fagundes et al. 2024	Systematic review	Comparable to or less than ROM	~40–60%	SMT similar to normal motion
Fagundes et al. 2024	Observational	Majority strain in positioning phase	~40–60%	Thrust adds minimal additional strain

PostGradDC.com

63

The Dissection

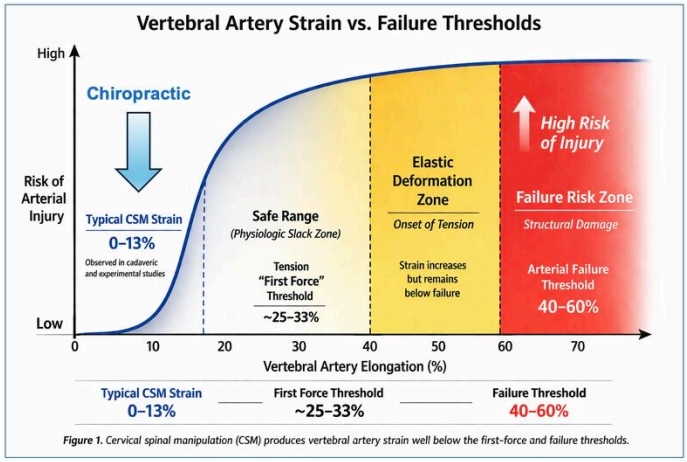

Figure 1. Cervical spinal manipulation (CSM) produces vertebral artery strain well below the first-force and failure thresholds.

PostGradDC.com

- **First Force Threshold:**
  - During cervical motion (including manipulation), the artery initially undergoes:
    - **Geometric straightening**
    - **Unfolding of slack**
- **No meaningful tensile stress is present during this phase**
- Only after this slack is removed does the artery begin to resist elongation—this is the **"first force" point**

64

Gorrell *et al. Chiropractic & Manual Therapies* (2022) 30:28
https://doi.org/10.1186/s12998-022-00438-0

Chiropractic & Manual Therapies

RESEARCH Open Access

Kinematics of the head and associated vertebral artery length changes during high-velocity, low-amplitude cervical spine manipulation

Lindsay M. Gorrell[1,2*], Gregor Kuntze[3], Janet L. Ronsky[1,4], Ryan Carter[5], Bruce Symons[5], John J. Triano[6] and Walter Herzog[1]

Conclusions: Mean head angular displacements and VA length changes were small during CSM thrusts. Of the four different CSM measured, mean VA length changes were largest during rotation procedures. This suggests that if clinicians wish to limit VA length changes during the thrust phase of CSM, consideration should be given to the type of CSM used.

65

Gorrell *et al. Chiropractic & Manual Therapies* (2022) 30:28
https://doi.org/10.1186/s12998-022-00438-0

Chiropractic & Manual Therapies

RESEARCH Open Access

Kinematics of the head and associated vertebral artery length changes during high-velocity, low-amplitude cervical spine manipulation

Lindsay M. Gorrell[1,2*], Gregor Kuntze[3], Janet L. Ronsky[1,4], Ryan Carter[5], Bruce Symons[5], John J. Triano[6] and Walter Herzog[1]

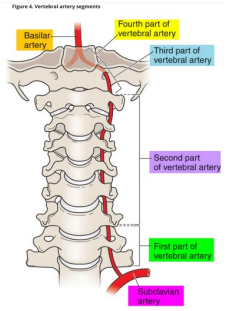

Table 2 Angular displacement (degrees) of the head relative to the sternum and VA length change (%) combining data from all donors and clinicians during ipsilateral CSM thrusts

		Rotation					Lateral flexion				
		X	Y	Z	Whole	V3	X	Y	Z	Whole	V3
C1	Mean	2.5	8.1	−11.5	1.1	3.7	−3.0	4.9	−4.4	0.9	2.6
	SD	2.6	2.8	3.8	0.9	4.4	1.7	4.3	7.8	1.5	4.3
	Minimum	0.2	5.9	−15.0	0.0	−0.3	−5.3	0.4	−20.0	−1.1	0.0
	Maximum	6.5	12.5	−5.8	2.3	10.0	−0.9	10.7	0.7	3.2	10.4
C2	Mean	2.1	10.0	−12.6	1.6	−0.1	−5.3	5.6	−6.4	1.1	2.3
	SD	4.4	3.5	4.5	1.3	5.3	4.2	3.2	8.9	0.8	3.6
	Minimum	−3.8	−5.0	−16.1	0.1	−9.3	−13.0	1.0	−19.3	0.2	−0.3
	Maximum	7.6	13.9	−3.7	3.2	7.1	−1.6	9.8	7.9	2.1	8.9
C3	Mean	−0.3	7.2	−11.0	1.9	4.5	−3.6	4.7	−4.1	0.7	1.7
	SD	2.1	2.3	2.6	0.7	5.4	2.2	3.2	3.0	0.5	2.6
	Minimum	−1.9	4.4	−13.7	0.8	0.0	−7.0	1.1	−8.9	0.2	0.0
	Maximum	2.8	10.1	−7.5	2.4	10.8	−1.4	9.4	−0.9	1.3	6.7
C4	Mean	1.5	8.9	−9.8	1.4	2.8	−3.9	6.3	−5.1	0.6	2.1
	SD	2.6	4.5	3.7	1.0	4.0	3.1	2.5	5.1	1.0	2.6
	Minimum	−2.8	2.5	−14.5	0.2	0.0	−9.1	2.2	−10.7	−0.6	0.0
	Maximum	5.0	13.2	−5.6	2.7	8.6	−1.7	9.1	2.0	2.1	5.6
C5	Mean	1.4	9.6	−10.7	1.8	2.5	−3.9	5.7	−2.1	1.2	2.5
	SD	4.7	2.7	3.1	1.2	3.1	3.0	3.8	4.2	1.0	2.6
	Minimum	−6.1	5.7	−15.5	−0.1	0.0	−7.6	1.3	−6.0	0.2	0.0
	Maximum	5.1	12.6	−7.4	3.1	6.6	−0.9	12.6	5.5	2.6	6.4
C6	Mean	1.3	8.9	−8.0	1.0	1.8	−4.2	4.6	−5.4	1.3	2.4
	SD	3.2	3.0	2.6	1.2	3.7	3.2	2.0	6.3	0.7	2.4
	Minimum	−3.9	5.0	−12.0	−0.4	−0.4	−9.4	1.5	−10.6	0.7	0.0
	Maximum	5.5	14.1	−4.6	3.1	11.6	−1.1	6.5	5.1	2.1	5.8
C7	Mean	−0.8	8.7	−9.5	1.3	2.0	−3.5	5.4	−3.3	1.2	2.0
	SD	4.3	2.6	3.0	1.1	2.8	3.5	2.6	4.1	1.0	3.6
	Minimum	−6.6	6.0	−15.3	0.3	−0.1	−8.8	2.3	−7.7	−0.3	−1.1
	Maximum	3.9	12.3	−7.0	3.3	6.8	0.8	7.9	2.5	2.3	7.1

Ipsilateral manipulations involve contralateral head rotation; positive kinematic values indicate flexion, left lateral flexion and left rotation; positive VA length changes indicate elongation of the vessel

X, coronal axis; Y, sagittal axis; Z, transverse axis; SD, standard deviation; whole, whole VA; V3, V3 segment of VA

66

Gorrell et al. Chiropractic & Manual Therapies (2022) 30:28
https://doi.org/10.1186/s12998-022-00438-0

Chiropractic & Manual Therapies

RESEARCH Open Access

Kinematics of the head and associated vertebral artery length changes during high-velocity, low-amplitude cervical spine manipulation

Lindsay M. Gorrell[1,2*], Gregor Kuntze[3], Janet L. Ronsky[1,4], Ryan Carter[5], Bruce Symons[5], John J. Triano[6] and Walter Herzog[1]

Table 3 Angular displacement (degrees) of the head relative to the sternum and VA length change (%) combining data from all donors and clinicians during contralateral CSM thrusts

		Rotation					Lateral flexion				
		X	Y	Z	Whole	V3	X	Y	Z	Whole	V3
C1	Mean	1.0	−8.8	9.7	0.9	1.8	−2.0	−5.9	0.1	0.8	1.8
	SD	3.4	2.0	3.3	0.8	1.4	1.6	3.0	4.1	1.2	1.8
	Minimum	−2.9	−11.8	6.2	0.2	0.0	−5.0	−10.1	−3.9	−1.3	0.0
	Maximum	5.2	−6.5	14.6	2.2	3.1	−0.5	−2.8	7.6	1.9	3.7
C2	Mean	0.9	−7.0	9.7	0.6	0.9	−2.3	−5.6	−0.3	1.6	2.0
	SD	2.8	3.0	3.2	0.4	1.0	3.3	5.7	2.2	1.2	2.6
	Minimum	−2.6	−10.3	5.4	0.2	0.0	−7.3	−11.5	−4.0	0.1	0.0
	Maximum	4.2	−2.6	13.6	1.1	2.2	1.8	4.4	2.3	3.6	6.0
C3	Mean	0.5	−9.1	8.3	1.4	2.2	−3.8	−7.4	1.6	1.4	1.1
	SD	4.5	5.7	2.7	0.7	2.7	2.9	4.2	4.3	2.0	1.9
	Minimum	−3.6	−19.3	3.9	0.2	0.0	−7.1	−15.1	−3.1	−1.4	−1.3
	Maximum	9.1	−3.7	11.0	2.3	5.8	−0.3	−4.3	8.8	4.2	4.2
C4	Mean	0.1	−8.2	7.4	1.0	1.3	−4.3	−6.0	1.8	1.8	0.7
	SD	2.0	3.9	2.5	0.7	1.8	4.5	2.3	6.8	1.7	2.1
	Minimum	−2.5	−14.5	5.1	−0.3	−0.7	−10.1	−10.1	−7.8	0.0	−1.3
	Maximum	3.5	−3.8	11.6	1.6	3.5	1.0	−3.6	12.9	4.4	3.9
C5	Mean	−1.3	−5.4	4.5	1.1	1.0	−3.7	−6.3	3.6	0.9	1.8
	SD	1.0	2.6	1.9	0.6	1.3	1.7	2.6	6.1	1.7	2.4
	Minimum	−3.2	−8.5	2.2	0.3	0.0	−6.6	−9.0	−2.8	−2.0	−0.2
	Maximum	−0.2	−1.9	7.0	1.8	3.3	−1.8	−3.2	11.9	2.5	5.8
C6	Mean	−0.7	−8.3	7.5	1.2	1.4	−4.6	−5.2	0.8	1.5	1.7
	SD	3.5	1.6	2.6	0.2	1.5	2.3	3.2	6.4	0.7	2.0
	Minimum	−7.7	−10.9	3.3	1.0	0.0	−6.1	−8.8	−4.9	0.6	0.0
	Maximum	1.7	−6.3	10.4	1.5	4.0	−1.2	−1.3	9.9	2.3	3.9
C7	Mean	−0.3	−8.4	6.1	0.9	1.3	−2.8	−5.7	0.7	0.7	0.5
	SD	2.7	2.4	3.1	0.5	2.4	3.1	1.5	5.8	0.7	1.1
	Minimum	−4.3	−12.3	2.7	0.2	−1.1	−6.7	−7.9	−6.5	0.0	−0.8
	Maximum	2.8	−6.3	10.4	1.6	4.4	1.4	−3.7	10.6	1.9	2.3

Contralateral manipulations involve ipsilateral head rotation; positive kinematic values indicate flexion, left lateral flexion and left rotation; positive VA length changes indicate elongation of the vessel

X, coronal axis; Y, sagittal axis; Z, transverse axis; SD, standard deviation; whole, whole VA; V3, V3 segment of VA

67

ELSEVIER

Journal of Electromyography and Kinesiology
Volume 22, Issue 5, October 2012, Pages 740-746



Vertebral artery strains during high-speed, low amplitude cervical spinal manipulation

W. Herzog, T.R. Leonard, B. Symons, C. Tang, S. Wuest

- VA strains obtained during SMT are significantly smaller than those obtained during diagnostic and range of motion testing, and are much smaller than failure strains.
- We conclude from this work that cervical SMT performed by trained clinicians does not appear to place undue strain on VA, and thus does not seem to be a factor in vertebro-basilar injuries.

68

Trauma?

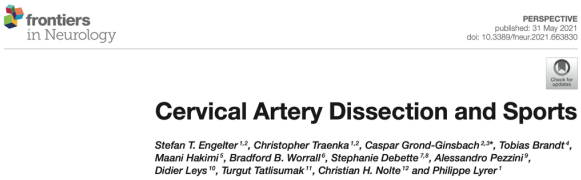

frontiers in Neurology

PERSPECTIVE
published: 31 May 2021
doi: 10.3389/fneur.2021.663830

Cervical Artery Dissection and Sports

Stefan T. Engelter[1,2], Christopher Traenka[1,2], Caspar Grond-Ginsbach[2,3], Tobias Brandt[4], Maani Hakimi[5], Bradford B. Worrall[6], Stephanie Debette[7,8], Alessandro Pezzini[9], Didier Leys[10], Turgut Tatlisumak[11], Christian H. Nolte[12] and Philippe Lyrer[1]*

- Approximately 40% of the CeAD patients reported any kind of recent head or neck trauma in the month prior to symptom onset (4), as compared to 10% of the patients with ischemic stroke attributable to a cause other than CeAD and 20% of the healthy controls (4).
- More than 90% of the trauma events recalled by the CeAD patients were trivial and so mild that the individuals did not seek for medical care or advice.
- As a causal relationship with the CeAD is either questionable or unclear, the term *mechanical trigger event* is preferred.

69

Randomized Controlled Trial > J Manipulative Physiol Ther. 2014 Jan;37(1):22-31.
doi: 10.1016/j.jmpt.2013.07.008. Epub 2013 Nov 15.

Changes in vertebral artery blood flow following various head positions and cervical spine manipulation

Jairus J Quesnele [1], John J Triano [2], Michael D Noseworthy [3], Greg D Wells [4]

- There were no significant changes in blood flow or velocity in the vertebral arteries of healthy young male adults after various head positions and cervical spine manipulations.

70

Open access Research

BMJ Open

Effect of cervical manipulation on vertebral artery and cerebral haemodynamics in patients with chronic neck pain: a crossover randomised controlled trial

Nicholas Moser,[1] Silvano Mior,[1,2] Michael Noseworthy,[3] Pierre Côté,[4] Greg Wells,[5] Michael Behr,[6] John Triano[1]

- Our work is the first to show that cervical manipulation does not result in brain perfusion changes compared with a neutral neck position or maximal neck rotation.
- The changes observed were found to not be clinically meaningful and suggests that cervical manipulation may not increase the risk of cerebrovascular events through a haemodynamic mechanism.

71

J Manipulative Physiol Ther. 2020 Feb;43(2):144-151. doi: 10.1016/j.jmpt.2019.09.001. Epub 2020 May 30.

Changes in Vertebral Artery Blood Flow in Different Head Positions and Post-Cervical Manipulative Therapy

Christopher Yelverton [1], Jessica Joy Wood [2], Diana Lopes Petersen [2], Cynthia Peterson [2]

- Hemodynamic measurements of the V3 region of the vertebral artery do not show significant changes in the measured head positions or following manipulation of the upper cervical spine in patients **without** pre-existing risk factors.

72

MAYO CLINIC

CONCISE REVIEW

Craniocervical Artery Dissections: A Concise Review for Clinicians

Zafer Keser, MD; James F. Meschia, MD; and Giuseppe Lanzino, MD

- Craniocervical artery dissection (CAD) is a sudden tear in the intimal layer with subsequent bleeding into the subintimal space.
- This causes progressive vessel wall incursion into the lumen and narrowing, which at times proceeds to occlusion.1
- The site of dissection becomes thrombogenic because of turbulent blood flow and exposure of thrombogenic factors (Figure 1A).
- Enlargement of the vessel wall can also lead to compression on surrounding structures like cranial nerves.2
- If the intramural hematoma grows into the adventitia, it can lead to pseudoaneurysm formation (Figure 1B).
- Rupture of a pseudoaneurysm can cause subarachnoid hemorrhage (SAH) if the site of dissection extends to the intracranial vasculature.

Mayo Clin Proc. ■ April 2022;97(4):777-783 ■ https://doi.org/10.1016/j.mayocp.2022.02.007
www.mayoclinicproceedings.org ■ © 2022 Mayo Foundation for Medical Education and Research

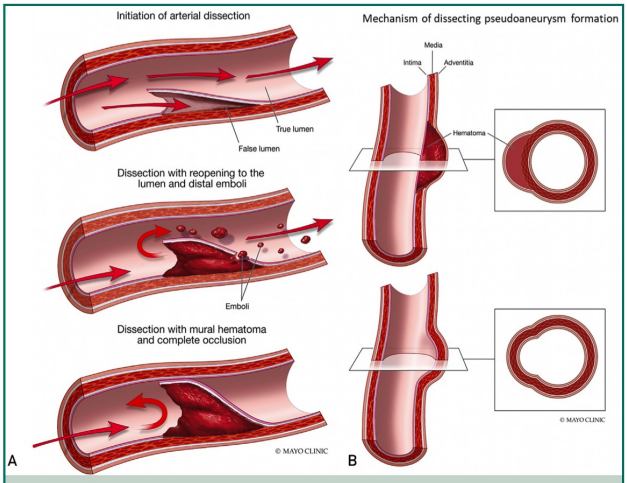

FIGURE 1. Mechanism and evolution of a dissection formation (A) and dissecting pseudoaneurysm (B). (Used with permission of Mayo Foundation for Medical Education and Research, all rights reserved.)

73

Symons et al. 2002

- Cadaveric segmental strain
- Strain: ~1–11%
- Includes rotational positioning
- Well below failure (40–60%)
- Conclusion: Insufficient force for dissection

Symons BP et al. JMPT. 2002;25:504–510.

74

Elliott et al. 2006

- Mechanical properties study
- Failure threshold ~40–60%
- Provides baseline comparison
- Conclusion: SMT far below failure

Elliott JM et al. Spine. 2006;31:E69–E74.

75

Wuest et al. 2010

- Whole artery strain
- Strain: ~2–3%
- Limited angular specificity
- Minimal elongation
- Conclusion: Negligible injury risk

Wuest S et al. JMPT. 2010;33:273–278.

76

Herzog et al. 2012

- Cadaveric SMT with coupled motion
- Strain: ~0–13%
- Includes angular mechanics
- Far below injury threshold
- Conclusion: No biomechanical causation

Herzog W et al. J Electromyogr Kinesiol. 2012;22:740–746.

77

Piper et al. 2014

- Motion analysis + strain modeling
- Strain up to ~18%
- Explicit angular motion tracking
- Below failure thresholds
- Conclusion: Rotation does not create injurious strain

Piper SL et al. Clin Biomech. 2014;29:1099–1105.

78

Gorrell et al. 2022

- High-precision cadaveric study
- Strain <20%
- First force ~25–33%
- Failure >40%
- Conclusion: SMT below tension threshold

Gorrell LM et al. Sci Rep. 2022;12:15438.

79

Fagundes et al. 2025

- Cervical manipulation causes less strain on the vertebral artery than passive motion.
- In the atlantoaxial region, manipulation causes less strain than passive motion.
- Passive cervical rotation and extension-rotation apply more strain than manipulation.

Fagundes et al. Clinical Biomechanics. 2025 106685.

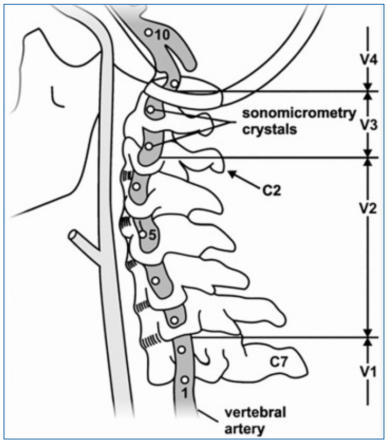

80

Integrated Conclusion

- Typical SMT strain: 0–13%
- First force: ~25–33%
- Failure: ~40–60%
- Angular motion does not significantly increase strain
- No biomechanical evidence supporting CAD causation
- Dissections more consistent with pre-existing pathology

81

Vertebral Artery Flow – In Vivo Studies

Study	Study type	In vivo?	Primary measure	Intervention/position	Main finding	Expert-testimony relevance	Research quality
Quesnele et al., 2014	Experimental in vivo MRI study	Yes	VA blood flow and velocity	Neutral, rotation, and cervical manipulation positions	No significant adverse hemodynamic compromise was identified with cervical positioning or manipulation.	Best in vivo imaging surrogate evidence; evaluates flow, not direct wall strain.	**Moderate–high**: in vivo MRI, controlled design, surrogate endpoint.
Moser et al., 2019	Crossover randomized controlled trial	Yes	VA and cerebral hemodynamics by MRI	Cervical manipulation and maximal rotation in chronic neck pain patients	No significant cerebral hemodynamic change after manipulation or maximal rotation.	High-value clinical population study; strongly relevant to physiologic safety arguments.	**High for hemodynamics; indirect for strain.**
Licht et al., 1998	In vivo ultrasound study	Yes	Peak VA flow velocity	Cervical rotation	Evaluated VA flow during rotation; useful early physiologic evidence.	Demonstrates that rotation can be tested physiologically, but ultrasound flow is not strain.	**Low–moderate**: older ultrasound methods, surrogate endpoint.
Licht et al., 1999	Experimental in vivo flow study	Yes	VA volume blood flow	Cervical manipulation and premanipulative testing	VA flow increased transiently after manipulation and returned to baseline; no significant adverse flow change during premanipulative testing.	Helpful rebuttal to claims that manipulation predictably reduces VA flow.	**Moderate**: in vivo flowmetry, small/older study.
Haynes, 2000	In vivo Doppler/duplex study	Yes	VA flow during rotation	Neck rotation	Compared Doppler velocimetry and duplex findings during cervical rotation.	Supports that rotation-related VA flow effects are variable and method-dependent.	**Low–moderate**: physiologic surrogate; older methodology.
Haynes & Milne, 2001	In vivo color duplex ultrasound	Yes	VA blood-flow velocity	Contralateral cervical rotation	Evaluated whether rotation altered VA blood-flow velocity.	Useful for discussing rotation as a potential flow modifier, not proof of injury mechanism.	**Low–moderate**: ultrasound surrogate endpoint.
Haynes, 2002	In vivo duplex investigation	Yes	Lumen narrowing mechanism	Atlanto-axial rotation	Examined whether narrowing was due to stretch or localized compression.	Relevant because it distinguishes mechanical compression from generalized tensile strain.	**Moderate**: mechanistic in vivo vascular imaging, still surrogate.
Bowler et al., 2011	In vivo ultrasound study	Yes	Internal carotid and VA blood flow	Simulated manipulation position	Simulated manipulation positioning did not adversely affect carotid or VA blood flow.	Directly relevant to premanipulative-position arguments.	**Moderate**: in vivo design, surrogate flow outcome.

82

Vessel Strain Unsupported…

- The **direct strain evidence** is biomechanical and largely cadaveric, with Herzog/Symons/Wuest studies showing that vertebral artery strain during cervical SMT is generally **less than or comparable to ordinary cervical range-of-motion loading**.
- The **in vivo human evidence** is primarily hemodynamic, not direct wall-strain measurement, and MRI/ultrasound studies generally do **not** demonstrate clinically meaningful vertebral artery or cerebral blood-flow compromise during cervical rotation, pre-manipulative positioning, or manipulation.
- The most defensible testimony is therefore: **direct in vivo vertebral artery strain measurement in humans is limited, but the combined biomechanical strain data and in vivo flow data do not support the assertion that cervical SMT predictably produces pathologic vertebral artery loading or flow compromise.**

83

Thromboembolic Inference: Integrated Conclusion

- **Association ≠ Causation**
- Strong confounding by indication (neck pain/headache)
- No high-quality evidence proving CSM causes thromboembolism
- Mechanism requires pre-existing dissection with thrombus
- Epidemiology does not support causal relationship

84

Thromboembolic Inference: Unconfirmed



Commentary
Commentaire

Sudden neck movement and cervical artery dissection

John W. Norris, Vadim Beletsky, Zurab G. Nadareishvili, on behalf of the Canadian Stroke Consortium

Two recent deaths from artery dissection following neck manipulation by chiropractors have focused media and medical attention on the relation between sudden neck movement and cervical artery dissection. Although the first case of carotid artery dissection due to chiropractic neck manipulation was described over 50 years ago,[1] the frequency of carotid and vertebral artery dissection as a cause of stroke has only been recognized in the last decade. Since then, there have been many publications and case reports on this topic. In a recent Canadian survey, dissection of the cervical arteries was one of the most common causes of stroke in patients less than 45 years of age.[2]

During the past year the Canadian Stroke Consortium, a national network of stroke physicians, has been prospectively collecting detailed information on cases of dissection of the cervical arteries. Seventy-four patients have been studied so far: their age range was 16–87 years (mean 44 years), 60% were male, and there was a predominance of vertebrobasilar artery dissections compared with carotid artery dissections (72% v. 28%). Most (81%) of the dissections were associated with sudden neck movement, ranging from therapeutic neck manipulation to a vigorous game of volleyball, but some occurred during mild exertion such as lifting a pet dog or during a bout of coughing.

The vertebral artery is extremely vulnerable to torsion injury because it winds around the atlas to enter the skull: any abrupt rotation may stretch the artery and tear the delicate intima. Thrombosis formed over this vascular injury may subsequently be dislodged and may embolize to the brain. This is probably the most frequent cause of stroke in these patients and produces a characteristic angiographic appearance sometimes with "false" aneurysms (Fig. 1).[3] Less frequently, the vessel may be occluded by a collar of hematoma forming in the vessel wall at the site of the dissection.

Angiographic evidence of injury to the vertebral artery is nearly always at the C1–2 level. The carotid artery, lying freely in the soft tissues of the neck, is more mobile and less vulnerable but is tethered adjacent to C2, so that dissections may occur 1–2 cm distal to the bifurcation (Fig. 2). This is in contrast to the site of atherosclerotic lesions, which are most frequently close to the origin of the internal carotid artery.

The resulting stroke follows the typical clinical pattern of its arterial territory: carotid artery dissections cause hemiparesis, hemisensory loss and other cerebral hemispheric features such as aphasia, whereas vertebrobasilar artery dissections may result in ataxia and quadriparesis. However, sudden and often severe neck or occipital pain is the hallmark of dissection (in 74% of our cases), and its on-

38 JAMC • 11 JUIL., 2000; 163 (1)

© 2000 Canadian Medical Association or Its licensors

Commentary
Commentaire

Cervical manipulation and risk of stroke

Moira K. Kapral, Susan J. Bondy

See related article page 905

An association between stroke and cervical manipulation has been reported with increasing frequency, and each new report seems to reignite debate between neurologists and chiropractors. Points of disagreement include the validity of the association, the magnitude of the potential risk and the practical implications with respect to patient care. Norris and colleagues[1] described a case series of patients with cervical artery dissection, with the provocative findings that the majority (81%) of patients reported some antecedent sudden neck movement, with neck manipulation being implicated in 28% of cases. (Other surveys by neurologists have estimated the risk of cervical artery dissection following neck manipulation to be of the order of 1 in 500 000 to 1 in 1 million manipulations.[2]) In this issue (page 905), Scott Haldeman and colleagues' review malpractice claims for stroke following chiropractic cervical manipulation and conclude that the risk of vertebral artery dissection following cervical manipulation is exceedingly low at approximately 1 in 1.85 million manipulations.

What is the true risk of cervical artery dissection and stroke following cervical manipulation? Unfortunately, the existing data do not permit a definitive answer to this question. The study by Norris and colleagues is laudable in its strict case definition and documentation of cases of arterial dissection. However, although it provides interesting information about potential mechanisms of injury, lack of blinding of the assessors may have led to bias in the assessment of exposure. In addition, case series such as this can never provide an estimate of risk of stroke or even establish a causal relationship between the exposure and the outcome because of the absence of a control group.

The study by Haldeman and colleagues provides important data about the association between stroke and specific chiropractic interventions. However, the use of malpractice claims data is unlikely to lead to an accurate estimation of the risk of stroke. Not all stroke events will lead to claims, and the same biases in documentation of exposure may be operating as in the Norris paper. In addition, this study relies on an estimate of the denominator of cervical manipulations performed by chiropractors.

A theoretically less biased estimate of the risk of stroke secondary to chiropractic manipulation comes from a population-based case–control study using administrative data from Ontario.[3] This placed the risk of stroke for individuals aged under 45 years at about 1.3 per 100 000 chiropractic visits, with a wide 95% confidence interval of 0.5–16.7 per 100 000. Interestingly, no significant association was found for patients aged over 45 years. Administrative data are also subject to error.

In clinical practice, what advice should clinicians give their patients? The answer must lie in conveying an honest estimate of risk, paired with an unbiased assessment of the potential benefit. However, both sides of this debate suffer from a lack of precise data.

The evidence to date indicates that the risk associated with chiropractic manipulation of the neck is both small and inaccurately estimated. The estimated level of risk is smaller than that associated with many commonly used diagnostic tests or prescription drugs. On the other hand, the expected benefit from the manoeuvre is also difficult to quantify. Systematic reviews of the literature and ratings of appropriateness by an expert panel[4] suggest that cervical manipulation or mobilization, or both, provide short-term pain relief and range-of-motion enhancement for the subgroup of individuals with subacute or chronic neck pain. The evidence to support the benefit of cervical manipulation for other indications, including acute neck pain, migraine and other miscellaneous conditions, is far less compelling.

In terms of providing evidence of efficacy, the onus may be placed fairly on practitioners and anyone advocating the expanded application of chiropractic care. This may be particularly true in the case of patients with no current symptoms (i.e., preventive therapy). There is an acute need for further research on the efficacy of chiropractic manipulation for indications to which it is now being widely applied, and for which it is frequently requested.

Responsible practitioners of chiropractic medicine are as motivated as any patient or professional group to obtain sound scientific data on the effectiveness and risks of chiropractic care. Chiropractic colleges and associated professional bodies have invested in the promotion and funding of high-quality research in this area.[5] Agencies that have taken measures to promote chiropractic care research include the Consortial Center for Chiropractic Research established by the US National Institutes of Health, the Research Committee of the Canadian Chiropractic Association (committee established in 1998) and the Canadian Memorial Chiropractic College. Quality research can be produced when it is supported financially. For example, we have seen more research on chiropractic care for low-back pain[6] than for neck pain because of the availability of re-

CMAJ • OCT. 2, 2001; 165 (7) 907

© 2001 Canadian Medical Association or Its licensors

Research
Recherche

Research letter

Arterial dissections following cervical manipulation: the chiropractic experience

Scott Haldeman, Paul Carey, Murray Townsend, Costa Papadopoulos

See related article page 907

Research into the effectiveness of spinal manipulation[1] has resulted in some acknowledgement of its use by independent agencies in Canada,[2] the United States,[3] the United Kingdom[4] and Denmark,[5] which has led to increased integration of chiropractors into mainstream health care delivery systems. This increased acceptance has led to greater interest in the potential complications of spinal manipulation and, in particular, the occurrence of arterial dissection following cervical manipulation.

Recent surveys have suggested that it is not uncommon for neurologists, particularly those with a specific interest in stroke, to treat patients who have developed a vertebral artery dissection following cervical manipulation.[6] In this study, we attempted to obtain an estimate of the rate of stroke following manipulation from a chiropractic perspective.

Following approval by the Institutional Review Board of the Canadian Memorial Chiropractic College in Toronto, Ont., a review of malpractice data from the Canadian Chiropractic Protective Association (CCPA) was carried out to evaluate all claims of stroke following chiropractic care for the 10-year period between 1988 and 1997. All case files were reviewed in order to determine the type of associated cerebrovascular event and the characteristics of the patients who experienced these complications. The diagnosis by the treating neurologist, which was obtained from the records, was used to determine the nature of the stroke. This was compared with the number of cervical manipulations performed each year by chiropractors covered by the CCPA. This denominator was obtained from a survey questionnaire that was completed for one week of practice by 10% of the practising chiropractors in Canada. The effective response rate was 77.8%. These data were extrapolated by multiplying the median number of visits in which a cervical manipulation was administered by the number of chiropractors in the survey group, and using a figure of 49.1 weeks of practice per year obtained from a previous survey. The results of the extrapolation suggested that approximately 134.5 million cervical manipulations were performed by chiropractors covered by the CCPA during this period.

There were 43 cases of neurological symptoms following cervical manipulation over the 10-year period. Of these, 20 were minor and were not diagnosed as stroke by a neurologist. Twenty-three cases of stroke or vertebral artery dissection following cervical manipulation were reported. The frequency of hypertension, diabetes, use of oral contraceptives, migraine headaches and smoking in these 23 patients is shown in Table 1.

There are over 4500 licensed chiropractors in Canada. The likelihood that a chiropractor will be made aware of an arterial dissection following cervical manipulation is approximately 1:8.06 million office visits, 1:5.85 million cervical manipulations, 1:1430 chiropractic practice years and 1:48 chiropractic practice careers. This is significantly less than the estimates of 1:500 000–1 million cervical manipulations calculated from surveys of neurologists.[7,8] These data also confirm the conclusions of a recent review of the literature in which patients at risk for this complication could not be identified.[9]

It is probable that the experience of chiropractors does not reflect all dissections that occur following cervical ma-

Table 1: Characteristics of patients who developed vertebral artery dissections following cervical manipulation (*n* = 23)

Characteristic	No. (and %) of patients*
Median age (and range), yr	42.5 (24–75)
Male:female	6 (26):17 (74)
Hypertension	4 (17.4)
Diabetes	0
Oral contraceptive use	1 (4.3)
Migraine	4 (17.4)
Smoking	5 (22)
Elevated cholesterol	0
Time of onset of symptoms following manipulation	
Within 20 min	15 (65)
1–24 h	5 (22)
1–9 d	3 (13)

*Unless stated otherwise.

CMAJ • OCT. 2, 2001; 165 (7) 905

© 2001 Canadian Medical Association or Its licensors

85

Thromboembolism?



86

Thromboembolism?

Study	Evidence	Relevance	Main Finding	Key Limitations	Interpretation
Rothwell et al., 2001	Population-based case-control	Examines stroke after chiropractic manipulation	Reported association, especially in younger patients.	Cannot distinguish causal injury from patients seeking care for early dissection symptoms.	Important historical association study, but weak for proving thromboembolic causation.
Smith et al., 2003	Case-control study	Often cited to support association between SMT and VAD	Reported SMT as an independent risk factor for VAD.	Retrospective design; recall/referral bias; temporality uncertain; prodromal symptoms may have prompted care.	Supports association, but does not prove that manipulation generated thrombus or embolization.
Cassidy et al., 2008	Population-based case-control and case-crossover	Evaluates VBA stroke after chiropractic and primary-care visits	No excess VBA stroke risk with chiropractic care compared with primary care; authors suggest patients with evolving dissection may seek care for headache/neck pain before stroke.	Claims-data design; exposure misclassification; cannot directly observe thrombus/dissection timing.	Strong support for confounding by indication, not proof that CSM causes thromboembolism.
Biller et al., 2014	Scientific statement/expert synthesis	Reviews CAD and cervical manipulative therapy	Recognizes association but notes causation is difficult to determine.	Consensus document; dependent on available low-to-moderate-quality evidence.	Best used to support caution and informed clinical reasoning, not definitive causation.
Kosloff et al., 2015	Large case-control study, commercial and Medicare populations	Evaluates VBA stroke risk after chiropractic exposure	No significant association between chiropractic care and VBA stroke; concluded manipulation is an unlikely cause.	Administrative coding limitations; cannot evaluate individual biomechanics or arterial pathology.	Higher-quality epidemiology arguing against a causal thromboembolic mechanism.
Church et al., 2016	Systematic review and meta-analysis	Assesses chiropractic care and cervical artery dissection	Found a small association, but evidence quality was very low and likely affected by bias/confounding.	Case reports and observational studies dominate; major confounding by neck pain/headache.	Association is insufficient to infer causation or a reliable thromboembolic mechanism.
Whedon et al., 2022	Medicare claims analysis	Evaluates cervical artery dissection after spinal manipulation in older adults	No increased CAD risk after cervical spinal manipulation compared with controls.	Medicare population only; claims-based diagnosis and exposure data.	Does not support CSM as an independent cause of CAD or thromboembolic stroke in older adults.

87

Thromboembolic Inference

- Literature evaluating the proposed relationship between cervical spinal manipulation (CSM) and thromboembolic stroke events.
- Focus: Epidemiology, association vs causation, and biologic plausibility.

88

Cassidy et al. 2008

- Population-based case-control + case-crossover
- No increased risk vs primary care
- Supports confounding by indication
- Interpretation: Early dissection symptoms drive care-seeking

Cassidy JD et al. Spine. 2008;33:S176–S183.

89

Kosloff et al. 2015

- Case-control (US commercial + Medicare Advantage)
- No significant association with VBA stroke
- Interpretation: CSM unlikely causal factor

Kosloff TM et al. Chiropr Man Therap. 2015;23:19.

90

Whedon et al. 2022

- Medicare claims analysis
- No increased CAD risk vs controls
- Interpretation: No evidence of causation

Whedon JM et al. BMC Geriatr. 2022;22:917.

91

Church et al. 2016

- Systematic review + meta-analysis
- Weak association, very low-quality evidence
- High bias + confounding

Church EW et al. Cureus. 2016;8:e498.

92

Smith et al. 2003 – Weak Evidence

- Case-control study
- Reported association with VAD
- Limitations: temporality, bias

Smith WS et al. Neurology. 2003;60:1424–1428.

93

Rothwell et al. 2001 – Weak Evidence

- Population-based case-control
- Association in younger patients
- Confounding by prodromal symptoms likely

Rothwell DM et al. Stroke. 2001;32:1054–1060.

94

AHA/ASA Statement 2014 – Weak Evidence

- Scientific statement
- Association recognized, causation uncertain
- Emphasizes difficulty in proving causation

Biller J et al. Stroke. 2014;45:3155–3174.

95

Ernst Reviews – Weak Evidence

- Systematic reviews of adverse events
- Based largely on case reports
- Cannot establish causation or incidence

Ernst E. J R Soc Med. 2007;100:330–338.
Ernst E. Med J Aust. 2002;176:376–380.

96

Wynd et al. 2013 – Weak Evidence

- Quality assessment of case reports
- Highlights major methodological limitations

Wynd S et al. PLoS One. 2013;8:e59170.

97

Weak Evidence

- Narrative reviews of mechanisms
- Proposed thromboembolic plausibility
- Bias
- Poor methodology
- No direct causal evidence

98

Core Questions

- Is embolization triggered by an external event?
- Or is it an intrinsic vascular process?
- Critical for clinical and medico-legal decisions
- Answer determines causation validity

99

CAD Pathophysiology

- Intimal disruption or intramural hematoma
- Platelet aggregation and thrombus formation
- Irregular lumen and turbulent flow
- Disease often precedes clinical encounter

100

Primary Stroke Mechanism

- ~85% embolic (artery-to-artery)
- Not external compression or occlusion
- Thrombus → embolus → ischemia → infarct

101

Drivers of Embolization

- Intrinsic thrombus instability
- Hemodynamic shear stress
- Turbulent flow patterns
- Ongoing thrombus remodeling

102

Hemodynamics

- Continuous pulsatile flow
- Shear stress at dissection site
- Turbulence at intimal flap
- Not event-specific forces

103

Hemodynamics



[RESEARCH REPORT]

HENDRIKUS ANTONIUS "RIK" KRANENBURG, PT[a] • ROB TYER, PT[b] • MAARTEN SCHMITT, PT, PhD[c] • GERT JAN LIJCKX, MD, PhD[d]
CEES VAN DER SCHANS, PT, PhD[a,e] • NATHAN HUTTING, PT, PhD[f,g] • ROGER KERRY, PT, PhD[h]

Effects of Head and Neck Positions on Blood Flow in the Vertebral, Internal Carotid, and Intracranial Arteries: A Systematic Review

Manual therapy interventions for the management of people with head and neck pain utilize various positions and movements of the craniocervical region. These interventions have rarely been associated with adverse events.[1,2,3,4] Exact incidence rates of adverse events are unknown, and causality between intervention and adverse event is debated.[2,3,5] Variables such as specific techniques, screening tests, and patient characteristics have been studied in an attempt to enhance the safety of treatment. Unfortunately, studies have been unable to identify specific variables related to the risk of adverse events.[1,2,3,5,6,7,8] However, a suspicion that high-velocity thrust (HVT) techniques may be associated with adverse events remains.[3,5,9]

Understanding the clinical relevance of arterial pathologies is essential for health care professionals working with the cervical spine.[10] The broad range of pathologies relevant to clinical reasoning and selecting appropriate interventions are defined by the umbrella term *cervical arterial dysfunction* (CAD).[11] This includes arterial events ranging from atherosclerotic disease to mechanical trauma of vessels. One of the most frequently described adverse events following cervical treatment techniques is arterial dissection.[10] Although many other pathological processes are of concern, dissection serves as a useful model to understand the relationship between cervical movement and arterial pathology. The pathophysiology of a dissection is not completely clear. A

104

Natural History

- Thrombus propagation and fragmentation
- Delayed embolization
- Symptoms precede neurologic deficits

105

No Discrete Trigger

- No consistent external trigger identified
- Occurs spontaneously
- Occurs during normal activity

106

Causation Question

- Does chiropractic care trigger embolization?
- Requires biological plausibility
- Requires epidemiologic evidence
- **Association ≠ Causation**

107

Epidemiology

- No increased stroke risk vs medical care
- Patients present with early symptoms
- Strong protopathic bias

108

Mechanistic Evidence

- SMT strain below physiologic thresholds
- Comparable or less than daily motion
- No thrombus disruption evidence

109

What Is Missing?

- No proof SMT causes thrombus formation
- No proof SMT triggers embolization
- No reproducible causal evidence

110

Bradford Hill Criteria

- The **Bradford Hill Criteria** are a set of nine epidemiologic principles used to help determine whether an observed association between an exposure and an outcome is likely to be causal rather than coincidental.
  - Strength: weak
  - Consistency: lacking
  - Temporality: confounded
  - Plausibility: unsupported

111

Most Plausible Explanation

- Spontaneous dissection occurs first
- Symptoms prompt care-seeking
- Stroke follows natural progression

112

Medico-Legal Summary

- Embolization is intrinsic to CAD
- Driven by vascular pathology
- No external trigger required
- No high-quality evidence of causation

113

Clinical Implications

- Recognize early symptoms
- Identify neurologic deficits
- Refer emergently
- Document thoroughly

114

Associated but NOT Causal…

- The **best epidemiologic studies** generally support **association without proven causation** and emphasize **confounding by indication**:
  - Patients with evolving cervical artery dissection often present with neck pain or headache and may seek chiropractic or medical care before stroke.
  - The thromboembolic theory is biologically plausible mainly when a pre-existing dissection with thrombus is already present, but **the literature proving that CSM itself dislodges thrombus is weak and largely inferential.**

115

Dissection and Thromboembolism?

When possible, we must identify neurologic signs of ischemia and infarct.



PostGradDC Summary Assessment for CAD/Stroke

Clinical History & Predisposition Screening
- Recent neck or head trauma (e.g., MVC, falls, sports)
- Connective tissue disorders, loose joint syndrome
- Fibromuscular dysplasia
- Fluoroquinolone, oral contraceptive, and blood thinner use
- Arteriopathy
- Family, past personal history of stroke, coagulopathies, PFO, Afib, etc.

Red Flag Symptoms
- Sudden, severe, unilateral, anterior or posterior neck pain or headache
- Visual disturbances (diplopia, vision loss), CN abnormalities
- Horner's syndrome (ptosis, miosis, anhidrosis)
- Dysarthria, dysphagia, vertigo, ataxia
- Focal neurologic deficits (weakness, numbness)

Physical/Complete Neurological Exam
- Vitals
- Cranial and peripheral nerve examination
- Cerebellar function, gait, and balance
- Extremity motor, reflex, and sensory testing
- Auscultation of carotid/vertebral bruits
- Beighton scale

Emergent Medical Referral
- Refer and communicate with emergency services
- Convey diagnosis and emergent need for CTA, MRA of neck, MRI brain
- Document
- Follow-up

116

Purpose

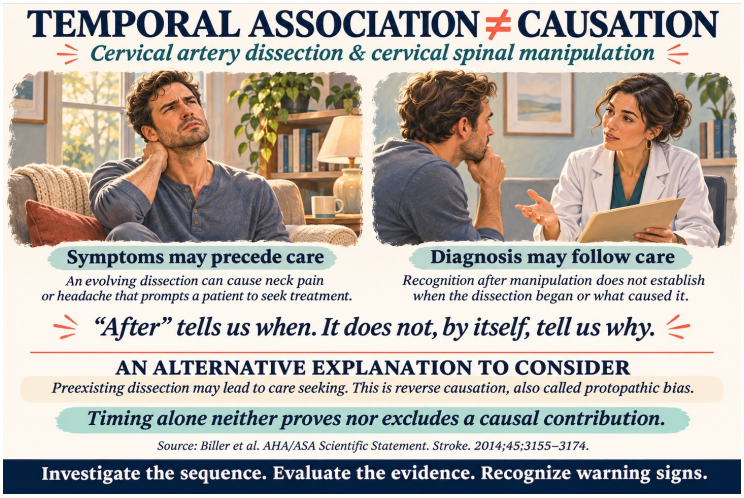

117

Cervical Artery Dissection: Risk and Risk Factors

James Demetrious, DC, DABCO
Diplomate, American Board of Chiropractic Orthopedists

www.PostGradDC.com

118

AHA/ASA Scientific Statement

Cervical Arterial Dissections and Association With Cervical Manipulative Therapy

A Statement for Healthcare Professionals From the American Heart Association/American Stroke Association

- Although the incidence of CD in CMT patients is probably low, **[???]** and causality difficult to prove, **[???]** practitioners should both strongly consider the possibility of CD **[???]** and inform patients of the statistical association **[???]** between CD and CMT, prior to performing manipulation of the cervical spine.

Stroke. 2014;45:3155-3174.

119

Incidence Rates and Rarity of CAD



Stroke

Check for updates

CLINICAL AND POPULATION SCIENCES

Epidemiology of Spontaneous Cervical Artery Dissection: Population-Based Study

Kim J. Griffin, MD; William S. Harmsen, MS; Jay Mandrekar, PhD; Robert D. Brown Jr, MD; Zafer Kesse, MD

BACKGROUND: Cervical artery dissection (CeAD) represents up to 15% to 25% of ischemic strokes in people under the age of 50 years. Noninvasive vessel imaging is increasingly used in clinical practice, but the impact on the frequency of detection of CeAD is unknown. In 2005, the yearly incidence rate of CeAD was estimated at 2.6 per 100 000 person-years, but the current incidence is unknown.

METHODS: In this population-based retrospective observational cohort study, we utilized the resources of the Rochester Epidemiology Project to ascertain all adult residents of Olmsted County, MN, diagnosed with internal carotid artery dissection and common carotid artery dissection or vertebral artery dissection from 2002 to 2020. Patients with only intracranial involvement or CeAD following major trauma were excluded. Age-adjusted sex-specific and age- and sex-adjusted incidence rates were estimated using the US White 2010 decennial census, with rates expressed per 100 000 person-years. We assessed longitudinal trends by dividing the data into 5-year time intervals, with the last being a 4-year interval.

RESULTS: We identified 123 patients with a diagnosis of CeAD. There were 63 patients with internal carotid artery dissection, 54 with vertebral artery dissection, 2 with concurrent internal carotid artery dissection and vertebral artery dissection, and 4 with common carotid artery dissection. There were 63 (51.2%) female patients and 60 (48.8%) male patients. The average age at diagnosis was 50.2 years (SD, 15.1 [95% CI, 20.1–90.5] years). The incidence rate of spontaneous CeAD encompassing all locations was 4.69 per 100 000 person-years (2.43 for internal carotid artery dissection and 2.01 for vertebral artery dissection). The incidence rate increased from 2.30 per 100 000 person-years from 2002 to 2006 to 8.93 per 100 000 person-years from 2017 to 2020 (P<0.0001). The incidence rate for female patients rose from 0.81 per 100 000 person-years from 2002 to 2006 to 10.17 per 100 000 person-years from 2017 to 2020.

CONCLUSIONS: The incidence rate of spontaneous CeAD increased nearly 4-fold over a 19-year period from 2002 to 2020. The incidence rate in women rose over 12-fold. The increase in incidence rates likely reflects the increased use of noninvasive vascular imaging.

GRAPHIC ABSTRACT: A graphic abstract is available for this article.

Key Words: adult ■ arteries ■ dissection ■ epidemiologic studies ■ incidence ■ neck pain ■ stroke

Cervical artery dissection (CeAD) is an uncommon cause of ischemic stroke. However, in adults under the age of 50 years, CeADs represent up to 15% to 25% of ischemic strokes.[1,2] CeAD often presents with local compressive symptoms, such as headache/neck pain and Horner syndrome, but many remain asymptomatic.[3]

This diversity in presentations contributes to a scarcity of epidemiological data for CeAD. A study from the Dijon Stroke Registry noted a raw incidence rate of ≈2.97 per 100 000/y but there are otherwise limited recent data.[1,4] Many key epidemiological studies are decades old. Our institution previously reported the incidence of spontaneous internal carotid artery dissections (ICADs) in 1965,

Correspondence to: Zafer Kesse, MD, Department of Neurology, Cerebrovascular Division Mayo Clinic, 200 First St, SW, Rochester, MN 55905. Email kesse.zafer@mayo.edu

This manuscript was sent to Emmanuel Touzé, Guest Editor, for review by expert referees, editorial decision, and final disposition.

Supplemental Material is available at https://www.ahajournals.org/doi/suppl/10.1161/STROKEAHA.123.043647.

For Sources of Funding and Disclosures, see page 676.

© 2024 American Heart Association, Inc.

Stroke is available at www.ahajournals.org/journal/str

670 March 2024

Stroke. 2024;55:670–677. DOI: 10.1161/STROKEAHA.123.043647

- The incidence rate of spontaneous CeAD encompassing all locations was 4.69 per 100 000 person-years:
  - 2.43 for internal carotid artery dissection and
  - 2.01 for vertebral artery dissection.
- The incidence rate increased from 2.30 per 100 000 person-years from 2002 to 2006 to 8.93 per 100 000 person-years from 2017 to 2020 (P<0.0001).

120



Kosloff et al. Chiropractic & Manual Therapies (2015) 23:19
DOI 10.1186/s12998-015-0063-x

CHIROPRACTIC & MANUAL THERAPIES

RESEARCH Open Access

Chiropractic care and the risk of vertebrobasilar stroke: results of a case–control study in U.S. commercial and Medicare Advantage populations

Thomas M Kosloff[1*†], David Elton[1†], Jiang Tao[2†] and Wade M Bannister[2†]

Conclusions

•We found no significant association between exposure to chiropractic care and the risk of VBA stroke.

•We conclude that manipulation is an unlikely cause of VBA stroke.

121



Taylor & Francis

Annals of Medicine

ISSN: 0785-3890 (Print) 1365-2060 (Online) Journal homepage: https://www.tandfonline.com/loi/iann20

A risk–benefit assessment strategy to exclude cervical artery dissection in spinal manual-therapy: a comprehensive review

Aleksander Chaibi & Michael Bjørn Russell

To cite this article: Aleksander Chaibi & Michael Bjørn Russell (2019) A risk–benefit assessment strategy to exclude cervical artery dissection in spinal manual-therapy: a comprehensive review, Annals of Medicine, 51:2, 118-127, DOI: 10.1080/07853890.2019.1590627

- In a comprehensive review of the literature published in the Annals of Medicine, Chaibi and Russell concluded, **"Manual therapy does not result in an increased risk of CAD." Additionally, the authors state, "…there is no firm scientific basis for direct causality between cervical spinal manipulative therapy and CAD."**

122

ANNALS OF MEDICINE
2019, VOL. 51, NO. 2, 118–127
https://doi.org/10.1080/07853890.2019.1590627

Taylor & Francis
Taylor & Francis Group

REVIEW ARTICLE

OPEN ACCESS Check for updates

A risk–benefit assessment strategy to exclude cervical artery dissection in spinal manual-therapy: a comprehensive review

Aleksander Chaibi[a,b] and Michael Bjørn Russell[a,b]

[a]Head and Neck Research Group, Research Centre, Akershus University Hospital, Oslo, Norway; [b]Institute of Clinical Medicine, Akershus University Hospital, University of Oslo, Nordbyhagen, Norway

- Consider the rarity of CAD, which reportedly constitutes as few as 1 per 8.1 million chiropractic office visits and 1 per 5.9 million cervical manipulations by practicing chiropractors in Canada.

123

ANNALS OF MEDICINE
2019, VOL. 51, NO. 2, 118–127
https://doi.org/10.1080/07853890.2019.1590627

Taylor & Francis
Taylor & Francis Group

REVIEW ARTICLE

OPEN ACCESS Check for updates

A risk–benefit assessment strategy to exclude cervical artery dissection in spinal manual-therapy: a comprehensive review

Aleksander Chaibi[a,b] and Michael Bjørn Russell[a,b]

[a]Head and Neck Research Group, Research Centre, Akershus University Hospital, Oslo, Norway; [b]Institute of Clinical Medicine, Akershus University Hospital, University of Oslo, Nordbyhagen, Norway

Manual therapy does not result in an increased risk of CAD.

- Cassidy et al. Risk of vertebrobasilar stroke and chiropractic care: results of a population-based case-control and case-crossover study. Spine. 2008;33(4 Suppl):S176-83.
- Church et al. Systematic review and meta-analysis of chiropractic care and cervical artery dissection: no evidence for causation. Cureus. 2016;8(2):e498.
- Cassidy et al. Risk of carotid stroke after chiropractic care: a population-based case-crossover study. J Stroke Cerebrovasc Dis. 2017;26(4):842-850.

124

Spine (Phila Pa 1976). 2008 Feb 15;33(4 Suppl):S176-83. doi: 10.1097/BRS.0b013e3181644600.

Risk of vertebrobasilar stroke and chiropractic care: results of a population-based case-control and case-crossover study

J David Cassidy [1], Eleanor Boyle, Pierre Côté, Yaohua He, Sheilah Hogg-Johnson, Frank L Silver, Susan J Bondy

Affiliations + expand

PMID: 18204390 DOI: 10.1097/BRS.0b013e3181644600

Conclusion: VBA stroke is a very rare event in the population. The increased risks of VBA stroke associated with chiropractic and PCP visits is likely due to patients with headache and neck pain from VBA dissection seeking care before their stroke. We found no evidence of excess risk of VBA stroke associated chiropractic care compared to primary care.

125

J Stroke Cerebrovasc Dis. 2017 Apr;26(4):842-850.
doi: 10.1016/j.jstrokecerebrovasdis.2016.10.031. Epub 2016 Nov 21.

Risk of Carotid Stroke after Chiropractic Care: A Population-Based Case-Crossover Study

J David Cassidy [1], Eleanor Boyle [2], Pierre Côté [3], Sheilah Hogg-Johnson [4], Susan J Bondy [5], Scott Haldeman [6]

Affiliations + expand

PMID: 27884458 DOI: 10.1016/j.jstrokecerebrovasdis.2016.10.031

- In 2017, Cassidy et al. published the results of a large population-based, case-crossover study in the Journal of Stroke and Cerebrovascular Diseases. The authors found **no excess of carotid artery stroke following chiropractic care and confirmed that patients sought care with early dissection related symptoms before developing strokes.**

126

ARTICLE IN PRESS

Risk of Carotid Stroke after Chiropractic Care: A Population-Based Case-Crossover Study

J. David Cassidy, DC, PhD, DrMedSc,*†‡ Eleanor Boyle, PhD,*‡ Pierre Côté, DC, PhD,‡§ Sheilah Hogg-Johnson, PhD,‖¶ Susan J. Bondy, PhD,‡ and Scott Haldeman, MD, PhD#

- Positive associations were found for both chiropractic and PCP visits and subsequent stroke in patients less than 45 years of age.

- There was no significant difference between chiropractic and PCP risk.

Journal of Stroke and Cerebrovascular Diseases, Vol. ■■, No. ■■ (■■), 2016: pp ■■–■■

127

Cureus

Open Access Original Article

DOI: 10.7759/cureus.498

Systematic Review and Meta-analysis of Chiropractic Care and Cervical Artery Dissection: No Evidence for Causation

Ephraim W. Church [1], Emily P. Sieg [1], Omar Zalatimo [1], Namath S. Hussain [1], Michael Glantz [1], Robert E. Harbaugh [1]

1. Department of Neurosurgery, Penn State Hershey Medical Center

Corresponding author: Ephraim W. Church, echurch@hmc.psu.edu

Disclosures can be found in Additional Information at the end of the article

- In 2016, Church et al. reported, **"There is no convincing evidence to support a causal link between chiropractic manipulation and CAD."** The authors reported an unfounded belief in causation might have dire consequences.

128

Open Access Original Article

DOI: 10.7759/cureus.498

Systematic Review and Meta-analysis of Chiropractic Care and Cervical Artery Dissection: No Evidence for Causation

Ephraim W. Church [1], Emily P. Sieg [1], Omar Zalatimo [1], Namath S. Hussain [1], Michael Glantz [1], Robert E. Harbaugh [1]

1. Department of Neurosurgery, Penn State Hershey Medical Center

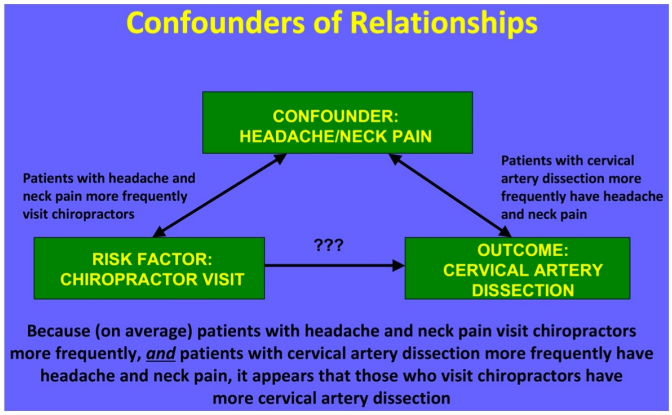

FIGURE 3: The association between a chiropractor visit and dissection may be explained by headache/neck pain, a likely confounder.

129

CAD...Protopathic Bias

130

FQ and CAD… A Protopathic Event

- **History and Etymology for *protopathic***
  - International Scientific Vocabulary, from Middle Greek ***prōto****pathēs* affected **first**,
  - from Greek *prōt-* prot- + ***pathos*** experience, **suffering** — more at PATHOS

131

Cerebrovascular Diseases

Letter to the Editor

Cerebrovasc Dis 2021;50:483–484
DOI: 10.1159/000515105

Received: January 1, 2021
Accepted: January 23, 2021
Published online: March 29, 2021

Response to Differential Risk Factors of Ischemic Stroke

Vivian Chun Kyle Lin Stephen M. Perle

University of Bridgeport, College of Health Sciences, School of Chiropractic, Bridgeport, CT, USA

"Given the fact that Garg et al. were aware of the potential for protopathic bias as the cause for the elevated risk for CeAD after cervical manipulation, why did they not test for this by including primary care physician visits and neck pain in their analysis."

132

Mild, Transient AEs

- [47] WHO. Guidelines on basic training and safety in chiropractic. Switzerland: World Health Organization; 2005.
- [48] Cagnie B, Vinck E, Beernaert A, et al. How common are side effects of spinal manipulation and can these side effects be predicted? Man Ther. 2004;9:151–156.
- [49] Hurwitz EL, Morgenstern H, Vassilaki M, et al. Adverse reactions to chiropractic treatment and their effects on satisfaction and clinical outcomes among patients enrolled in the UCLA Neck Pain Study. J Manipulative Physiol Ther. 2004;27:16–25.
- [50] Thiel HW, Bolton JE, Docherty S, et al. Safety of chiropractic manipulation of the cervical spine: a prospect- ive national survey. Spine (Phila, PA, 1976). 2007;32: 2375–2378.
- [51] Rubinstein SM, Leboeuf-Yde C, Knol DL, et al. The benefits outweigh the risks for patients undergoing chiropractic care for neck pain: a prospective, multi- center, cohort study. J Manipulative Physiol Ther. 2007;30:408–418.
- [52] Eriksen K, Rochester RP, Hurwitz EL. Symptomatic reactions, clinical outcomes and patient satisfaction associated with upper cervical chiropractic care: a prospective, multicenter, cohort study. BMC Musculoskelet Disord. 2011;12:219.
- [53] Walker BF, Hebert JJ, Stomski NJ, et al. Outcomes of usual chiropractic. The OUCH randomized controlled trial of adverse events. Spine. 2013;38:1723–1729.
- [54] Maiers M, Evans R, Hartvigsen J, et al. Adverse events among seniors receiving spinal manipulation and exercise in a randomized clinical trial. Man Ther. 2015; 20:335–341.
- [55] Chaibi A, Benth JS, Tuchin P, et al. Adverse events in a chiropractic spinal manipulative therapy single- blinded, placebo, randomized controlled trial for migraineurs. Musculoskelet Sci Pract. 2017;29:66–71.

Chaibi and Russell. ANNALS OF MEDICINE. 2019, VOL. 51, NO. 2, 118–127.

133

J Manipulative Physiol Ther. 2008 Jul-Aug;31(6):461-4. doi: 10.1016/j.jmpt.2008.06.001.

Adverse events following chiropractic care for subjects with neck or low-back pain: do the benefits outweigh the risks?

Sidney M Rubinstein [1]

Affiliations – collapse

Affiliation

1 Institute for Research in Extramural Medicine, EMGO-Institute, VU University Medical Center, 1081 BT Amsterdam, The Netherlands. sm.rubinstein@vumc.nl

PMID: 18722202 DOI: 10.1016/j.jmpt.2008.06.001

- Most adverse events associated with spinal manipulation are benign and self-limiting.
- The incidence of severe complications following chiropractic care and manipulation is extremely low.
- The best evidence suggests that chiropractic care is a useful therapy for subjects with neck or low-back pain for which the risks of serious adverse events should be considered negligible.

134

Eur Spine J (2008) 17 (Suppl 1): S176-S183
DOI 10.1007/s00586-008-0634-9

Risk of Vertebrobasilar Stroke and Chiropractic Care

Results of a Population-Based Case-Control and Case-Crossover Study

J. David Cassidy, DC, PhD, DrMedSc,*†‡ Eleanor Boyle, PhD,* Pierre Côté, DC, PhD,*†‡§ Yaohua He, MD, PhD,* Sheilah Hogg-Johnson, PhD,†§ Frank L. Silver, MD, FRCPC,¶|| and Susan J. Bondy, PhD†

- The source population included all residents of Ontario (109,020,875 person-years of observation over 9 years) covered by the publicly funded Ontario Health Insurance Plan (OHIP).
- Available utilization data included hospitalizations with diagnostic coding, and practitioner (physician and chiropractic) utilization as documented by fee-for-service billings accompanied by diagnostic coding.

135

Eur Spine J (2008) 17 (Suppl 1): S176-S183
DOI 10.1007/s00586-008-0634-9

Risk of Vertebrobasilar Stroke and Chiropractic Care

Results of a Population-Based Case-Control and Case-Crossover Study

J. David Cassidy, DC, PhD, DrMedSc,*†‡ Eleanor Boyle, PhD,* Pierre Côté, DC, PhD,*†‡§ Yaohua He, MD, PhD,* Sheilah Hogg-Johnson, PhD,†§ Frank L. Silver, MD, FRCPC,¶|| and Susan J. Bondy, PhD†

- **Conclusion.**
  - VBA stroke is a very rare event in the population.
  - The increased risks of VBA stroke associated with chiropractic and PCP visits is likely due to patients with headache and neck pain from VBA dissection seeking care before their stroke.
  - We found no evidence of excess risk of VBA stroke associated chiropractic care compared to primary care.

136

Eur Spine J (2008) 17 (Suppl 1): S176-S183
DOI 10.1007/s00586-008-0634-9

Risk of Vertebrobasilar Stroke and Chiropractic Care

Results of a Population-Based Case-Control and Case-Crossover Study

J. David Cassidy, DC, PhD, DrMedSc,*†‡ Eleanor Boyle, PhD,* Pierre Côté, DC, PhD,*†‡§ Yaohua He, MD, PhD,* Sheilah Hogg-Johnson, PhD,†§ Frank L. Silver, MD, FRCPC,¶‖ and Susan J. Bondy, PhD†

- There is an association between vertebrobasilar artery stroke and chiropractic visits in those under 45 years of age.
- We found no evidence of excess risk of VBA stroke associated chiropractic care.
- The increased risks of vertebrobasilar artery stroke associated with chiropractic and physician visits is likely explained by patients with vertebrobasilar dissection-related neck pain and headache consulting both chiropractors and primary care physicians before their VBA stroke.

137

13x Increased Risk?

- **Murphy:**
  - There is nothing in the Cassidy study that demonstrates that a patient is more likely to have a stroke after seeing a chiropractor within one day compared to an MD or PCP, let alone a 13-fold difference.

138

13x Increased Risk?

- **Rubinstein:**
  - The important points being, there were too few cases to calculate an effect, as evidenced by the unstable (read: very wide 95% CI's).
  - However, what makes it slightly complicated is, there is no comparison to the PCP, because that began at day 1.
  - Nevertheless, those OR's also demonstrate (similar) unstable effects.
  - The conclusion remains, the odds are similar for a visit to the chiropractor as for the PCP; providing strong evidence to support the hypothesis that patients seek care for an underlying CAD in development.
  - Lastly, I think that one can also conclude, that if SMT of the neck was dangerous and chiropractors practiced irresponsibly, the incidence of CAD would be much higher than 1 in a million treatments or 1 in 100,000 patients (give or take).

139

SMT is Safe

- Thus, these studies support the evidence of spontaneous causality or minimally suggest a very low risk for serious AEs following SMT [41,73,74].
  - [41] Tuchin P. A replication of the study 'Adverse effects of spinal manipulation: a systematic review'. Chiropr Man Ther. 2012;20:30.
  - [73] Gouveia LO, Castanho P, Ferreira JJ. Safety of chiro- practic interventions: a systematic review. Spine (Phila, PA, 1976). 2009;34:E405–E413.
  - [74] Whedon JM, Song Y, Mackenzie TA, et al. Risk of stroke after chiropractic spinal manipulation in medi- care B beneficiaries aged 66 to 99 years with neck pain. J Manipulative Physiol Ther. 2015;38:93–101.
- There is no strong evidence in the literature that manual therapy provokes CAD.

140

No Association with Traumatic Injury

- Retrospective cohort studies have reported no association with traumatic injury to the head or neck after SMT for neuromusculoskeletal pain [69].
  - [69] Whedon JM, Mackenzie TA, Phillips RB, et al. Risk of traumatic injury associated with chiropractic spinal manipulation in Medicare Part B beneficiaries aged 66 to 99 years. Spine. 2015;40:264–270.

141

SMT Strains Do Not Exceed Failure Strains

- Invasive studies have further disproven any misconception as to whether VA strains during head movements, including SMT, exceed failure strains [70,71].
  - [70] Herzog W, Leonard TR, Symons B, et al. Vertebral artery strains during high-speed, low amplitude cervical spinal manipulation. J Electromyogr Kinesiol. 2012;22:740–746.
  - [71] Piper SL, Howarth SJ, Triano J, et al. Quantifying strain in the vertebral artery with simultaneous motion analysis of the head and neck: a preliminary investigation. Clin Biomech (Bristol, Avon). 2014;29:1099–1107.

142

AHA/ASA Scientific Statement

Cervical Arterial Dissections and Association With Cervical Manipulative Therapy

A Statement for Healthcare Professionals From the American Heart Association/American Stroke Association

Factors Associated With CD:

- Major and minor cervical trauma
- Arterial hypertension
- Young age
- Current use of oral contraceptives
- Migraine
- Fibromuscular dysplasia
- Ultrastructural connective tissue abnormalities
- Vascular subtype of Ehlers-Danlos syndrome
- Marfan syndrome
- Turner syndrome
- Williams syndrome
- Familial cases
- Hereditary hemochromatosis
- Osteogenesis imperfecta type I
- α1-Antitrypsin deficiency
- 677T genotype MTHFR
- Hyperhomocysteinemia
- Cystic medial necrosis of intracranial vessels
- Styloid process length
- ICAM-1 E4690 K gene polymorphism
- Autosomal-dominant polycystic kidney disease
- Infections [INFECTION OR FQs???]
- Moyamoya disease
- Lentiginosis [FRECKLES…REALLY???]
- Vessel redundancies (coils, kinks, loops), especially if bilateral
- **Fluoroquinolones NOT Identified**

Stroke. 2014;45:3155-3174.

POSTGRADDC
EVIDENCE BASED, CLINICALLY INTUITIVE CE

143

CAD Risk Factors?

- **Open Neurol J. 2010; 4: 50–55. Cervical Artery Dissection: Emerging Risk Factors**
  - Primary disease of arterial wall (fibrodysplasia), Ehlers Danlos-syndrome IV, Marfan's syndrome, vessel tortuosity, recent respiratory tract infection, migraine, hyperhomocysteinemia, major head/neck trauma like chiropractic maneuver, coughing or hyperextension injury associated to car.
- **Lancet Neurol. 2009 Jul;8(7):668-78. Cervical-artery dissections: predisposing factors, diagnosis, and outcome.**
  - Trauma to the neck, infection, migraine, hyperhomocysteinaemia, underlying arteriopathy
- **Stroke. 2005 Jul;36(7):1575-80. A systematic review of the risk factors for cervical artery dissection.**
  - Aortic root diameter >34 mm, trauma, homocysteine, and recent infection.

POSTGRADDC
EVIDENCE BASED, CLINICALLY INTUITIVE CE

James Demetrious, DC, DABCO

144

144

Risk Factors for CeAD and Related Stroke



Open access Systematic review

SVN Stroke & Vascular Neurology

Risk factors for cervical artery dissection: a systematic review with meta-analysis

Wilco Jacobs ,[1,2] Debbie S Wright,[3] Katherine Pohlman ,[3] Rob Rosenbaum,[4] Barbara A Hutten,[5] Gwendolyne GM Scholten-Peeters,[6] Scott Haldeman,[7] Johannes CF Ket,[8] Sidney M Rubinstein [2]

To cite: Jacobs W, Wright DS, Pohlman K, *et al*. Risk factors for cervical artery dissection: a systematic review with meta-analysis. *Stroke & Vascular Neurology* 2025;0. doi:10.1136/svn-2025-004186

► Additional supplemental material is published online only. To view, please visit the journal online (https://doi.org/10.1136/svn-2025-004186).

Received 5 March 2025
Accepted 16 July 2025

Check for updates

© Author(s) (or their employer(s)) 2025. Re-use permitted under CC BY-NC. No commercial re-use. See rights and permissions. Published by BMJ Group.

For numbered affiliations see end of article.

Correspondence to
Dr Wilco Jacobs
wilco@thewalthacenter.nl

ABSTRACT

Background Cervical artery dissection (CAD) is a rare cause of stroke. This is an update of an earlier systematic review, which focuses on the risk of CAD in the general population. The objective was to identify the risk factors for CAD.

Methods A comprehensive search was conducted in MEDLINE, EMBASE and Web of Science on 20 September 2024. Observational studies (cohort, case-control studies and case-crossover studies) that studied patients with CAD and a control group were included. Risk of bias was assessed with the ROBINS-E tool, and certainty of the evidence was assessed using Grading of Recommendations Assessment, Development and Evaluation (GRADE). The results were stratified by healthy controls (primary analyses) and other control groups, notably ischaemic non-CAD stroke (secondary analyses).

Findings In total, 126 study reports were identified, of which 54 used one or more healthy control groups. Of those reports, 49 (91%) used a case-control design. The risk of bias was generally high (93%). For the following categories, effects were identified: (1) genetic factors or factors with a familial predisposition: migraine, methylenetetrahydrofolate reductase (MTHFR) TT homozygosity, matrix metalloproteinases (MMP) concentration, and connective tissue disorders; (2) external factors: recent infection, winter or autumn–winter season and oral contraceptive use; (3) minor trauma; (4) cardiovascular factors: hypertension, hypercholesterolaemia, relative vasodilatation of internal carotid, coronary artery disease and other cardiac diseases. For other risk factors (5), there were no significant pooled estimates. The certainty of the evidence was moderate for migraine and MTHFR TT, low for minor trauma and very low certainty for all others.

Interpretation This is the first review that comprehensively examined the risk of CAD in the general population. Genetic factors, cardiovascular risk factors, recent infection and minor trauma are risk factors for CAD. Caution is needed in interpretation as the evidence is overall low to very low certainty, except for migraine and MTHFR TT homozygosity.

WHAT IS ALREADY KNOWN ON THIS TOPIC

⇒ Cervical artery dissection (CAD) is a rare vascular pathology which affects about 9 in 100 000 young and otherwise healthy people per year. A recent study suggests that most are asymptomatic, with up to two of 100 cases of CAD resulting in ischaemic intracerebral stroke.

⇒ Several potential risk factors of CAD have been suggested based on case series and cross-sectional studies using all source stroke populations as controls. Still, a comprehensive review of risk factors in the general population is lacking as many of these studies based on stroke populations have a high risk of bias.

WHAT THIS STUDY ADDS

⇒ We included cohort, case-crossover studies and case-control studies with healthy control groups or stroke control groups.

⇒ Genetic factors, cardiovascular risk factors, recent infection and minor trauma are risk factors for CAD in the general population. The best evidence with a moderate level of certainty shows that migraine and methylenetetrahydrofolate reductase TT homozygosity are important risk factors for CAD.

HOW THIS STUDY MIGHT AFFECT RESEARCH, PRACTICE OR POLICY

⇒ Knowledge of risk factors may help identify those at risk of CAD and may assist general practitioners in clinical reasoning and determining when to refer patients for hospital care.

INTRODUCTION

Cervical artery dissection (CAD) is a vascular condition involving a false, blood-filled lumen between the vessel wall layers, most commonly occurring in the vertebral and carotid arteries.[1] Spontaneous CAD refers to occurrence without obvious major trauma. Knowledge about the incidence of CAD is limited due to the underdiagnosis of asymptomatic cases. In the healthy adult population, CAD occurs at a rate of 8.95 per 100 000 person-years,[2] while CAD accompanied by stroke occurs at a rate of 2.97 per 100 000 person-years.[3] Between 0 and 13.5% of adult CAD patients experience a stroke within the first 6 weeks,[4–6] but this estimate is dependent on the hospital setting with stroke centres

Protected by copyright, including for uses related to text and data mining, AI training, and similar technologies.

Open access

Table 1 Summary of findings table: Genetic factors or factors with a familial predisposition

Risk factor	Pooled estimate (95% CI)	Number of participants (Studies)	Certainty of the evidence (GRADE)*	Comments
MMP lab (SMD)	2 (0.74 to 3.27)	356 (2)[25 43]	Very low[1 2 6]	
Connective tissue disorder (OR)	2.21 (1.06 to 4.59)	485 (3)[37 42 50]	Very low[1 4 6]	
Migraine (OR)	2.34 (1.58 to 3.48)	2218 (5)[18 27 30 36 52]	Moderate[1 6 7]	
MTHFR TT (OR)	2.94 (1.8 to 4.78)	533 (3)[54 57 58]	Moderate[1 6 8]	
Extra cellular Matrix regulating genes (OR)	3.59 (0.49 to 26.3)	33 610 (2)[33 48]	Very low[1 2 4]	
TGFB genes (OR)	–	134 630 (2)[33 55]	Very low[1 2 4 6]	Too few observations, individual studies used Fisher exact analyses

Summary of findings: Risk factors for cervical artery dissection - Genetic factors or factors with a familial predisposition.
Patient population: Patients with cervical artery dissection with or without stroke Exposed (Control) populations: General healthy population
Outcome: Cervical artery dissection.
GRADE Working Group grades of evidence: High certainty: We are very confident that the true effect lies close to that of the estimate of the effect. Moderate certainty: We are moderately confident in the effect estimate: The true effect is likely to be close to the estimate of the effect, but there is a possibility that it is substantially different. Low certainty: Our confidence in the effect estimate is limited: The true effect may be substantially different from the estimate of the effect. Very Low certainty: We have very little confidence in the effect estimate: The true effect is likely to be substantially different from the estimate of effect.
*Downgraded for 1 Risk of bias 2 Inconsistency 3 Indirectness 4 Imprecision 5 Publication bias. Upgraded for 6 Large effect 7 Plausible residual confounding 8 Dose response gradient
MMP, matrix metalloproteinases; MTHFR, methylenetetrahydrofolate reductase; OR, odds ratio; SMD, standardised mean difference; TGFB, transforming growth factor β.

145

Risk Factors for CeAD and Related Stroke

Open access

Table 2 Summary of findings table: External factors

Risk factor	Pooled estimate (95% CI)	Number of participants (Studies)	Certainty of the evidence (GRADE)*	Comments
Recent infection (OR)	2.03 (1.33 to 3.09)	NA (5)[40 49 61 69 90]	Very low[1 4]	
White blood cells (SMD)	1.46 (0.99 to 1.93)	323 (2)[26 66]	Very low[1 3]	
Winter or autumn–winter season (OR)	1.37 (1.04 to 1.82)	826 (2)[51 60]	Very low[1]	
Oral contraceptive use (OR)	1.81 (1.07 to 3.06)	1226 (4)[18 27 52 56]	Very low[1]	
Current Alcohol user (OR)	0.94 (0.82 to 1.09)	3322 (3)[29 50 58]	Very low[1]	

Summary of findings: Risk factors for cervical artery dissection - External factors.

Patient population: Patients with cervical artery dissection with or without stroke Exposed (Control) populations: General healthy population] Outcome: Cervical artery dissection

For GRADE decisions see table 1 footnote
NA, not applicable; OR, odds ratio; SMD, standardised mean difference.

146

Risk Factors for CeAD and Related Stroke

Table 3 Summary of findings table: Minor trauma

Risk factor	Pooled estimate (95% CI)	Number of participants (Studies)	Certainty of the evidence (GRADE)*	Comments
Minor trauma (OR)	4.33 (1.96 to 9.56)	1497 (3)[30 42 43]	Low[1 6]	Heterogeneous definitions
Manipulative therapy 30d (OR)	0.64 (0.26 to 1.6)	47 085 (3)[30 47 68]	Very low[1–4]	Not upgraded due to substantial downgrades

Summary of findings: Risk factors for cervical artery dissection - Minor trauma.

Patient population: Patients with cervical artery dissection with or without stroke Exposed (Control) populations: General healthy population Outcome: Cervical artery dissection

For GRADE decisions see table 1 footnote.

Jacobs W, *et al. Stroke & Vascular Neurology* 2025;**0**. doi:10.1136/svn-2025-004186 5

147

Risk Factors for CeAD and Related Stroke

Table 4 Summary of findings table: cardiovascular factors

Risk factor	Pooled estimate (95% CI)	Number of participants (Studies)	Certainty of the evidence (GRADE)*	Comments
Common carotid artery diameter (SMD)	0.13 (-0.25 to 0.51)	154 (3)[19 22 36]	Very low[1 2 4]	
Intima-media thickness (SMD)	−0.18 (-0.54 to 0.18)	116 (2)[22 36]	Very low[1 4]	
Relative Vasodilation of the ICA (SMD)	−1.17 (-2.13 to -0.21)	102 (2)[19 22]	Very low[1 2 4]	Not upgraded due to substantial downgrades
Smoking (OR)	1.08 (0.92 to 1.27)	8641 (21)[17 18 22 25–27 29–31 36 42 46 49 50 52 53 56–58 66 70]	Very low[1 2 4]	
Hypertension (OR)	1.58 (1.43 to 1.75)	22379 (23)[17 18 22 23 25–29 31 36 42 46 47 49 50 52 53 56–58 66 70]	Low[1 7]	
Bleeding (OR)	1.08 (0.26 to 4.48)	293 (2)[43 50]	Very low[1–4]	
Hypercholesterolaemia (OR)	1.29 (1.04 to 1.61)	20603 (18)[17 22 23 25 26 29–31 47 49 50 52 53 56–58 66 70]	Very low[1 2]	
Coronary artery disease (OR)	1.81 (1.47 to 2.22)	9328 (2)[47 50]	Very low[1 3]	
Other cardiac diseases (OR)	1.85 (1.65 to 2.08)	13 124 (2)[23 47]	Very low[1–3]	
BMI (SMD)	−0.14 (-0.41 to 0.13)	1201 (5)[17 22 36 50 56]	Very low[1 3 4]	
Obesity (OR)	0.41 (0.31 to 0.56)	4996 (3)[28 29 58]	Very low[1 3]	Not upgraded due to substantial downgrades
Overweight (OR)	0.81 (0.62 to 1.06)	4796 (2)[28 29]	Very low[1–3]	Not upgraded due to substantial downgrades
DM (OR)	1.09 (0.7 to 1.69)	12421 (20)[17 18 22 23 25 26 29–31 42 46 49 50 52 53 56–58 66 70]	Very low[1 2 4]	Not upgraded due to substantial downgrades

Summary of findings: Risk factors for cervical artery dissection: Cardiovascular factors.

Patient population: Patients with cervical artery dissection with or without stroke Exposed (Control) populations: General healthy population Outcome: Cervical artery dissection

For GRADE decisions see table 1 footnote.
BMI, body mass index; DM, Diabetes Mellitus; ICA, internal carotid artery; OR, odds ratio; SMD, standardised mean difference.

148

Risk Factors for CeAD and Related Stroke



Open access Letter

SVN Stroke & Vascular Neurology

Letter to the editor: *risk factors for cervical artery dissection – a systematic review with meta-analysis*

Joshua Piener, L. Rachid Salmi, J. David Cassidy, Carol Cancelliere, Melissa Atkinson-Graham, Iben Axén, Nora Bakas, Marco Campello, Jan Hartvigsen, Cesar Hincapié, Sheilah Hogg-Johnson, Fred Johansson, Silvano Mior, Cecilia K Øverås, Heather Shearer, Eva Skillgate, Manav V Vyas, Pierre Côté

We commend Jacobs *et al* for their article, *Risk factors for cervical artery dissection: a systematic review with meta-analysis*, which addresses this important topic through a comprehensive review. The authors report adherence to guidelines outlined by the Joanna Briggs Institute (JBI) for aetiology, the Preferred Reporting Items for Systematic Reviews and Meta-Analyses (PRISMA) 2020 statement, and Grading of Recommendations, Assessment, Development and Evaluation (GRADE) for observational studies. While the review transparently describes methodological challenges and cautions readers about the low certainty of evidence, in our view, it does not fully adhere to the methodological and reporting standards outlined by these guidelines. Moreover, we highlight key methodological limitations of the review.

JBI GUIDANCE FOR AETIOLOGY

JBI guidance recommends conducting meta-analyses after establishing that studies are clinically and methodologically homogenous. This criterion was not met by Jacobs *et al*. Instead, they pooled studies that investigated unique clinical conditions, including cervical artery dissection (CAD), vertebrobasilar stroke and carotid artery stroke. Although the authors acknowledged the clinical heterogeneity as a limitation, they nevertheless computed and reported pooled estimates that combined heterogeneous populations, exposures and outcomes. As illustrated by their subgroup analyses, several risk factors show markedly different effect estimates depending on the clinical condition. Pooling data across such diverse populations can lead to biased estimates of association between risk factors and CAD. Moreover, the decision to combine results from all ages in the primary meta-analyses is problematic as age is an effect modifier in the relationship between several risk factors and CAD-related stroke.[1 2] For example, Jacobs *et al* demonstrated in their subgroup analyses that effect estimates for obesity, migraine with aura, smoking and manipulative therapy (30-day window) varied substantially by age, underscoring the need for age-stratified analyses.

Second, JBI guidance requires explicit justification for including studies with high risk of bias (ROB) in meta-analyses, as combining studies with selection bias, measurement bias and confounding can lead to erroneous pooled estimates. While the authors reported quality assessments, they did not provide a rationale for including studies with 'very high ROB' or 'high ROB'. Subgroup analyses suggest that such 'high ROB' studies heavily influenced the pooled estimates of association. For example, the pooled OR for migraine without aura in the general population (see Appendix 8 in Jacobs *et al*) was 3.35 (95% CI 1.97 to 6.34). However, among 'very high ROB' studies, the OR of 4.72 (95% CI 2.25 to 9.94) was substantially higher compared with the OR of 1.64 (95% CI 0.98 to 2.75) in studies with 'some concerns', suggesting an overestimation of association in the pooled estimate. Furthermore, the pooled OR for some risk factors is derived solely from studies with high ROB. For example, the association between hypercholesterolaemia and CAD (OR 1.29, 95% CI 1.04 to 1.61) was calculated by 18 studies rated 'very high ROB' and two studies rated 'high ROB'. Including high ROB studies in a systematic review of aetiology is problematic as it undermines the confidence in the validity of the pooled estimates.

Third, as recommended by JBI guidance, Jacobs *et al* registered their *a priori* protocol on PROSPERO (CRD42025486338). In their

Received 23 October 2025
Accepted 29 October 2025

Check for updates

© Author(s) (or their employer(s)) 2025. Re-use permitted under CC BY-NC. No commercial re-use. See rights and permissions. Published by BMJ Group.

For numbered affiliations see end of article.

Correspondence to
Dr Joshua Piener
jpiener@cmcc.ca

BMJ Group

Piener J, *et al*. *Stroke & Vascular Neurology* 2025;0. doi:10.1136/svn-2025-004044 1

Protected by copyright, including for uses related to text and data mining, AI training, and similar technologies. For commercial use, see https://www.bmj.com/company/legal-licensing-agreements/. Published by BMJ Group.

149

Risk Factors for CeAD and Related Stroke



JOURNAL OF MANUAL & MANIPULATIVE THERAPY

Taylor & Francis

OPEN ACCESS

Red flags for extracranial vertebral artery dissections in patients with neck pain: a scoping review

Daniel Feller, Firas Mourad, Filippo Maselli, Graziana Lullo, Claudia Milella, Bart Koes, Alessandro Chiarotto and Annemarie De Zoete

ABSTRACT

Objectives: Neck pain is common and generally benign, but in rare cases it may be the early symptom of vertebral artery dissection (VAD). To date, no published secondary analysis addressing red flags for VADs in patients whose primary complaint is neck pain, nor any describing the typical clinical presentation, demographic characteristics, and common risk factors of VAD, has been published. Therefore, this scoping review addresses that gap by summarizing the current knowledge on red flags, predisposing risk factors, clinical features at presentation, and demographic profiles in patients presenting primarily with neck pain due to extracranial vertebral artery dissection.

Methods: A systematic search was conducted in MEDLINE, Embase, Web of Science, and CINAHL. Primary studies on adults with extracranial VAD and neck pain were included. Two authors independently selected studies and extracted data on clinical predictors.

Results: Forty-six studies (38 case reports, 8 case series) involving 58 patients were included. Most patients (63.8%) were female, with a mean age of 36.8 years. Neck pain was typically unilateral, severe, and poorly responsive to analgesics, often radiating to the head, upper limb, or shoulder; in half of the cases no identifiable cause of onset could be determined, while trauma or sudden neck movements accounted for another third. Risk factors were inconsistently reported, with migraine and hypertension the most frequent. Ischemic symptoms dominated. Neurological symptoms were present in two-thirds of cases, most frequently upper limb weakness and dizziness, while systemic symptoms (mainly nausea and vomiting) occurred in 24.1%. Physical-examination findings were also inconsistently reported: motor deficits, sensory loss, and reflex abnormalities were each documented in roughly 40–47% of cases, and cranial nerve examination was described in only 25.9% of cases and was unremarkable in most of these.

Conclusion: Symptoms and demographic features in extracranial VAD cases with neck pain are highly variable. Due to limited diagnostic accuracy data and inconsistent reporting, the clinical utility of red flags remains uncertain. Until more robust evidence becomes available, clinicians should adhere to expert recommendations for screening for VAD while maintaining a high level of vigilance. Further large-scale observational studies are needed to assess the diagnostic value of red flags in this context.

ARTICLE HISTORY
Received 30 June 2025
Accepted 11 August 2026

KEYWORDS
Neck pain; dissection; screening; differential diagnosis; Risk Factors; Headache; warning signs

Introduction

Neck pain is a highly prevalent and disabling condition [1]. While the majority of cases have a benign origin, neck pain may be an early manifestation of a serious condition, such as vertebral artery dissection (VAD) [2]. The estimated annual incidence of VADs is approximately 1 case per 100,000 individuals [3]. VADs arise from a tear in the inner layers of the artery's wall, leading to a cascade of events which create a pseudoaneurysm occluding the lumen, or which trigger the clotting of an embolus which may propagate to the brain, causing an ischemic stroke [4–7]. VAD might not be detected in the early stages, particularly in the absence of clear ischemic features, leading to potential catastrophic consequences for the patient, including strokes in the posterior circulation [4–6]. The etiology of VAD is multifactorial, with both spontaneous and traumatic onset being reported, particularly for individuals under 45 years of age [6]. While some cases have been observed to have an association with identifiable risk factors, such as connective tissue disorders, hypertension, or recent cervical trauma, many others occur

CONTACT Daniel Feller, DanielFeller.fb@gmail.com, Department of General Practice, Erasmus MC, University Medical Centre, Dr. Molewaterplein 40, Rotterdam 3015 GD, The Netherlands

Supplemental data for this article can be accessed online at https://doi.org/10.1080/10669817.2026.2728218

© 2026 The Author(s). Published by Informa UK Limited, trading as Taylor & Francis Group.
This is an Open Access article distributed under the terms of the Creative Commons Attribution License (http://creativecommons.org/licenses/by/4.0/), which permits unrestricted use, distribution, and reproduction in any medium, provided the original work is properly cited. The terms on which this article has been published allow the posting of the Accepted Manuscript in a repository by the author(s) or with their consent.

- It is recommended to adopt sound clinical reasoning that considers the warning features in the context of the whole patient's presentation [8,9,38].
- Identifying atypical pain characteristics, risk factors, or preceding neurological signs and symptoms should serve as clinical prediction guides when used in combination with a thorough patient history and an appropriate physical examination to make the best judgment on the probability of serious pathology that is present [8,9].
- Additionally, close surveillance of these features' progress over time may be useful, particularly in physiotherapy and general practitioner settings, since patients are seen more frequently [39].
- In situations of diagnostic uncertainty, taking a cautious approach and considering a referral to a specialist may be the safest way to mitigate potential risks [38].

150

Risk Factors for CeAD and Related Stroke

Part A: Risk factors for CeAD occurrence

Table 1. Genetic and familial factors

Factor	Finding	Certainty (GRADE)	Source	Status
Migraine	Pooled OR 2.34 (1.58–3.48); 5 studies, n=2,218. No difference with or without aura.	Moderate	J	Verified
MTHFR C677T TT homozygosity	Pooled OR 2.94 (1.8–4.78); 3 studies, n=533.	Moderate	J	Verified
Connective tissue disorders (combined)	Pooled OR 2.21 (1.06–4.59); 3 studies, n=485.	Very low	J	Verified
Vascular Ehlers-Danlos (COL3A1)	Two cases among 1,934 consecutive CeAD patients; inherited connective tissue disorders appeared exceptional.	n/a	D3	Verified
FMD, Marfan, EDS	Not assessable against healthy controls in Jacobs (all studies used stroke or hospital controls). FMD strongly over-represented in multiple dissections (OR 3.97).	Not assessable	J, Be	Verified
TGFBR2, FBN1, other genes	TGFBR2 positive in 2 of 3 studies; FBN1 OR 13.15 (1.66–104) in one study; too sparse to pool.	Very low	J	Verified
Serum MMP level	SMD 2.0 (0.74–3.27); 2 studies. MMP polymorphisms not associated.	Very low	J	Verified
Family history of CeAD	About 1% of patients.	n/a	D3	Verified
PHACTR1 variant	GWAS in 1,393 cases and 14,416 controls found an association.	n/a	D4	Verified

151

Risk Factors for CeAD and Related Stroke

Table 2. External factors and triggers

Factor	Finding	Certainty (GRADE)	Source	Status
Recent infection	Pooled OR 2.03 (1.33–3.09); 5 studies. Risk declined from 30 to 365 days after respiratory infection.	Very low	J	Verified
White blood cell count	SMD 1.46 (0.99–1.93); 2 studies.	Very low	J	Verified
Winter / autumn–winter season	Pooled OR 1.37 (1.04–1.82); 2 studies.	Very low	J	Verified
Oral contraceptive use	Pooled OR 1.81 (1.07–3.06); 4 studies. Authors describe the data as inconsistent (one significant study, three non-significant). Also listed in the AHA/ASA 2014 statement.	Very low	J, Bi	Verified / Secondary
Alcohol use	OR 0.94 (0.82–1.09); no association.	Very low	J	Verified
Pregnancy	Single study; no pooled estimate.	n/a	J	Verified

152

Risk Factors for CeAD and Related Stroke

Table 3. Minor trauma and cervical manipulation

Factor	Finding	Certainty (GRADE)	Source	Status
Minor trauma	Pooled OR 4.33 (1.96–9.56); 3 studies, n=1,497; heterogeneous definitions.	Low	J	Verified
Cervical manipulation (cSMT), 30 days	Pooled OR 0.64 (0.26–1.6); 3 studies. Individual studies conflict: Engelter OR 3.6 (1.23–10.7) vs healthy controls; Cassidy and Kosloff found no excess over primary-care visits.	Very low	J, C	Verified
cSMT: AHA/ASA interpretation	Statistical association; causation not shown. Reverse causation possible because early dissection pain may prompt a visit. Association largely confined to patients under 45 and to vertebral dissection.	n/a	Bi	Secondary (verify)
Manipulation in multiple CeAD	OR 2.23 (1.26–3.95).	n/a	Be	Verified
Remote head or neck surgery	OR 1.87 (1.16–3.00) for multiple CeAD.	n/a	Be	Verified

153

Risk Factors for CeAD and Related Stroke

Table 4. Cardiovascular and metabolic factors

Factor	Finding	Certainty (GRADE)	Source	Status
Hypertension	Pooled OR 1.58 (1.43–1.75); 23 studies, n=22,379.	Low	J	Verified
Hypercholesterolemia	Pooled OR 1.29 (1.04–1.61); 18 studies. Earlier CADISP-type data found the opposite direction.	Very low	J, D4	Verified
Coronary artery disease; other cardiac disease	OR 1.81 (1.47–2.22) and OR 1.85 (1.65–2.08); 2 studies each.	Very low	J	Verified
Obesity	OR 0.41 (0.31–0.56); 3 studies. Overweight and BMI not significant.	Very low	J	Verified
Smoking; diabetes	OR 1.08 (0.92–1.27); OR 1.09 (0.7–1.69). Both non-significant.	Very low	J	Verified
Hyperhomocysteinemia	Elevated in 3 studies.	Very low	J	Verified

154

Risk Factors for CeAD and Related Stroke

Table 5. Arterial and anatomic features

Factor	Finding	Certainty (GRADE)	Source	Status
Relative ICA vasodilation	SMD −1.17 (−2.13 to −0.21); 2 studies.	Very low	J	Verified
Carotid IMT; common carotid diameter	Not significant.	Very low	J	Verified
Elongated styloid process (>30 mm); vascular tortuosity	Named as predisposing anatomy.	n/a	Y	Verified

155

Risk Factors for CeAD and Related Stroke

Part B: Risk factors for ischemic stroke and recurrence once CeAD is present

Table 6. Imaging markers

Factor / item	Finding	Source	Status
Cervical artery occlusion	RR 1.59 (1.17–2.17) for recurrence; OR 9.5 for early recurrence.	B1, B2	Secondary (verify)
Intraluminal thrombus	OR 17.5 (3.0–101.7) for early recurrence; independently associated with stroke on MRI.	B2, B3, B4	Secondary (verify)
Stenosis ≥70%	No early recurrence without ischemic presentation or with <70% stenosis; moderate-to-severe stenosis linked to stroke (OR 3.4).	B2, B3	Secondary (verify)
Irregular surface (MRI)	OR 4.29 (1.61–11.46).	B4	Secondary (verify)
Double lumen	IRR 2.83 for recurrence at days 4–7.	B5	Secondary (verify)
Intracranial extension / embolism / large-vessel occlusion	OR 6.8 (early recurrence); RR 2.75; RR 1.44.	B1, B2	Secondary (verify)
Poor circle of Willis	OR 8.5 (2.0–35.4); RR 1.96.	B1, B2	Secondary (verify)
Dissection location	Not significant after adjusting for morphology.	B5	Secondary (verify)

156

Risk Factors for CeAD and Related Stroke

Table 7. Patient factors, timing and burden

Factor / item	Finding	Source	Status
Prior ischemic stroke	RR 1.77; predictor in STOP-CAD.	B1, B6	Secondary (verify)
Coronary artery disease	RR 1.63 for recurrent ischemic events.	B1	Secondary (verify)
Early ischemic recurrence	About 9% (95% CI 5–13%) within 2 weeks; median 1.5 days after diagnosis.	B2	Secondary (verify)
Subsequent stroke by day 180	5.3% in STOP-CAD.	B6	Secondary (verify)
Recurrent dissection	About 1–2% per year; FMD and younger age raise risk.	Y (summary)	Secondary (verify)
Share of ischemic stroke	About 2% overall; up to 25% under age 50.	Y	Verified
Stroke within 4 weeks of CeAD	Range 0–13.5%, setting-dependent.	J	Verified
CeAD with stroke, incidence	About 2.97 per 100,000 person-years.	J (citing Béjot 2014, Int J Stroke)	Verified

157

Risk Factors for CeAD and Related Stroke

References

Code	Citation
J	Jacobs W, Wright DS, Pohlman K, et al. Risk factors for cervical artery dissection: a systematic review with meta-analysis. Stroke Vasc Neurol. 2025. doi:10.1136/svn-2025-004186. [Verified from uploaded PDF]
Y	Yaghi S, Engelter S, Del Brutto VJ, et al. Treatment and outcomes of cervical artery dissection in adults: a scientific statement from the American Heart Association. Stroke. 2024;55(3):e91–e106. doi:10.1161/STR.0000000000000457. [Verified]
Bi	Biller J, Sacco RL, Albuquerque FC, et al. Cervical arterial dissections and association with cervical manipulative therapy: a statement for healthcare professionals from the AHA/ASA. Stroke. 2014 (October issue). [Volume and pages unverified; content from a slide-deck summary]
D3	Debette S, Goeggel Simonetti B, Schilling S, et al. Familial occurrence and heritable connective tissue disorders in cervical artery dissection. Neurology. 2014;83(22):2023–2031. doi:10.1212/WNL.0000000000001027. [Verified]
D4	Debette S, Kamatani Y, Metso TM, et al. Common variation in PHACTR1 is associated with susceptibility to cervical artery dissection. Nat Genet. 2015;47(1):78–83. [Verified]
Be	Béjot Y, Aboa-Aboulé C, Debette S, et al. Characteristics and outcomes of patients with multiple cervical artery dissection. Stroke. 2014;45:37–41. [Verified]
C	Cassidy JD, Boyle E, Côté P, et al. Risk of vertebrobasilar stroke and chiropractic care: results of a population-based case-control and case-crossover study. Spine. 2008;33(4 Suppl):S176–S183. PMID 18204390. [Verified]
DL	Debette S, Leys D. Cervical-artery dissections: predisposing factors, diagnosis, and outcome. Lancet Neurol. 2009;8:668–678. [Verified]
B1	Systematic review of prognostic factors for recurrent ischemic events after CeAD. Authors and journal not captured; retrieved via aggregator. [Secondary]
B2	Early ischemic recurrence in acute spontaneous cervical artery dissection (2023). Authors and journal not confirmed. [Secondary]
B3	Liu J, Ouyang F, Liu Y, et al. HR-MRI identification and scoring of factors for CAD-related ischemic stroke. Quant Imaging Med Surg. Year not confirmed. [Secondary]
B4	Wu Y, Wu F, Yang Q. High-resolution MRI of cervicocranial artery dissection: imaging features associated with stroke (PMC6817420). Journal not confirmed. [Secondary]
B5	Jang et al. Recurrent ischemic stroke after craniocervical artery dissection, nationwide cohort. Aggregator page only. [Secondary]
B6	STOP-CAD secondary analysis of predictors of subsequent ischemic stroke. Retrieved as a medRxiv preprint and a literature-watch summary. [Secondary]

158

Risk Factors for CeAD and Related Stroke

Demetrious *Chiropractic & Manual Therapies* (2018) 26:22
https://doi.org/10.1186/s12998-018-0193-z

Chiropractic & Manual Therapies

HYPOTHESIS Open Access

Spontaneous cervical artery dissection: a fluoroquinolone induced connective tissue disorder?

James S. Demetrious

Abstract

Background: Spontaneous cervical artery dissections more often manifest in young people and have been associated with catastrophic consequences. Some indeterminate risk factors have been identified, making the diagnosis of developing dissections quite difficult. Fluoroquinolone antibiotics have been recognized for their degradative effects on connective tissue. Recent studies have implicated fluoroquinolones in the genesis of aortic artery aneurysms. It is the purpose of this paper to provide reasoning for a testable hypothesis of whether fluoroquinolones constitute a risk factor associated with cervical artery dissections.

Methods: A PubMed search was conducted to investigate whether cervical artery dissection has been associated with fluoroquinolone use. An assessment of risk factors was made of hereditary connective tissue disorders, infection, and seasonal predisposition related to cervical artery dissection. These factors were considered in conjunction with reports of connective tissue toxicity associated with fluoroquinolone medications.

Results: It appears that no reported cases of cervical artery dissection have previously been correlated with fluoroquinolone use. Heritable connective tissue disorders, infection, seasonal predisposition and condition latencies are associated with fluoroquinolone medications. Several recent articles have implicated fluoroquinolones with aortic dissections and aneurysm.

Conclusion: A causal relationship of fluoroquinolone antibiotics to cervical artery dissection is plausible. The suppositions developed in this paper are insufficient to suggest that fluoroquinolones currently represent an established risk factor in the development of cervical artery dissections. Fluoroquinolones may indeed be a novel and previously unrecognized cause of cervical artery dissections.

Keywords: Cervical artery dissection, Fluoroquinolone, Carotid, Vertebral, Stroke, Infarct, Connective tissue, Collagen, Aneurysm

Conclusion

A causal relationship of fluoroquinolone antibiotics to cervical artery dissection is plausible. Fluoroquinolones may indeed be a novel and previously unrecognized cause of cervical artery dissections. This hypothesis is insufficient to conclude that fluoroquinolones represent a current and established risk factor for the development of cervical artery dissections. An initial call for case reports and formal investigation is warranted. An extensive longitudinally observed population study might shed light upon this subject.

159

Risk Factors for CeAD and Related Stroke

Trager et al. Chiropractic & Manual Therapies https://doi.org/10.1186/s12998-026-00678-4 (2026) 34:53

Chiropractic & Manual Therapies

RESEARCH Open Access

Association between spinal manipulative therapy and cervical artery dissection in patients with neck pain or headache: a retrospective cohort study

Robert J. Trager[1,2*], Anthony N. Baumann[4,5], Collin M. Labak[6], Kelsey L. Lewis[1], Jaime Abraham Perez[7], Christine M. Goertz[8,9] and Andres Schuster[10]

Abstract

Objectives Cervical artery dissection (CeAD) has been proposed as a sequela of spinal manipulative therapy (SMT), however, protopathic bias arising from care-seeking for CeAD symptoms (e.g., neck pain/headache) may overestimate observed associations. Among adults experiencing new neck pain/headache, we tested the null hypothesis of no significant CeAD risk within 30 days following SMT compared to matched ibuprofen-prescribed controls.

Methods We searched United States TriNetX Linked health records/claims data (2010–2025) for adults seeking care for new episodes of neck pain/headache receiving (1) chiropractor-administered cervical SMT or (2) outpatient visit with ibuprofen prescription, excluding those with previous cerebrovascular disease and/or CeAD, using propensity matching to minimize confounding. We examined the risk ratio (RR) of CeAD (primary outcome), exploring cumulative incidence, CeAD subtypes, absolute risk difference (RD), and negative control outcomes.

Results After matching, there were 431,492 patients per cohort. In the SMT cohort, compared with the ibuprofen cohort, CeAD risk was lower while RD was minimal [95% CI] (RR = 0.53 [0.35, 0.83]; RD = −6.3 [−10.8, −2.0] events per 100,000 patients; $P = 0.004$). Carotid artery dissection risk was lower; vertebral artery dissection risk was not significantly different. Data quality supported balanced confounders and minimal follow-up loss (< 3%). Negative control outcomes were partially balanced.

Conclusions This study found no evidence of an increased risk of CeAD after chiropractor-administered cervical SMT compared with ibuprofen prescription in adults seeking care for new episodes of neck pain or headache. Despite the rarity of these events, all clinicians, including chiropractors, should maintain vigilance for CeAD symptoms. Additional multidisciplinary research is warranted to further address potential confounding and examine patient subgroups (e.g., migraine) and stroke.

Keywords Chiropractic, Spinal manipulation, Adverse outcome pathways, Safety, Vertebral artery dissection

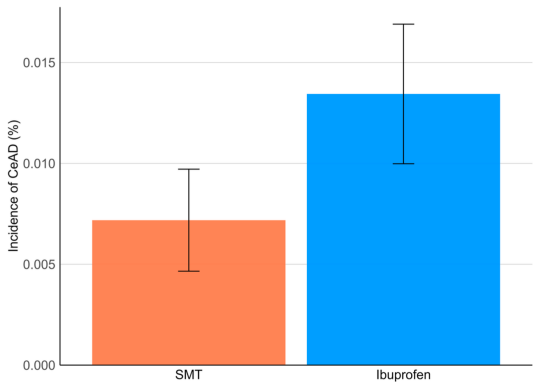

Fig. 1 Total incidences of cervical artery dissection (CeAD) per cohort. The spinal manipulative therapy (SMT) cohort is represented in orange while the ibuprofen cohort is represented in blue. The error bars indicate 95% confidence intervals. Data represent findings after matching, over the 30-day follow-up window

160

Risk Factors for CeAD and Related Stroke

Trager et al. Chiropractic & Manual Therapies (2026) 34:53
https://doi.org/10.1186/s12998-026-00678-4

Chiropractic & Manual Therapies

RESEARCH Open Access

Association between spinal manipulative therapy and cervical artery dissection in patients with neck pain or headache: a retrospective cohort study

Robert J. Trager[1,2,3*], Anthony N. Baumann[4,5], Collin M. Labak[6], Kelsey L. Lewis[1], Jaime Abraham Perez[7], Christine M. Goertz[8,9] and Andres Schuster[1,9]

Abstract

Objectives Cervical artery dissection (CeAD) has been proposed as a sequela of spinal manipulative therapy (SMT), however, protopathic bias arising from care-seeking for CeAD symptoms (e.g., neck pain/headache) may overestimate observed associations. Among adults experiencing new neck pain/headache, we tested the null hypothesis of no significant CeAD risk within 30 days following SMT compared to matched ibuprofen-prescribed controls.

Methods We searched United States TriNetX Linked health records/claims data (2010–2025) for adults seeking care for new episodes of neck pain/headache receiving (1) chiropractor-administered cervical SMT or (2) outpatient visit with ibuprofen prescription, excluding those with previous cerebrovascular disease and/or CeAD, using propensity matching to minimize confounding. We examined the risk ratio (RR) of CeAD (primary outcome), exploring cumulative incidence, CeAD subtypes, absolute risk difference (RD), and negative control outcomes.

Results After matching, there were 431,492 patients per cohort. In the SMT cohort, compared with the ibuprofen cohort, CeAD risk was lower while RD was minimal [95% CI] (RR=0.53 [0.35, 0.83]; RD=-6.3 [-10.8, -2.0] events per 100,000 patients; $P = 0.004$). Carotid artery dissection risk was lower; vertebral artery dissection risk was not significantly different. Data quality supported balanced confounders and minimal follow-up loss (< 3%). Negative control outcomes were partially balanced.

Conclusions This study found no evidence of an increased risk of CeAD after chiropractor-administered cervical SMT compared with ibuprofen prescription in adults seeking care for new episodes of neck pain or headache. Despite the rarity of these events, all clinicians, including chiropractors, should maintain vigilance for CeAD symptoms. Additional multidisciplinary research is warranted to further address potential confounding and examine patient subgroups (e.g., migraine) and stroke.

Keywords Chiropractic, Spinal manipulation, Adverse outcome pathways, Safety, Vertebral artery dissection

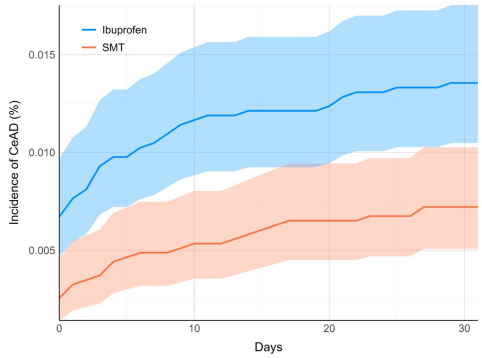

Fig. 2 Cumulative incidences of cervical artery dissection (CeAD). The spinal manipulative therapy (SMT) cohort is represented in orange while the ibuprofen cohort is represented in blue. Shaded regions highlight 95% confidence intervals (CI). Data represent findings after matching, over the 30-day follow-up window. Both cohorts show similar curvilinear patterns with some events occurring on the index date (day 0), and maintain relatively consistent separation throughout follow-up with some overlap in 95% CI

161

Risk Factors for CeAD and Related Stroke

Health Science Reports WILEY
Health Science Reports

ORIGINAL RESEARCH OPEN ACCESS

Association Between Autoimmune Thyroiditis and Cervical Artery Dissection: A Retrospective Cohort Study

Robert J. Trager[1,2,3] | Pratheek S. Makineni[4] | Debbie S. Wright[1,2]

[1]Cenace Whole Health, University Hospitals Cleveland Medical Center, Cleveland, Ohio, USA | [2]Department of Family Medicine and Community Health, Case Western Reserve University School of Medicine, Cleveland, Ohio, USA | [3]Department of Biostatistics and Bioinformatics Clinical Research Training Program, Duke University School of Medicine, Durham, North Carolina, USA | [4]Case Western Reserve University School of Medicine, Cleveland, Ohio, USA | [5]Parker University, Dallas, Texas, USA | [6]Private practice, The Grove Health and Wellness, Courtenay, British Columbia, Canada

Correspondence: Robert J. Trager (Robert.Trager@case.edu)

Received: 21 January 2025 | **Revised:** 19 January 2026 | **Accepted:** 13 March 2026

Funding: Clinical and Translational Science Collaborative of Northern Ohio, National Institutes of Health, National Center for Advancing Translational Sciences; Clinical and Translational Science, Grant/Award Number: UM1TR004639; Elizabeth Severance Prentiss Foundation (Cleveland, OH)

Keywords: autoimmune diseases | cardiovascular diseases | cerebrovascular disorders | internal carotid artery dissection | thyroid diseases | vertebral artery dissection

ABSTRACT

Background and Aims: Limited evidence suggests autoimmune thyroiditis (AT) could represent a risk factor for cervical artery dissection (CeAD). We tested the hypothesis of a positive association between AT and CeAD within 3 years following diagnosis compared to matched euthyroid controls.

Methods: We searched a de-identified United States' data resource (TriNetX LLC) for adults age ≥ 18 with newly-diagnosed AT, and euthyroid controls, from 2014 to 2024. Propensity matching controlled for variables associated with CeAD. Our primary outcome was the risk ratio (RR) for CeAD within 3 years' follow-up. Secondary outcomes explored the cumulative incidence of CeAD and RRs for vertebral and carotid artery dissection and stroke.

Results: After matching, there were 143,831 patients per cohort (80% female). Comparing the AT cohort to matched euthyroid controls, the incidence and risk of CeAD was significantly greater [95% CI] (0.04691 vs. 0.0235; RR = 1.58 [1.04, 2.40]; $p = 0.029$). Secondary outcomes included a non-significant increase in incidence and risk of vertebral artery dissection (0.0225 vs. 0.0179;; RR = 1.28 [0.76, 2.16]; $p = 0.354$), and significant increase in incidence and risk of carotid artery dissection (0.0195 vs. 0.0091; RR = 2.33 [1.19, 4.59]; $p = 0.011$) and stroke (2.15 vs. 1.35; RR = 1.67 [1.36, 1.77]; $p < 0.001$). Cumulative incidence of CeAD in patients with AT highlighted a time-dependent increase relative to euthyroid controls.

Conclusion: The present findings suggest that AT is a risk factor for CeAD. Additional research is needed to corroborate these findings and clarify factors that may mediate the AT-CeAD association, such as medications, thyroid hormones, and antibody levels.

1 | Introduction

Cervical artery dissection (CeAD) is a serious condition characterized by a tear in the wall of a cervical artery, leading to an intramural hematoma and potentially causing a stroke [1]. The incidence of CeAD is approximately 8.9 per 100,000 person-years [2]. Autoimmune thyroiditis (AT), also called Hashimoto's thyroiditis, represents the most common cause of hypothyroidism in regions with adequate iodine intake, such as the United States (US) [3, 4]. AT is an established risk factor for stroke [5] and is associated with increased risk of several cardiovascular diseases [6–9], including aortic dissection and spontaneous coronary

This is an open access article under the terms of the Creative Commons Attribution License, which permits use, distribution and reproduction in any medium, provided the original work is properly cited.
© 2026 The Author(s). *Health Science Reports* published by Wiley Periodicals LLC.

162

CeAD Diagnostic Delay



OPEN

Systemic lupus erythematosus is associated with an increased risk of cervical artery dissection

Robert J. Trager, Benjamin P. Lynn, Anthony N. Baumann & Eric Chun-Pu Chu

Limited evidence suggests that autoimmune diseases are associated with an increased risk of cervical artery dissection (CeAD). We hypothesized individuals with systemic lupus erythematosus (SLE) would have an increased risk of CeAD following SLE diagnosis compared to matched non-lupus controls. We queried a de-identified United States electronic medical records network (TriNetX, Inc.) for individuals aged 10 and older from 2012 to 2020, for two cohorts: (1) SLE and (2) non-lupus controls, excluding those with prior CeAD. We used propensity matching to control for confounding variables and calculated the risk ratio (RR) for CeAD occurring over four years' follow-up, secondarily exploring cumulative incidence. After matching, both cohorts contained 77,008 patients, who were mostly female (89%). The incidence and risk of CeAD was significantly greater among those with SLE compared to matched non-lupus controls (95% CI) (0.08% vs. 0.04%; RR = 2.33 [1.49;3.66]; $P < 0.001$). These findings support the hypothesis that SLE is a risk factor for CeAD. Additional research is needed to identify the mechanisms that may underly the SLE-CeAD association and examine the potential association between other autoimmune diseases and CeAD.

Systemic lupus erythematosus (SLE) is a chronic, multisystem autoimmune disorder involving the production of autoantibodies which lead to inflammation and tissue damage[1]. Limited research has suggested that autoimmune diseases, such as SLE, may be a risk factor for spontaneous cervical artery dissection (CeAD)[2–4], a condition involving a tear and hematoma within the wall of the vertebral or carotid artery[5]. The incidence of SLE increases during adolescence, reaching up to 10 per 100,000 person-years in adults[6]. CeAD has an incidence of 8.9 per 100,000 person-years and accounts for 15–25% of strokes in adults under age 50[7].

Specific etiologies of CeAD are recognized including trauma[8] and iatrogenic causes such as spine surgery[9]. Several risk factors for CeAD have also been identified, albeit with varying degrees of certainty. Better-established risk factors include fibromuscular dysplasia and other genetic conditions affecting collagen[8,10], hypertension[11,12], migraine without aura[13], pregnancy[14,15], and respiratory infections[16–18] (apart from coronavirus disease 2019[19]). Others potential risk factors like diabetes mellitus[11,12], autoimmune thyroiditis[3,4], hyperlipidemia[11,12], fluoroquinolones[20], oral contraceptives[10,21,22], alcohol intake[11,23,24], and tobacco use[25] have conflicting or only preliminary evidence to date. Additionally, socioeconomic factors may influence whether patients undergo testing to identify CeAD[26,27], highlighting the need for carefully designed studies to examine these risk factors.

Case-control studies have also revealed heightened inflammatory markers in individuals with CeAD compared to non-CeAD controls. Notably, elevations in C-reactive protein, erythrocyte sedimentation rate, and white blood cell counts have been observed[28–31]. While these findings suggest a potential underlying inflammatory mechanism for CeAD, the mediating factors remain unclear. Accordingly, some researchers have suggested that autoimmune disease may play a role, given these conditions can induce inflammation[32]. For example, one case-control study involving 215 CeAD cases found that 12.6% of individuals with CeAD had an autoimmune disease, compared to only 0.9% of age- and sex-matched population controls[3]. Therefore, while a direct link between specific autoimmune diseases and CeAD is yet to be confirmed, prior research indicates that further investigation into this relationship is warranted.

[1]Connor Whole Health, University Hospitals Cleveland Medical Center, 11100 Euclid Ave, Cleveland 44106, OH, USA. [2]Department of Family Medicine and Community Health, Case Western Reserve University School of Medicine, Cleveland, OH, USA. [3]Department of Biostatistics and Bioinformatics Clinical Research Training Program, Duke University School of Medicine, Durham, NC, USA. [4]Los Gatos Sports Clinic, Los Gatos, CA, USA. [5]College of Medicine, Northeast Ohio Medical University, Rootstown, OH, USA. [6]Department of Rehabilitation Services, University Hospitals, Cleveland, OH, USA. [7]New York Medical Group, EC Healthcare, Kowloon, Hong Kong. ✉email: Robert.Trager@UHhospitals.org

Scientific Reports | (2025) 15:1555 | https://doi.org/10.1038/s41598-025-85655-2 nature portfolio

Content courtesy of Springer Nature, terms of use apply. Rights reserved

- Currently, CeAD diagnosis presents a challenge due to its benign-appearing early symptoms, reflected by a mean time-to-diagnosis of 9 days (SD=12)53.

163

Risk Factors for CeAD and Related Stroke



Systematic Review and Meta-Analysis

Medicine

OPEN

Cervical arteries tortuosity and its association with dissection

A systematic review and meta-analysis

Anas Bitar, MD*, Dana Almahder, MD, Jaafer A. Jouini, MD, Bayan Alsaid, MD, PhD

Abstract

Background: This study investigated the link between arterial tortuosity and cervical artery dissection, focusing on carotid and vertebral tortuosity indices, as well as carotid tortuosity classifications (kinking, looping, and coiling).

Methods: We searched PubMed, SCOPUS, Web of Science, and Google Scholar from database inception to January 2024. The inclusion criteria encompassed human studies on tortuosity and cervical, carotid, or vertebral artery dissection. Exclusion criteria included case reports, non-English studies, and studies solely on connective tissue disorders and diseases. Quality and risk of bias were assessed using the Newcastle-Ottawa Scale. Random-effects model was employed for mean differences and odds ratios. When meta-analysis was not feasible, we summarized and integrated the results narratively.

Results: Seven studies, involving 507 dissected patients and 582 non-dissected patients, were included. In a meta-analysis of 3 studies, vertebral tortuosity favored the dissection cases [MD = 3.58, 95% CI: 2.21–4.95]. The mean carotid tortuosity difference was not statistically significant in a meta-analysis of 2 studies [MD = 2.27, 95% CI: −0.16–4.70]. In the classification analysis, 2 studies indicated no conclusive association between kinking, coiling, and cervical arteries dissection. Regarding carotid classification and internal carotid artery dissection, meta-analyses only showed a significant association with kinking, but the result was inconclusive.

Conclusion: Tortuosity index screenings may help prevent cervical artery dissection among at-risk individuals. However, the association with specific tortuosity classifications remains inconclusive, and further research is needed to validate these findings. Standardized measurement criteria are crucial for future studies.

Abbreviations: CCTI = common carotid tortuosity index, CeAD = cervical artery dissection, CTI = carotid tortuosity index, ICA = internal carotid artery, ICAD = internal carotid artery dissection, ICTI = internal carotid tortuosity index, NOS = Newcastle-Ottawa scale, VTI = vertebral tortuosity index.

Keywords: arterial tortuosity, carotid artery, cervical artery, dissection, vertebral artery

1. Introduction

The cervical arteries consist of 3 layers, with the innermost layer being the tunica intima. It forms the vessel lining and is delicate, making it prone to tearing and initiating arterial dissections.[1,2] Dissections can occur spontaneously or as a consequence of trauma.[3] Cervical artery dissection (CeAD) frequently leads to stroke or transient ischemia in young adults, although some individuals may experience milder symptoms.[4] While this condition is relatively rare,[5] It stands as the most common cause of ischemic strokes in young and otherwise healthy individuals.[6,7]

The etiological factors contributing to this condition remain a subject of ongoing investigation, with hypotheses suggesting potential links to established vascular risk factors such as hypertension, diabetes mellitus, and smoking, as well as associations with connective tissue disorders like Marfan syndrome, cervical traumas, and infections.[8,9]

Arterial tortuosity, a vascular system morphological characteristic indicating deviation from a straight line, has been postulated as a potential manifestation of an underlying connective tissue abnormality that could weaken vessel walls and increase the risk of arterial dissection.[10,11] It may be influenced by embryological development,[12] and it has been detected in genetic disorders related to aortic conditions, involving factors in the TGF-β signaling pathway, matrix proteins, vascular smooth muscle relaxation, and copper

The authors have no funding and conflicts of interest to disclose.

All data generated or analyzed during this study are included in this published article [and its supplementary information files].

The protocol was registered in the PROSPERO database (CRD-42024502689).

* Faculty of Medicine, Damascus University, Damascus, Syria. Laboratory of Anatomy, Faculty of Medicine, Damascus University, Damascus, Syria.

* Correspondence: Anas Bitar, Faculty of Medicine, Damascus University, Damascus, Syria (e-mail: anasbitr@gmail.com).

Copyright © 2025 the Author(s). Published by Wolters Kluwer Health, Inc. This is an open-access article distributed under the terms of the Creative Commons Attribution-Non Commercial License 4.0 (CCBY-NC), where it is permissible to download, share, remix, transform, and buildup the work provided it is properly cited. The work cannot be used commercially without permission from the journal.

How to cite this article: Bitar A, Almahder D, A Jouini J, Alsaid B. Cervical arteries tortuosity and its association with dissection: A systematic review and meta-analysis. Medicine 2025;104:7(e41517).

Received: 28 August 2024 / Received in final form: 4 December 2024 / Accepted: 24 January 2025

http://dx.doi.org/10.1097/MD.0000000000041517

164

Risk Factors for CeAD and Related Stroke

OPEN

Systemic lupus erythematosus is associated with an increased risk of cervical artery dissection

Robert J. Trager, Benjamin P. Lynn, Anthony N. Baumann & Eric Chun-Pu Chu

Limited evidence suggests that autoimmune diseases are associated with an increased risk of cervical artery dissection (CeAD). We hypothesized individuals with systemic lupus erythematosus (SLE) would have an increased risk of CeAD following SLE diagnosis compared to matched non-lupus controls. We queried a de-identified United States electronic medical records network (TriNetX, Inc.) for individuals aged 10 and older from 2012 to 2020, for two cohorts: (1) SLE and (2) non-lupus controls, excluding those with prior CeAD. We used propensity matching to control for confounding variables and calculated the risk ratio (RR) for CeAD occurring over four years' follow-up, secondarily exploring cumulative incidence. After matching, both cohorts contained 77,008 patients, who were mostly female (89%). The incidence and risk of CeAD was significantly greater among those with SLE compared to matched non-lupus controls (95% CI) (0.08% vs. 0.04%; RR = 2.33 (1.49,3.66); $P < 0.0001$). These findings support the hypothesis that SLE is a risk factor for CeAD. Additional research is needed to identify the mechanisms that may underly the SLE-CeAD association and examine the potential association between other autoimmune diseases and CeAD.

Systemic lupus erythematosus (SLE) is a chronic, multisystem autoimmune disorder involving the production of autoantibodies which lead to inflammation and tissue damage[1]. Limited research has suggested that autoimmune diseases, such as SLE, may be a risk factor for spontaneous cervical artery dissection (CeAD)[2–5], a condition involving a tear and hematoma within the wall of the vertebral or carotid artery[6]. The incidence of SLE increases during adolescence, reaching up to 10 per 100,000 person-years in adults[7]. CeAD has an incidence of 8.9 per 100,000 person-years and accounts for 15–25% of strokes in adults under age 50[8].

Specific etiologies of CeAD are recognized including trauma[9] and iatrogenic causes such as spine surgery[10]. Several risk factors for CeAD have also been identified, albeit with varying degrees of certainty. Better-established risk factors include fibromuscular dysplasia and other genetic conditions affecting collagen[8,11], hypertension[12,13], migraine without aura[14], pregnancy[15,16], and respiratory infections[17,18] (apart from coronavirus disease 2019[19]). Others potential risk factors like diabetes mellitus[13,17], autoimmune thyroiditis[13], hyperlipidemia[12,13], fluoroquinolones[20], oral contraceptives[16,21,22], alcohol intake[12,23,24], and tobacco use[12] have conflicting or only preliminary evidence to date. Additionally, socioeconomic factors may influence whether patients undergo testing to identify CeAD[25–27], highlighting the need for carefully designed studies to examine these risk factors.

Case-control studies have also revealed heightened inflammatory markers in individuals with CeAD compared to non-CeAD controls. Notably, elevations in C-reactive protein, erythrocyte sedimentation rate, and white blood cell counts have been observed[28,29]. While these findings suggest a potential underlying inflammatory mechanism for CeAD, the mediating factors remain unclear. Accordingly, some researchers have suggested that autoimmune disease may play a role, given these conditions can induce inflammation[30]. For example, one case-control study involving 215 CeAD cases found that 12.6% of individuals with CeAD had an autoimmune disease, compared to only 0.9% of age- and sex-matched population controls[6]. Therefore, while a direct link between specific autoimmune diseases and CeAD is yet to be confirmed, prior research indicates that further investigation into this relationship is warranted.

[1]Connor Whole Health, University Hospitals Cleveland Medical Center, 11100 Euclid Ave, Cleveland 44106, OH, USA. [2]Department of Family Medicine and Community Health, Case Western Reserve University School of Medicine, Cleveland, OH, USA. [3]Department of Biostatistics and Bioinformatics Clinical Research Training Program, Duke University School of Medicine, Durham, NC, USA. [4]Los Gatos Sports Chiro, Los Gatos, CA, USA. [5]College of Medicine, Northeast Ohio Medical University, Rootstown, OH, USA. [6]Department of Rehabilitation Services, University Hospitals, Cleveland, OH, USA. [7]New York Medical Group, EC Healthcare, Kowloon, Hong Kong. ✉email: Robert.Trager@UHhospitals.org

Content courtesy of Springer Nature, terms of use apply. Rights reserved

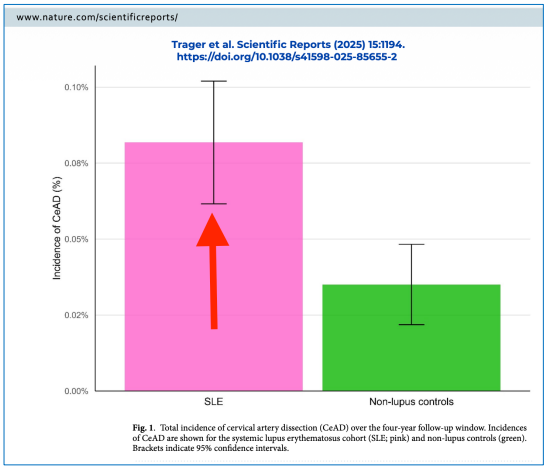

Fig. 1. Total incidence of cervical artery dissection (CeAD) over the four-year follow-up window. Incidences of CeAD are shown for the systemic lupus erythematosus cohort (SLE; pink) and non-lupus controls (green). Brackets indicate 95% confidence intervals.

165

Arq Neuropsiquiatr 2005;63(2-B):523-526

INTERNAL CAROTID ARTERY DISSECTION IN A PATIENT WITH RECENT RESPIRATORY INFECTION

Case report of a possible link

Cynthia Resende Campos[1], Thiago Gasperini Bassi[2], Fabiano Pinto[2], Demétrius Kasak P. Abrahão[3]

ABSTRACT - The pathogenesis of spontaneous cervical artery dissection remains unknown. Infection-mediated damage of the arterial wall may be an important triggering mechanism. We describe a 21 year-old man with respiratory infection (bronchial pneumonia) which was diagnosed and treated with antibiotic few days prior to the right internal carotid artery dissection. The patient presented ischemic retinal and cerebral strokes. Based on literature review, we discuss the possibility of a causal link between infection and arterial dissection.

KEY WORDS: carotid dissection, infection, stroke.

- A 21- year-old man with fever, cough and purulent sputum was diagnosed as lobar pneumonia (leukocytosis: 16.9/nL and positive chest X-ray) and treated with levofloxacin for 3 days.

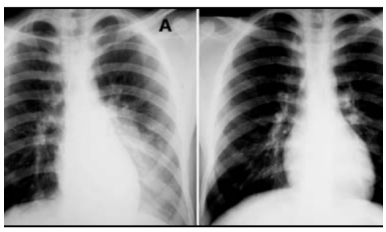

Chest X-ray. A: At first admission, prior to antibiotic t
. B. After the treatment, at the second admission.

166

Arq Neuropsiquiatr 2005;63(2-B):523-526

INTERNAL CAROTID ARTERY DISSECTION IN A PATIENT WITH RECENT RESPIRATORY INFECTION

Case report of a possible link

Cynthia Resende Campos[1], Thiago Gasperini Bassi[2], Fabiano Pinto[2], Demétrius Kasak P. Abrahão[3]

ABSTRACT - The pathogenesis of spontaneous cervical artery dissection remains unknown. Infection-mediated damage of the arterial wall may be an important triggering mechanism. We describe a 21 year-old man with respiratory infection (bronchial pneumonia) which was diagnosed and treated with antibiotic few days prior to the right internal carotid artery dissection. The patient presented ischemic retinal and cerebral strokes. Based on literature review, we discuss the possibility of a causal link between infection and arterial dissection.

KEY WORDS: carotid dissection, infection, stroke.

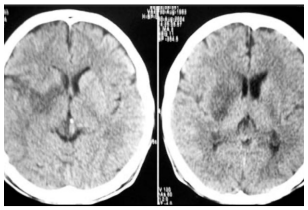

1 2. Brain CT: right striatocapsular ischemic stroke.

- On the fourth day, pneumonia symptoms had improved, including coughing, and he was discharged.
- In the same night, he woke up with a sudden onset of intense right hemi-cranial and retroorbital pain followed by visual disturbance and left hemiplegia.
- Brain CT revealed a right striatocapsular ischemic stroke (Fig 2).
- Four-vessel digital angiography showed an irregular high-grade stenosis at the right internal carotid artery (ICA) starting about 2 cm distal to the carotid bulb extending until an occlusion into the petrous bone.
- The proximal segment of the right ICA had a tapered flame-like appearance. There was an accentuation of the filling of the external carotid artery branches (Fig 3).
- These findings supported the diagnosis of arterial dissection.

167

Arq Neuropsiquiatr 2005;63(2-B):523-526

INTERNAL CAROTID ARTERY DISSECTION IN A PATIENT WITH RECENT RESPIRATORY INFECTION

Case report of a possible link

Cynthia Resende Campos[1], Thiago Gasperini Bassi[2], Fabiano Pinto[2], Demétrius Kasak P. Abrahão[3]

ABSTRACT - The pathogenesis of spontaneous cervical artery dissection remains unknown. Infection-mediated damage of the arterial wall may be an important triggering mechanism. We describe a 21 year-old man with respiratory infection (bronchial pneumonia) which was diagnosed and treated with antibiotic few days prior to the right internal carotid artery dissection. The patient presented ischemic retinal and cerebral strokes. Based on literature review, we discuss the possibility of a causal link between infection and arterial dissection.

KEY WORDS: carotid dissection, infection, stroke.



- In conclusion, we call attention to the diagnosis of CAD as an important cause of ischemic stroke in young patients and reinforce the possibility of recent infection as an environmental trigger factor for spontaneous CAD.

Infection??? How about iatrogenic Fluoroquinolone caused CAD?

168



- **Detecting the Burgeoning CAD:**
  - Detailed History + Time
  - Due Diligence + Time
  - Emphasis on Importance to Reporting S/S + Time
  - Re-Evaluation + Time

169

Purpose



170

POSTGRADDC
EVIDENCE BASED, CLINICALLY INTUITIVE CE

Cervical Artery Dissection due to Fluoroquinolones, NOT Chiropractic!

James Demetrious, DC, DABCO
Diplomate, American Board of Chiropractic Orthopedists

www.PostGradDC.com

171

Course Syllabus

- CAD: The Evidence
- Diagnostic Risk Factors
- Protopathic Bias
- Chiropractic Detection
- Fluoroquinolones

172

Fluoroquinolones and CAD

173

e-Journal

Quarterly Journal of ACO – March 2008 – Volume 5; Issue 1

Original Articles

Iatrogenic Tendinopathy Associated with Levaquin (levofloxacin)

Ronald C Evans, DC, FACO, FICC
Senior Orthopedist, ICON Whole Health 1441 29th Street, Suite 100, West Des Moines, Iowa, 50266

Figure 1. Localized swelling at the 3-6 cm level (from the calcaneal insertion) in the left Achilles tendon.



174

Journal of Athletic Training 2014;49(3):422–427
doi: 10.4085/1062-6050-49.2.09
© by the National Athletic Trainers' Association, Inc
www.natajournals.org

systematic review

Fluoroquinolones and Tendinopathy: A Guide for Athletes and Sports Clinicians and a Systematic Review of the Literature

Trevor Lewis, MSc, MCSP*; Jill Cook, PhD†

*Physiotherapy Department, Aintree University Hospital National Health Service Foundation Trust, University Hospital Aintree, Liverpool, United Kingdom; †Department of Physiotherapy, Monash University–Peninsula Campus, Frankson, Victoria, Australia

Key Points

- Tendinopathy can be a complication of treatment with fluoroquinolone antibiotics and usually is linked with 1 or more synergistic factors.
- Symptoms of fluoroquinolone-related tendinopathy can present within hours of starting treatment or up to 6 months after ceasing treatment, and recovery can be slower and require a less aggressive approach early in rehabilitation than for other types of tendinopathy.
- Treatment with fluoroquinolones should be discontinued and treatment with a nonquinolone antibiotic should be considered in patients who present with tendinopathy.
- Clinicians, athletes, athletic trainers, and medical support teams should be aware of and alert to the potential adverse effects of fluoroquinolones.

Journal of Athletic Training 2014;49(3):422–427

175

Unidentified Etiology of Cervical Artery Dissection?...Fluoroquinolones

Downloaded from http://bmjopen.bmj.com/ on October 26, 2016 - Published by group.bmj.com

Open Access Research

BMJ Open Fluoroquinolones and collagen associated severe adverse events: a longitudinal cohort study

Nick Daneman,[1,2,3,4] Hong Lu,[1] Donald A Redelmeier[1,2,3,5]

To cite: Daneman N, Lu H, Redelmeier DA. Fluoroquinolones and collagen associated severe adverse events: a longitudinal cohort study. *BMJ Open* 2015;5:e010077. doi:10.1136/bmjopen-2015-010077

► Prepublication history for this paper is available online. To view these files please visit the journal online (http://dx.doi.org/10.1136/bmjopen-2015-010077).

ABSTRACT

Objectives: Fluoroquinolone-associated tendon ruptures are a recognised complication, but other severe collagen-associated adverse events may also be possible. Our objectives were to confirm the association of fluoroquinolones and tendon rupture, to clarify the potential association of fluoroquinolones and retinal detachment, and to test for a potentially lethal association between fluoroquinolones and aortic aneurysms.

Setting: Population-based longitudinal cohort study in Ontario, Canada.

Participants: Older adults turning 65 years between April 1 1997 and March 31 2012 were followed until primary outcome, death, or end of follow-up (March 31

Strengths and limitations of this study

- This study reports a novel and important association of fluoroquinolone prescriptions with aortic aneurysms.
- The study design involves a population-based, longitudinal analysis of 1.7 million older adults.
- The findings are robust across multiple sensitivity, subgroup and tracer analyses.
- Misclassification of fluoroquinolone exposure is possible, if some patients did not use their dispensed prescriptions.
- Underdetection of mild or asymptomatic outcome events is possible.

176

Research

Original Investigation

Risk of Aortic Dissection and Aortic Aneurysm in Patients Taking Oral Fluoroquinolone

Chien-Chang Lee, MD, ScD; Meng-tse Gabriel Lee, PhD; Yueh-Sheng Chen, MD; Shih-Hao Lee, MA; Yih-Sharng Chen, MD, PhD; Shyr-Chyr Chen, MD, MBA; Shan-Chwen Chang, MD, PhD

IMPORTANCE Fluoroquinolones have been associated with collagen degradation, raising safety concerns related to more serious collagen disorders with use of these antibiotics, including aortic aneurysm and dissection.

Editor's Note page 1847

Supplemental content at jamainternalmedicine.com

- Cipro (ciprofloxacin), Avelox (moxifloxacin), Levaquin (Levofloxacin),Floxin (ofloxacin), Factive (gemifloxacin), Noroxin (norfloxacin)

177

RESEARCH

OPEN ACCESS

Fluoroquinolone use and risk of aortic aneurysm and dissection: nationwide cohort study

Björn Pasternak,[1,2] Malin Inghammar,[2,3] Henrik Svanström[2]

[1]Clinical Epidemiology Unit T2, Department of Medicine Solna, Karolinska Institutet, 17176 Stockholm, Sweden
[2]Department of Epidemiology Research, Statens Serum Institut, Copenhagen, Denmark
[3]Section for Infection Medicine, Department of Clinical Sciences Lund, Lund University, Lund, Sweden
Correspondence to: B Pasternak bjorn.pasternak@ki.se

Additional material is published online only. To view please visit the journal online.
Cite this as: BMJ 2018;360:k678
http://dx.doi.org/10.1136/bmj.k678
Accepted: 22 January 2018

ABSTRACT

OBJECTIVE
To investigate whether oral fluoroquinolone use is associated with an increased risk of aortic aneurysm or dissection.

DESIGN
Nationwide historical cohort study using linked register data on patient characteristics, filled prescriptions, and cases of aortic aneurysm or dissection.

SETTING
Sweden, July 2006 to December 2013.

PARTICIPANTS
360 088 treatment episodes of fluoroquinolone use (78%ciprofloxacin) and propensity score matched comparator episodes of amoxicillin use (n=360 088).

CONCLUSIONS
In a propensity score matched cohort, fluoroquinolone use was associated with an increased risk of aortic aneurysm or dissection. This association appeared to be largely driven by aortic aneurysm.

Introduction

Fluoroquinolones remain among the most commonly used antibiotics globally, and about 30 million outpatient prescriptions for fluoroquinolones are issued per year in the United States alone.[1 2] Fluoroquinolone use is associated with an increased risk of tendon disorders, including Achilles tendon rupture and tendinopathy.[3 4] The mechanisms behind these adverse events, which are recognised in a boxed warning, are thought to implicate non-antimicrobial properties of

178

Fluoroquinolone adverse effects

Often prescribed for urinary, respiratory, dermatologic and other infections, severe adverse effects of fluoroquinolones have been reported in the U.S., causing the Food and Drug Administration to communicate advisories related to safety and utilization:

- October 2008- Warning on tendon injuries with fluoroquinolone antibiotics.
- August 2013- Warning on peripheral neuropathy injuries with fluoroquinolone antibiotics.
- May 12, 2016- FDA approves safety labeling changes for fluoroquinolones.
- July 26, 2016- FDA Drug Safety Communication: FDA updates warnings for oral and injectable fluoroquinolone antibiotics due to disabling side effects.

Demetrious *Chiropractic & Manual Therapies* (2018) 26:22
https://doi.org/10.1186/s12998-018-0193-z

179

Jun and Fang *BMC Cardiovasc Disord* (2021) 21:470
https://doi.org/10.1186/s12872-021-02258-1
BMC Cardiovascular Disorders

REVIEW Open Access

Current progress of fluoroquinolones-increased risk of aortic aneurysm and dissection

Cui Jun[1] and Bian Fang[2*]

"Of note, in December 2018, FDA issued several "black box warnings" against FQ with the latest safety announcement warning about an increased risk of ruptures in the aorta blood vessel in certain patients."

180

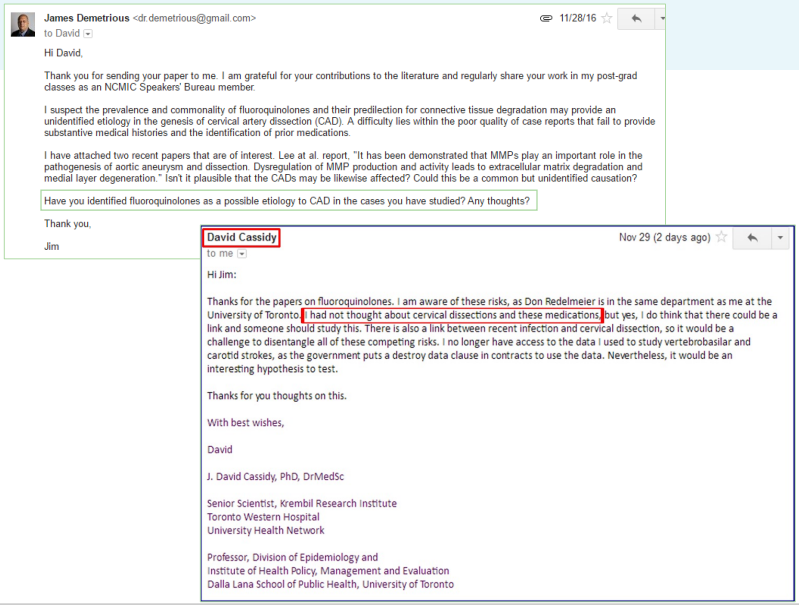

James Demetrious <dr.demetrious@gmail.com> 11/28/16

to David

Hi David,

Thank you for sending your paper to me. I am grateful for your contributions to the literature and regularly share your work in my post-grad classes as an NCMIC Speakers' Bureau member.

I suspect the prevalence and commonality of fluoroquinolones and their predilection for connective tissue degradation may provide an unidentified etiology in the genesis of cervical artery dissection (CAD). A difficulty lies within the poor quality of case reports that fail to provide substantive medical histories and the identification of prior medications.

I have attached two recent papers that are of interest. Lee at al. report, "It has been demonstrated that MMPs play an important role in the pathogenesis of aortic aneurysm and dissection. Dysregulation of MMP production and activity leads to extracellular matrix degradation and medial layer degeneration." Isn't it plausible that the CADs may be likewise affected? Could this be a common but unidentified causation?

Have you identified fluoroquinolones as a possible etiology to CAD in the cases you have studied? Any thoughts?

Thank you,

Jim

David Cassidy Nov 29 (2 days ago)

to me

Hi Jim:

Thanks for the papers on fluoroquinolones. I am aware of these risks, as Don Redelmeier is in the same department as me at the University of Toronto. I had not thought about cervical dissections and these medications, but yes, I do think that there could be a link and someone should study this. There is also a link between recent infection and cervical dissection, so it would be a challenge to disentangle all of these competing risks. I no longer have access to the data I used to study vertebrobasilar and carotid strokes, as the government puts a destroy data clause in contracts to use the data. Nevertheless, it would be an interesting hypothesis to test.

Thanks for you thoughts on this.

With best wishes,

David

J. David Cassidy, PhD, DrMedSc

Senior Scientist, Krembil Research Institute
Toronto Western Hospital
University Health Network

Professor, Division of Epidemiology and
Institute of Health Policy, Management and Evaluation
Dalla Lana School of Public Health, University of Toronto

181

Demetrious *Chiropractic & Manual Therapies* (2018) 26:22
https://doi.org/10.1186/s12998-018-0193-z

Chiropractic & Manual Therapies

HYPOTHESIS Open Access

Spontaneous cervical artery dissection: a fluoroquinolone induced connective tissue disorder?

James S. Demetrious

Conclusion: A causal relationship of fluoroquinolone antibiotics to cervical artery dissection is plausible. The suppositions developed in this paper are insufficient to suggest that fluoroquinolones currently represent an established risk factor in the development of cervical artery dissections. Fluoroquinolones may indeed be a novel and previously unrecognized cause of cervical artery dissections.

182

Demetrious *Chiropractic & Manual Therapies* (2018) 26:22
https://doi.org/10.1186/s12998-018-0193-z

Chiropractic & Manual Therapies

HYPOTHESIS Open Access

Spontaneous cervical artery dissection: a fluoroquinolone induced connective tissue disorder?

James S. Demetrious

Epidemiology

- Spontaneous cervical artery dissections are a common cause of stroke in young adults, with a mean age of occurrence of approximately 45 years and a slight gender predisposition favoring males 48–55% [1, 2].
- During a 17-year study period, Lee et al. reported a mean annual incident rate of 2.6 to 3.1 per 100,000 population [3].
- A seasonal variation has been reported with cervical artery dissection more likely to occur in the winter [4].
  - Paciaroni M, Georgiadis D, Arnold M, Gandjour J, Keseru B, Fahrni G, et al. Seasonal variability in spontaneous cervical artery dissection. J Neurol Neurosurg Psychiatry. 2006;77:677–9.

183

Demetrious *Chiropractic & Manual Therapies* (2018) 26:22
https://doi.org/10.1186/s12998-018-0193-z

Chiropractic & Manual Therapies

HYPOTHESIS Open Access

Spontaneous cervical artery dissection: a fluoroquinolone induced connective tissue disorder?

James S. Demetrious

Congenital risk factors

- Heritable disorders such as:
  - Ehlers-Danlos syndrome,
  - Marfan syndrome,
  - osteogenesis imperfecta type 1,
  - autosomal dominant polycystic kidney disease,
  - and fibromuscular dysplasia have been reported as risk factors for cervical artery dissection [2].
- While only 1–5% of patients with these connective tissue disorders have been identified with spontaneous vertebral artery dissection, 20% of patients have a yet unnamed connective tissue disorder [5].

184

Demetrious *Chiropractic & Manual Therapies* (2018) 26:22
https://doi.org/10.1186/s12998-018-0193-z

Chiropractic & Manual Therapies

HYPOTHESIS Open Access

Spontaneous cervical artery dissection: a fluoroquinolone induced connective tissue disorder?

James S. Demetrious

Environmental risk factors

- A history of recent infection has been associated as a risk factor for cervical artery dissection [6, 7].
- Suda et al. reported an average of 24.5% more antibiotic prescriptions were dispensed in the winter months than in the summer, over a 5-year study period with a mean outpatient consumption of quinolone antibiotics of 13.66% [8].
- These combined factors may partially explain the seasonal variation and increased risk of dissection during winter months.

185

Demetrious *Chiropractic & Manual Therapies* (2018) 26:22
https://doi.org/10.1186/s12998-018-0193-z

Chiropractic & Manual Therapies

HYPOTHESIS Open Access

Spontaneous cervical artery dissection: a fluoroquinolone induced connective tissue disorder?

James S. Demetrious

Fluoroquinolone adverse effects

- Currently, the FDA has advised that fluoroquinolones should be reserved for use in patients who have no other treatment options for:
  - acute bacterial sinusitis,
  - acute bacterial exacerbation of chronic bronchitis,
  - and uncomplicated urinary tract infections

  because the risk of severe side effects outweighs the benefits in these patients.

For some serious bacterial infections, the benefits of fluoroquinolones outweigh the risks, and it is appropriate for them to remain available as a therapeutic option [9].

186

Demetrious *Chiropractic & Manual Therapies* (2018) 26:22
https://doi.org/10.1186/s12998-018-0193-z

Chiropractic &
Manual Therapies

HYPOTHESIS Open Access

Spontaneous cervical artery dissection: a fluoroquinolone induced connective tissue disorder?

James S. Demetrious

Fluoroquinolones and connective tissue toxicity

- The FDA issued a Black Box warning for adverse effects associated with fluoroquinolones following surveillance data that associated these medications with tendinitis and tendon rupture.
- Wise et al. reported that the use of fluoroquinolones was associated with a 4-fold increase risk of Achilles tendinopathy and a 2-fold increase of tendon rupture in a database study of 6.4 million patients [10].
- Collagen degradation due to fluoroquinolones reportedly involves the upregulation of matrix metalloproteinases resulting in a reduction in the quantity and quality of collagen fibrils [11].

187

Demetrious *Chiropractic & Manual Therapies* (2018) 26:22
https://doi.org/10.1186/s12998-018-0193-z

Chiropractic &
Manual Therapies

HYPOTHESIS Open Access

Spontaneous cervical artery dissection: a fluoroquinolone induced connective tissue disorder?

James S. Demetrious

Fluoroquinolone latency

- A considerable latency from the commencement of fluoroquinolones to the onset of symptoms have been attributed to delayed mitochondrial toxicity, depletion, mutation, and cytotoxicity providing a foundation for reported occurrence of associated adverse effects [12].
- In a review of 98 case reports of fluoroquinolone-associated tendinopathy, symptoms were reported as occurring within two hours of taking the medication to as long as six months after the cessation of treatment, with the median time of onset of six days [13].
- The FDA reports that side effects occurred within hours to weeks after starting the fluoroquinolone, for an average of fourteen months to as long as nine years after stopping the medicines.
- Several cases reported that some side effects stopped or improved after discontinuation of the drug; others reported the side effects worsened or continued [9].

188

Demetrious *Chiropractic & Manual Therapies* (2018) 26:22
https://doi.org/10.1186/s12998-018-0193-z

Chiropractic & Manual Therapies

HYPOTHESIS Open Access

Spontaneous cervical artery dissection: a fluoroquinolone induced connective tissue disorder?

James S. Demetrious

Fluoroquinolones, aortic aneurysms, and cervical arterial dissections

- Collagen is a major extracellular matrix component of the aortic wall raising the concern that fluoroquinolones may cause or aggravate an aortic aneurysm and dissection.
- Lee et al. reported a 2- fold increase in the risk of an aortic aneurysm and dissection within 60 days of fluoroquinolone exposure [14].
- The tunica adventitia of the aortic, carotid and vertebral arteries are comprised of dense irregular connective tissue containing loosely organized collagen fibers [17].
- As fluoroquinolones may induce degradation of collagen causing aortic dissection and aneurysm, this raises the concern that fluoroquinolones may cause cervical artery dissections by a similar mechanism.

189

Demetrious *Chiropractic & Manual Therapies* (2018) 26:22
https://doi.org/10.1186/s12998-018-0193-z

Chiropractic & Manual Therapies

HYPOTHESIS Open Access

Spontaneous cervical artery dissection: a fluoroquinolone induced connective tissue disorder?

James S. Demetrious

Discussion

- It is plausible that fluoroquinolones may incite connective tissue degradation and play a contributory role in the genesis of cervical artery dissections.
- When considering relationships the extent of adverse effects associated with fluoroquinolones, some multifactorial, interrelated risk factors and associations warrant further investigation regarding the etiology of spontaneous cervical artery dissection:
  - Connective tissue: Aortic and cervical arteries are comprised of connective tissue. Fluoroquinolone toxicity is associated with connective tissue degradation and aortic aneurysms. Adverse effects of fluoroquinolone medications may explain why otherwise normal; young populations experience cervical artery dissections.
  - Infections and seasonal relationships: Infections are associated with an increased risk of cervical artery dissection. The frequency of infections, fluoroquinolone utilization and cervical artery dissections increase during winter months. These temporal relationships may predispose patients to iatrogenic cervical artery dissections.
  - Latency: The latencies of clinical manifestations following the utilization of fluoroquinolone medications require careful consideration by clinicians.
- When considering these factors, it is reasonable to ponder an associated causality between fluoroquinolone use and cervical artery dissection.

190

Demetrious *Chiropractic & Manual Therapies* (2018) 26:22
https://doi.org/10.1186/s12998-018-0193-z

Chiropractic & Manual Therapies

HYPOTHESIS Open Access

Spontaneous cervical artery dissection: a fluoroquinolone induced connective tissue disorder?

James S. Demetrious

Conclusion

- A causal relationship of fluoroquinolone antibiotics to cervical artery dissection is plausible. Fluoroquinolones may indeed be a novel and previously unrecognized cause of cervical artery dissections.
- This hypothesis is insufficient to conclude that fluoroquinolones represent a current and established risk factor for the development of cervical artery dissections.
- An initial call for case reports and formal investigation is warranted. An extensive longitudinally observed population study might shed light upon this subject.

191

Use of fluoroquinolones and the risk of spontaneous cervical artery dissection

E. Del Zotto[a] and A. Pezzini[b]

[a]*U.O. Neurologia, Istituto Ospedaliero Poliambulanza, Brescia; and* [b]*Dipartimento di Scienze Cliniche e Sperimentali Clinica Neurologica, Università degli Studi di Brescia, Brescia, Italy*

Keywords: cervical artery dissection, fluoroquinolones, ischaemic, stroke

Received 16 October 2018
Accepted 23 January 2019

European Journal of Neurology 2019, **26:** 1028–1031

doi:10.1111/ene.13917

Background and purpose: Because of their potential to alter the integrity of collagen and other components of the extracellular matrix, fluoroquinolone antibiotics might be involved in the pathogenesis of spontaneous cervical artery dissection (sCeAD).

Methods: In the setting of a single-centre case–control study, whether fluoroquinolone use in the 30-day period before the index event is associated with sCeAD (cases) in comparison with a group of age- and sex-matched patients who suffered a first-ever acute cerebral infarction from a cause other than CeAD (non-CeAD IS, controls) was assessed.

Results: Overall, 284 cases (mean age 43.2 ± 10.4 years; 58.5% men) and 568 controls qualified for the analysis. Thirty (10.6%) patients in the sCeAD group and 16 (2.8%) in the non-CeAD IS group were fluoroquinolone users ($P \leq 0.001$). The use of these antibiotics was associated with a more than two-fold increased risk of sCeAD [odds ratio (OR) 2.31; 95% confidence interval (CI) 1.00–5.30] after adjusting for confounders. The risk was more substantial in the subgroup of patients with dissection involving the carotid artery (OR 2.78; 95% CI 1.14–6.78), in females (OR 4.58; 95% CI 1.04–20.1) and compared to that conferred by other antibiotics (OR 2.42; 95% CI 1.02–5.75).

Conclusions: Fluoroquinolones may represent a novel contributing factor involved in the pathogenesis of sCeAD.

192

Internal Medicine
The Japanese Society of Internal Medicine
doi: 10.2169/internalmedicine.6736-20
Intern Med 60: 2863-2865, 2021
http://internmed.jp

【 CASE REPORT 】

Vertebral Artery Dissection after Exposure to Levofloxacin: A Report of Two Cases

Taku Harada [1,2], Yukinori Harada [2] and Taro Shimizu [2]

Abstract:
Exposure to quinolones is known to be an independent risk factor for aortic dissection; however, the association with vertebral artery dissection remains unclear. We report two cases of vertebral artery dissection that occurred 4 and 8 days after exposure to levofloxacin, respectively. Both patients had risk factors for vertebral artery dissection, and quinolone use could have been avoided. These two cases indicate that quinolone exposure can be a risk factor for vertebral artery dissection. Considering the possible mechanism, it is better to avoid the prescription of quinolones to patients who have insufficient connective tissues to avoid vertebral artery dissection.

Key words: vertebral artery dissection, quinolone, drug adverse effect

(Intern Med 60: 2863-2865, 2021)
(DOI: 10.2169/internalmedicine.6736-20)

193

Case 1

- A 45-year-old man presented to the emergency department with sudden-onset left posterior neck pain and left hemiparesis.
- His medical history included hypertension, dyslipidemia, and diabetes mellitus, and he had taken levofloxacin orally for a sore throat and cough for 8 days.
- He had no history of connective tissue disease or head and neck trauma.
- His vital signs were normal, except for high blood pressure (152/95 mmHg).
- A neurological examination revealed nystagmus, left hemifacial hypoalgesia, left-sided deficit of cranial nerves VII, IX, and X and paralysis of the left upper limb.
- Magnetic resonance imaging (MRI)/magnetic resonance angiography (MRA) of the brain revealed left vertebral artery dissection and infarction of the left me-dulla (Fig. 1, 2).
- A diagnosis of Wallenberg syndrome associated with vertebral artery dissection was made.
- He received conservative therapy and was subsequently tranferred to a rehabilitation hospital on day 30. He had a Modified Rankin Scale score of 3.

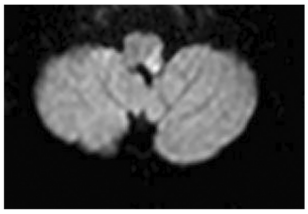

Figure 1. On diffusion-weighted magnetic resonance imaging, the left lateral medulla showed a high signal intensity.

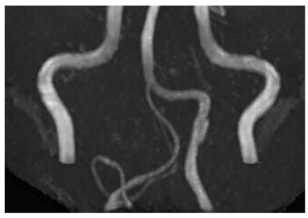

Figure 2. Magnetic resonance angiography showed dilation of the left vertebral artery with irregularity.

194

National Institute of Neurological Disorders and Stroke

- **Wallenberg's syndrome or Lateral Medullary Syndrome** is a neurological condition caused by a stroke in the:
  - vertebral or
  - posterior inferior cerebellar artery of the brain stem.
- Symptoms include:
  - difficulties with swallowing,
  - hoarseness, dizziness,
  - nausea and vomiting,
  - rapid involuntary movements of the eyes (nystagmus),
  - and problems with balance and gait coordination.
  - Some individuals will experience a lack of pain and temperature sensation on only one side of the face, or a pattern of symptoms on opposite sides of the body – such as paralysis or numbness in the right side of the face, with weak or numb limbs on the left side.
  - Uncontrollable hiccups may also occur, and some individuals will lose their sense of taste on one side of the tongue, while preserving taste sensations on the other side.
  - Some people with Wallenberg's syndrome report that the world seems to be tilted in an unsettling way, which makes it difficult to keep their balance when they walk.

195

@Neudrawlogy

LATERAL MEDULLARY SYNDROME - WALLENBERG'S SYNDROME

What? *Acute continuous vertigo* due to *Posterior Circulation Stroke (usually Posterior Inferior Cerebellar Artery occlusion)*

CLINICAL FINDINGS:

Nausea/vomiting/vertigo /nystagmus	Vestibular nucleus (CN 8)
Ageusia	Solitary nucleus/tract
Ipsilateral ataxia	Inferior cerebellar peduncle
Ipsilateral facial numbness	Trigeminal nucleus (CN 5) /tract
Ipsilateral Horner's Syndrome	Sympathetic pathway
Contralateral loss of pain/ temperature	Spinothalamic tract
Palatal myoclonus	Central tegmental tract
Hoarseness/dysphagia	Nucleus ambiguus - CN 9, 10)

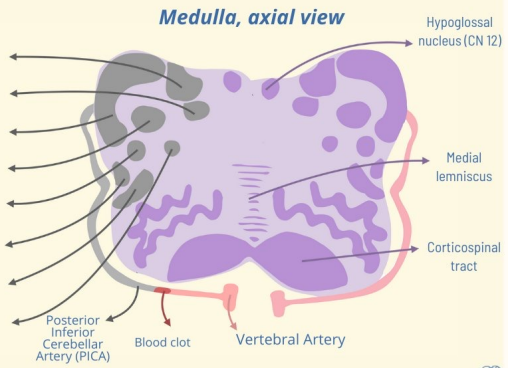

196

Intern Med 60: 2863-2865, 2021

Case 2

- A 66-year-old man was transferred to the hospital for the treatment of pancreatitis with pancreatic abscess.
- He developed pneumonia and was initially treated with intravenous levofloxacin on postoperative day 9.
- He developed sudden-onset left occipital pain on postoperative day 13.
- MRI/MRA performed on postoperative day 17 revealed left vertebral artery dissection (Fig. 3).
- His vital signs were normal, with no neurologic abnormalities, and
- MRI showed no complications of ischemic stroke.
- The administration of levofloxacin was continued until postoperative day 30. The patient was discharged on postoperative day 35 with no neurological complications.

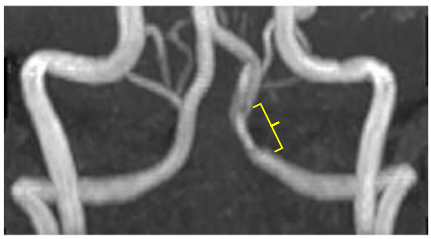

Figure 3. Magnetic resonance angiography showed dilatation of the left vertebral artery with focal stenosis.

197

Intern Med 60: 2863-2865, 2021

- There are several possible mechanisms through which quinolones may cause arterial dissection:
  - Quinolones have properties, such as chelation of several metal ions (e.g., calcium, magnesium, and aluminum), which are essential for type 1 collagen synthesis (1),
  - The decreased expression and activity of lysyl oxidase, and the increased expression and activity of matrix metalloproteinases (1, 5).
    - Type 1 collagen is a major component of the vessel wall (6), and a decrease of type 1 collagen may lead to vessel wall vulnerability.
    - The lysyl oxidases are extracellular copper enzymes that initiate the crosslinking of collagens and elastin.
    - These crosslinks provide the tensile strength and elastic properties of vascular walls.
    - Some reports indicated that decreased expression of lysyl oxidase can be associated with vulnerability of arteries (7), which can result in aortic dissection and aneurysm (8).
  - Matrix metalloproteinases are a family of proteolytic enzymes that degrade several components of the extracellular matrix and which mediate vascular remodeling, which may cause vascular dissection. In fact, increase serum levels of matrix metalloproteinase-9 have been reported to be associated with vertebral artery dissection (9).

198

Intern Med 60: 2863-2865, 2021

- Quinolone is an overused antimicrobial drug.
- If quinolones can cause vertebral artery dissection, efforts to revisit the appropriate use of quinolones may reduce the incidence of vertebral artery dissection.
- The FDA recommends that quinolones not be used by individuals who are at risk for aortic dissection or aortic aneurysm (13).
- Similarly, since vertebral artery dissection can cause serious ischemic stroke, physicians should reconsider the need for quinolones in patients who have additional risk factors for vertebral artery dissection.

199

A Medical Intragenic Cause of CAD

ELSEVIER
Archives of Cardiovascular Diseases Supplements
Volume 15, Issue 1, January 2023, Pages 112-113

498

Fluoroquinolone use preceding medium-size artery dissection: A case series

L. Wang [1], B. Oehmichen [1], B. Pariente [1], N. Mohamedi [1], C. Cheng [1], G. Détriché [1], A. Galloula [1], L. Khider [1], A. Lillo Le Louet [2], E. Messas [1], L. Amar [3], G. Goudot [1], T. Mirault [1]

[1] Médecine vasculaire, hôpital européen Georges-Pompidou, AP–HP, Paris
[2] Centre régional de pharmacovigilance, hôpital européen Georges-Pompidou, AP–HP, Paris
[3] Hypertension artérielle, hôpital européen Georges-Pompidou, AP–HP, Paris

Fluoroquinolone adverse effects

- To our knowledge, it is the first case series reporting visceral artery dissections following a treatment by FQ.
- All the previous studies establishing a link between arterial dissection and FQ were related to aortic syndrome or carotid arteries.
- Although this class of antibiotics is effective to treat many infectious diseases, their prescription must be earmarked for weighed medical indications and avoided in patients with a previous history of dissection or underlying condition of arterial fragility.
- In addition, the search for a fluoroquinolone intake must be carried out precisely in the event of the discovery of a medium-sized arterial dissection.

200

Journal of Clinical Neuroscience 93 (2021) 6–16

Contents lists available at ScienceDirect

Journal of Clinical Neuroscience

journal homepage: www.elsevier.com/locate/jocn

Vertebrobasilar and internal carotid arteries dissection in 188 patients

Biljana Georgievski Brkić [a], Tatjana Dučić Jaramaz [b], Marjana Vukičević [c], Nataša Stanisavljević [d], Dejan Kostić [e], Miloš Lučić [f], Ivan Marinković [g,*], Tija Apostolović [h], Tatjana Vlašković [i], Ana Ćirković [j], Slobodan Marinković [k]

[a] Department of CT and MRI, Sveti Sava Hospital, University of Belgrade, Belgrade, Serbia
[b] Department of Cerebrovascular Diseases, Sveti Sava Hospital, University of Belgrade, Belgrade, Serbia
[c] Department of Cerebrovascular Diseases, Sveti Sava Hospital, University of Belgrade, Belgrade, Serbia
[d] Department of Hematology, Clinical Hospital Center Bežanijska kosa, Faculty of Medicine, University of Belgrade, Serbia
[e] Institute of Radiology, Military Medical Academy, Belgrade, Serbia
[f] Imaging Center, Institute of Oncology, Faculty of Medicine, University of Novi Sad, Sremska Kamenica, Serbia
[g] Clinical Neuroscience, Neurology, Helsinki University Hospital, University of Helsinki, Finland
[h] Department of Intensive Care, Sveti Sava Hospital, University of Belgrade, Belgrade, Serbia
[i] Laza Lazarević Psychiatric Hospital, Faculty of Medicine, University of Belgrade, Belgrade, Serbia
[j] Institute of Anatomy, Faculty of Medicine, University of Belgrade, Belgrade, Serbia
[k] Department of Neuroanatomy, Institute of Anatomy, Faculty of Medicine, University of Belgrade, Belgrade, Serbia

skull base surgery [49,55,84]. Certain types of medication can occasionally produce dissections [50,54,85], then arterial elongation [60], fibromuscular dysplasia and connective tissue diseases [8,12,42,86–88], polycystic kidney disease, pregnancy and postpartum [89–91], as well as certain gene mutations [9,86,92–94].

[84] Rowan N, Turner M, Valappil B, Fernandez-Miranda J, Wang E, Gardner P, et al. Injury of the carotid artery during endoscopic endonasal surgery: Surveys of skull base surgeons. J Neurol Surg B Skull Base 2018;79(03):302–8.
[85] Demetrious JS. Spontaneous cervical artery dissection: a fluoroquinolone induced connective tissue disorder? Chiropr Man Therap 2018;26:22.
[86] Henrard C, Belge H, Fastré S, et al. Cervical artery dissection: fibromuscular dysplasia versus vascular Ehlers-Danlos syndrome. Blood Press

201

Journal of Clinical Neuroscience 87 (2021) 26–28

Contents lists available at ScienceDirect

Journal of Clinical Neuroscience

journal homepage: www.elsevier.com/locate/jocn

Case report

Unilateral common carotid artery dissection in a patient with recent COVID-19: An association or a coincidence?

Onur Serdar Gencler [a,*], Meltem Refiker Ege [b], Aydın Aslan [c]

[a] Department of Neurology, Medical Park Ankara Hospital, Yuksek Ihtisas University, Kent Koop District, 1868 Street Batikent Avenue. No:15, Yenimahalle, Ankara 06680, Turkey
[b] Department of Cardiology, Medical Park Ankara Hospital, Yuksek Ihtisas University, Kent Koop District, 1868 Street, Batikent Avenue. No:15, Yenimahalle, Ankara 06680, Turkey
[c] Department of Radiology, Liv Hospital, Yuksek Ihtisas University, Kavaklidere Avenue Bestekar Road No:8. Cankaya, Ankara 06680, Turkey

ARTICLE INFO

Article history:
Received 3 December 2020
Accepted 13 February 2021

Keywords:
COVID-19
Carotid artery dissection
Ischemic stroke
Thromboinflammatory changes
Vascular complications

ABSTRACT

The "Corona Virus Disease 2019 (COVID-19)", caused by severe acute respiratory coronavirus 2 (SARS-CoV-2), progressed rapidly since its first outbreak, and quickly developed into a pandemic. Although COVID-19 mostly presents with respiratory symptoms, researchers have started reporting neurologic manifestations such as cerebrovascular diseases in patients, with COVID-19 as the pandemic has progressed. Herein, we report a case of 38-year-old female patient identified with a left common carotid artery dissection, with COVID-19. Clinicians must keep in mind that COVID-19 can cause vascular complications such as carotid artery dissections in the ensuing period, even after the acute phase, although there is currently a lack of sufficient evidence to identify any causal association between COVID-19 and arterial dissections.

© 2021 Elsevier Ltd. All rights reserved.

"It was understood that the patient had presented to an external facility with complaints of fever and fatigue approximately 1 month earlier, and had received therapy after being diagnosed with COVID-19."

References

[1] Ellul MA, Benjamin L, Singh B, Lant S, Michael BD, Easton A, et al. Neurological associations of COVID-19. Lancet Neurol 2020;19(9):767–83. https://doi.org/10.1016/S1474-4422(20)30221-0.
[2] Mao L, Jin H, Wang M, Hu Y, Chen S, He Q, et al. Neurologic manifestations of hospitalized patients with coronavirus disease 2019 in Wuhan, China. JAMA Neurol 2020;77(6):683–90. https://doi.org/10.1001/jamaneurol.2020.1127.
[3] Oxley TJ, Mocco J, Majidi S, Kellner CP, Shoirah H, Singh IP, et al. Large-vessel stroke as a presenting feature of Covid-19 in the young. N Engl J Med 2020;382(20):. https://doi.org/10.1056/NEJMc2009787e60.
[4] Patel P, Khandelwal P, Gupta G, Singla A. COVID-19 and cervical artery dissection-A causative association? J Stroke Cerebrovasc Dis 2020;29(10):. https://doi.org/10.1016/j.jstrokecerebrovasdis.2020.105047105047.
[5] Feigin VL, Forouzanfar MH, Krishnamurthi R, Mensah GA, Connor M, Bennett DA, et al. Global Burden of Diseases, Injuries, and Risk Factors Study 2010 (GBD 2010) and the GBD Stroke Experts Group. Global and regional burden of stroke during 1990-2010: findings from the Global Burden of Disease Study 2010. Lancet 2014;383(9913):245–54. https://doi.org/10.1016/s0140-6736(13)61953-4.
[6] Marini C, Russo T, Felzani G. Incidence of stroke in young adults: a review. Stroke Res Treat 2010;2011:. https://doi.org/10.4061/2011/535672535672.
[7] Tsivgoulis G, Palaiodimou L, Zand R, Lioutas VA, Krogias C, Katsanos AH, et al. COVID-19 and cerebrovascular diseases: a comprehensive overview. Ther Adv Neurol Disord 2020;13. https://doi.org/10.1177/1756286420978004.
[8] Cai X, Guan J, Ren S, Wei Y, Peng X, Qiu W, et al. Treatment of internal carotid artery dissection with Willis covered stent: a case report of recurrent limb weakness and no response to medical therapy. Exp Ther Med 2016;11(5):1983–6. https://doi.org/10.3892/etm.2016.3112.
[9] Demetrious JS. Spontaneous cervical artery dissection: a fluoroquinolone induced connective tissue disorder? Chiropr Man Therap 2018;26:22. https://doi.org/10.1186/s12998-018-0193-z.
[10] Campos CR, Bassi TC, Pinto F, Abrahão DK. Internal carotid artery dissection in a patient with recent respiratory infection: case report of a possible link. Arq Neuropsiquiatr 2005;63(2B):523–6. https://doi.org/10.1590/s0004-282x2005000300029.



202

Jun and Fang *BMC Cardiovasc Disord* (2021) 21:470
https://doi.org/10.1186/s12872-021-02258-1

BMC Cardiovascular Disorders

REVIEW Open Access

Current progress of fluoroquinolones-increased risk of aortic aneurysm and dissection

Cui Jun[1] and Bian Fang[2*]

- Population-based studies reported an annual incidence of AA of 3–13.7/100,000 population, and AD of 3–20/100,000 population [2–4].
- Over the past decades, it is suggested that the rate of mortality from AA and AD has risen ranging from 1.2 to 24.8 fold in many developed countries, such as the United States, Britain and Japan [6, 7].
- Fluoroquinolones (FQ) are the most widely used pre- scribed antibiotics in the world. In the United States alone, about 30 million outpatient prescribed with FQ per year [9].
- FQ shows activity against both Gram-positive and Gram-negative bacteria, and are widely used to treat skin, urinary tract, bone, soft tissue, pulmonary infections and so on.

203

Jun and Fang *BMC Cardiovasc Disord* (2021) 21:470
https://doi.org/10.1186/s12872-021-02258-1

BMC Cardiovascular Disorders

REVIEW Open Access

Current progress of fluoroquinolones-increased risk of aortic aneurysm and dissection

Cui Jun[1] and Bian Fang[2*]

- **FQ are classified into 5 categories:**
  - 1st generation FQ include nalidixic acid, oxolinic acid, pipemidic acid and rosoxacin.
  - 2nd generation FQ contain ciprofloxacin, norfloxacin, enoxacin, pefloxacin, lomefloxacin, nadifloxacin, rufloxacin, and ofloxacin.
  - 3rd generation FQ contain levofloxacin, pazufloxacin, temafloxacin, tosufloxacin, sparfloxacin, gre- pafloxacin, and balofloxacin
  - 4th generation FQ include prulifloxacin, trovafloxacin, alatrofloxacin, delafloxacin, clinafloxacin, besifloxacin, sitafloxacin, finafloxacin, gatifloxacin, gemi- floxacin, and moxifloxacin
  - 5th generation FQ include lev- onadifloxacin, nemonoxacin (non-fluorinated quinolone antibiotic), and zabofloxacin

204

AE

Jun and Fang *BMC Cardiovasc Disord* (2021) 21:470
https://doi.org/10.1186/s12872-021-02258-1

BMC Cardiovascular Disorders

REVIEW Open Access

Current progress of fluoroquinolones-increased risk of aortic aneurysm and dissection

Cui Jun[1] and Bian Fang[2*]

- The most common AEs of FQ are mild and reversible, like headaches, diarrhea and nausea. However, we should pay more attention to **FQ-related serious AEs**, such as:
  - tendinitis and tendon rupture,
  - hepatic toxicity,
  - *Clostrid- ium difficile* infections,
  - prolonged QT interval,
  - torsades de pointes (ventricular tachycardia),
  - phototoxicity,
  - dysglycemia,
  - acute renal failure and
  - seizures [23, 24]
  - arrhythmia (85% increase) and cardiovascular mortality (71% increase).
  - In December 2018, FDA issued several "black box warnings" against FQ about an increased risk of ruptures in the aorta blood vessel in certain patients.

205

AE

Jun and Fang *BMC Cardiovasc Disord* (2021) 21:470
https://doi.org/10.1186/s12872-021-02258-1

BMC Cardiovascular Disorders

REVIEW Open Access

Current progress of fluoroquinolones-increased risk of aortic aneurysm and dissection

Cui Jun[1] and Bian Fang[2*]

- Numerous studies have highlighted the critical roles of smooth muscle function and extracellular matrix (ECM) (collagen and elastic fibers) in structural integrity of the arterial wall.
- **Collagen and elastic fibers play important roles in the mechanical properties of the vessel wall.**
- At the pathological level, TAA is characterized by medial degeneration, including:
  - elastic fibers fragmentation and loss of elastic tissue,
  - vascular smooth muscle cells (VSMCs) loss, defects in collagen microarchitecture,
  - proteoglycan deposition and a less remarkable inflammatory cells infiltration.
- Moreover, three important pathological marks are displayed in the progression of AAA:
  - ECM degradation,
  - VSMCs loss and
  - infiltration of macrophages, neutrophils, mast cells and T/B lymphocytes.

206

Duration of FQ Use

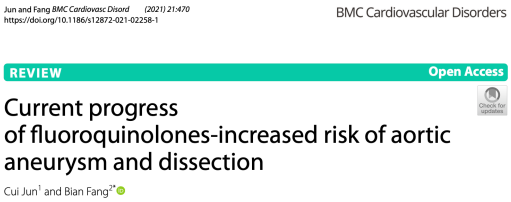
Jun and Fang BMC Cardiovasc Disord (2021) 21:470
https://doi.org/10.1186/s12872-021-02258-1

BMC Cardiovascular Disorders

REVIEW Open Access

Current progress of fluoroquinolones-increased risk of aortic aneurysm and dissection

Cui Jun[1] and Bian Fang[2*]

- Lee et al. [1] found an increased risk in AAD with FQ use (rate ratio [RR]=2.43; 95% confidence interval [CI]=1.83–3.22).
- Revealed a twofold increase the risk of AAD after FQ exposure.
- Oral FQ were associated with increased incidence of aneurysm formation in United States adults.

207

Duration of FQ Use

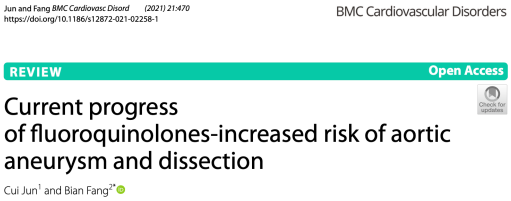
Jun and Fang BMC Cardiovasc Disord (2021) 21:470
https://doi.org/10.1186/s12872-021-02258-1

BMC Cardiovascular Disorders

REVIEW Open Access

Current progress of fluoroquinolones-increased risk of aortic aneurysm and dissection

Cui Jun[1] and Bian Fang[2*]

- Current FQ use within 60 days was associated with the highest risk of AAD.
- Increased risk of AAD with prolonged FQ use.
- Higher risk of AAD was associated with FQ exposure for longer than 14 days.
- However, recent results indicated that FQ were associated with increased 90-day incidence of:
  - AAA (HR=1.31; 95% CI 1.25–1.37),
  - iliac artery aneurysm (HR = 1.60; 95% CI 1.33–1.91),
  - and other AAA (HR=1.58; 95% CI 1.39–1.79) [41].
- Of note, the investigator suggested that FQ should be used with caution in adults, not just in high-risk individuals [41].

208

Table 2 Types of FQ use and the incidence of AAD

FQ	Outcome	References
All FQ	AAD	[44]
Ciprofloxacin	AAD	[44]
	AA	[45]
Levofloxacin	AAD	[8, 44–46]
	AA	[45]
Moxifloxacin	AAD, AA	[44, 45]
	AA	[45]
Ofloxacin	None	[44]
Enoxacin, fleroxacin, gemifloxacin, grepafloxacin, lomefloxacin, norfloxacin, pazufloxacin, pefloxacin, prulifloxacin, rufloxacin, sparfloxacin, temafloxacin, trovafloxacin	None	[46]
Oral FQ	AAD	[1, 4, 8, 9, 45, 47]
Oral FQ	AAA, iliac artery aneurysm and other AAA	[41]

FQ fluoroquinolones, *AA* aortic aneurysm, *AAD* aortic aneurysm and dissection

Jun and Fang *BMC Cardiovasc Disord* (2021) 21:470

209

Mechanisms of FQ Damage

Jun and Fang *BMC Cardiovasc Disord* (2021) 21:470
https://doi.org/10.1186/s12872-021-02258-1

BMC Cardiovascular Disorders

REVIEW Open Access

Current progress of fluoroquinolones-increased risk of aortic aneurysm and dissection

Cui Jun[1] and Bian Fang[2*]

- Some hypothesized biological mechanisms have been proposed:
  - FQ may interfere with ECM integrity in the aortas.
  - Dysregulation of ECM homeostasis disrupted ECM integrity and impaired biomechanical strength, which finally triggered progressive aortic weakening, dissection, or rupture [55].
  - Enzymatic degradation of ECM by MMPs and vascular remodeling constituted the most prominent characters of AA [56].
  - FQ reduced collagen production in tenocytes [57] and fibroblasts [58].
  - Ciprofloxacin (the most commonly used FQ) suppressed TIMP-1 expression but enhanced MMP expression in the cornea [59], in tendon cells and tissues [57, 60], and in fibroblasts [61], which finally promoted MMP activation and tissue destruction.

210

Mechanisms of FQ Damage

Jun and Fang *BMC Cardiovasc Disord* (2021) 21:470
https://doi.org/10.1186/s12872-021-02258-1

BMC Cardiovascular Disorders

REVIEW Open Access

Current progress of fluoroquinolones-increased risk of aortic aneurysm and dissection

Cui Jun[1] and Bian Fang[2*]

- It was suggested that ciprofloxacin greatly up-regulated MMP activity more than twofold in cultured human aortic smooth muscle cells (HASMCs) [62].
- Human aortic fibroblasts exposed to FQ showed an increased capacity for ECM dysregulation by reducing the expression of collagen and endogenous pro-tease inhibitors protein.
- They further demonstrated collagen degradation and decreased TIMPs activity in human aortic fibroblasts cultured with 2 days FQ [63].
- A recent study confirmed that ciprofloxacin significantly increased the incidence of AAD (79%) in mice [47].

211

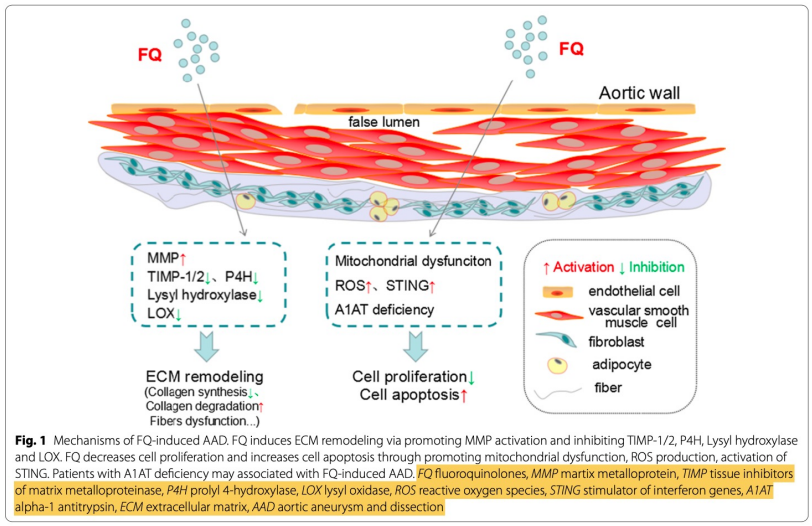

Fig. 1 Mechanisms of FQ-induced AAD. FQ induces ECM remodeling via promoting MMP activation and inhibiting TIMP-1/2, P4H, Lysyl hydroxylase and LOX. FQ decreases cell proliferation and increases cell apoptosis through promoting mitochondrial dysfunction, ROS production, activation of STING. Patients with A1AT deficiency may associated with FQ-induced AAD. *FQ* fluoroquinolones, *MMP* martix metalloprotein, *TIMP* tissue inhibitors of matrix metalloproteinase, *P4H* prolyl 4-hydroxylase, *LOX* lysyl oxidase, *ROS* reactive oxygen species, *STING* stimulator of interferon genes, *A1AT* alpha-1 antitrypsin, *ECM* extracellular matrix, *AAD* aortic aneurysm and dissection

Jun and Fang *BMC Cardiovasc Disord* (2021) 21:470

212

Difficult (IF Not Impossible DX)

Peter Tuchin
to me

Tue, Jul 26, 6:19 PM (17 hours ago)

Hi Jim

Many case reports do not supply good clinical info in their history summary, so IMO, to determine clear indications for a potential CAD is very difficult (if not impossible)

FQ could certainly be a significant factor and one which has not previously received strong recognition. Most case reports don't ask about any recent infections or FQ use.

But I suspect there are a multitude of factors, which may be different for almost every case. These factors include things you mentioned (genetics, risk factors such as smoking, migraine, etc), but also include other minor activities (eg sports, or activities involving neck movements) which appear to be the last factor that damages a probably weakened artery.

These other minor activities (eg sports, or activities involving neck movements) are rarely documented in any detail making it very hard to get a clear timeline of symptoms. I have attached 2 recent case reports to highlight this

213

In Conclusion…

214

POSTGRADDC
EVIDENCE BASED, CLINICALLY INTUITIVE CE

Clinical Risk Management:
Cervical Artery Dissection - Diagnosis

James Demetrious, DC, DABCO
Diplomate, American Board of Chiropractic Orthopedists

www.PostGradDC.com

215

Syllabus



216

Syllabus

- **We will review:**
  - Mild SMT AEs
  - Incidence rate of CAD.
  - The rarity of CAD that makes the provision of epidemiological evidence challenging.
  - Bad Science – The Lack of Causality
  - Several extensive cohort studies and meta-analyses have found no excess risk of CAD resulting in secondary ischemic stroke for chiropractic SMT compared to primary care.
  - Retrospective cohort studies have reported no association with traumatic injury to the head or neck after SMT for neuromusculoskeletal pain.
  - Studies that have disproven any misconception about whether SMT strains exceed failure strains.
  - No changes in blood flow or velocity in the VA of healthy young male adults were found in various head positions and during a cervical SMT.
  - CAD Assessment Tool
  - Cases

217

CeAD Diagnostic Delay



Journal of the American Heart Association

ORIGINAL RESEARCH

Possible Diagnostic Error in Cervical Artery Dissection: Analysis of STOP-CAD Study

- 663 of 4,012 patients (16.5%) had a health care encounter for CeAD-attributable symptoms in the 30 days before diagnosis.
- Median symptom-to-diagnosis time was 7 days with possible error versus 1 day without.
- Error was more likely with younger age, migraine history, headache, and no focal deficit.

218

CeAD Diagnostic Delay



Misdiagnosis of Cervicocephalic Artery Dissection in the Emergency Department

Ava L. Liberman, MD; Babak B. Navi, MD, MS; Charles C. Esenwa, MD, MS; Cenai Zhang, MS; Justin Song, BS; Natalie T. Cheng, MD; Daniel L. Labovitz, MD; Hooman Kamel, MD; Alexander E. Merkler, MD

Background and Purpose—Cervicocephalic artery dissection is an important cause of stroke. The clinical presentation of dissection can resemble that of benign neurological conditions leading to delayed or missed diagnosis.

Methods—We performed a retrospective cohort study using statewide administrative claims data from all Emergency Department visits and admissions at nonfederal hospitals in Florida from 2005 to 2015 and New York from 2006 to 2015. Using validated *International Classification of Diseases, Ninth Revision, CM* codes, we identified adult patients hospitalized for cervicocephalic artery dissection. We defined probable misdiagnosis of dissection as having an Emergency Department treat-and-release visit for symptoms or signs of dissection, including headache, neck pain, and focal neurological deficits in the 14 days before dissection diagnosis. Multivariable logistic regression was used to compare adverse clinical outcomes in patients with and without probable misdiagnosis.

Results—Among 7090 patients diagnosed with a dissection (mean age 52.7 years, 44.9% women), 218 (3.1% [95% CI, 2.7%–3.5%]) had a preceding probable Emergency Department misdiagnosis. After adjustment for demographics and vascular risk factors, there were no differences in rates of stroke (odds ratio, 0.82 [95% CI, 0.62–1.09]) or in-hospital death (odds ratio, 0.26 [95% CI, 0.07–1.08]) between dissection patients with and without a probable misdiagnosis at index hospitalization.

Conclusions—We found that ≈1 in 30 dissection patients was probably misdiagnosed in the 2 weeks before their diagnosis. (*Stroke*. 2020;51:1876-1878. DOI: 10.1161/STROKEAHA.120.029390.)

Key Words: diagnosis ■ diagnostic errors ■ dissection ■ headache

- We found that ≈1 in 30 patients with cervicocephalic artery dissection had a probable ED misdiagnosis in the 14 days before their hospitalization for dissection.
- After adjustment for demographics and vascular comorbidities, probable **ED misdiagnosis of dissection was not associated with increased odds of stroke or death at index hospitalization.**

CeAD Diagnostic Delay



Misdiagnosis of Cervicocephalic Artery Dissection in the Emergency Department

Ava L. Liberman, MD; Babak B. Navi, MD, MS; Charles C. Esenwa, MD, MS; Cenai Zhang, MS; Justin Song, BS; Natalie T. Cheng, MD; Daniel L. Labovitz, MD; Hooman Kamel, MD; Alexander E. Merkler, MD

Background and Purpose—Cervicocephalic artery dissection is an important cause of stroke. The clinical presentation of dissection can resemble that of benign neurological conditions leading to delayed or missed diagnosis.

Methods—We performed a retrospective cohort study using statewide administrative claims data from all Emergency Department visits and admissions at nonfederal hospitals in Florida from 2005 to 2015 and New York from 2006 to 2015. Using validated *International Classification of Diseases, Ninth Revision, CM* codes, we identified adult patients hospitalized for cervicocephalic artery dissection. We defined probable misdiagnosis of dissection as having an Emergency Department treat-and-release visit for symptoms or signs of dissection, including headache, neck pain, and focal neurological deficits in the 14 days before dissection diagnosis. Multivariable logistic regression was used to compare adverse clinical outcomes in patients with and without probable misdiagnosis.

Results—Among 7090 patients diagnosed with a dissection (mean age 52.7 years, 44.9% women), 218 (3.1% [95% CI, 2.7%–3.5%]) had a preceding probable Emergency Department misdiagnosis. After adjustment for demographics and vascular risk factors, there were no differences in rates of stroke (odds ratio, 0.82 [95% CI, 0.62–1.09]) or in-hospital death (odds ratio, 0.26 [95% CI, 0.07–1.08]) between dissection patients with and without a probable misdiagnosis at index hospitalization.

Conclusions—We found that ≈1 in 30 dissection patients was probably misdiagnosed in the 2 weeks before their diagnosis. (*Stroke*. 2020;51:1876-1878. DOI: 10.1161/STROKEAHA.120.029390.)

Key Words: diagnosis ■ diagnostic errors ■ dissection ■ headache

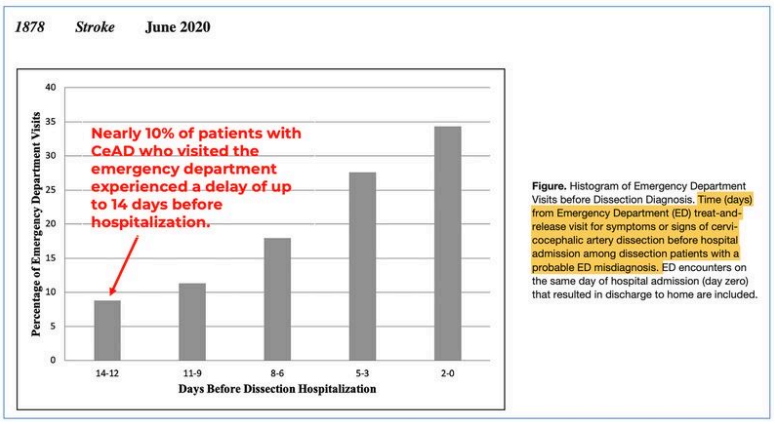

Figure. Histogram of Emergency Department Visits before Dissection Diagnosis. Time (days) from Emergency Department (ED) treat-and-release visit for symptoms or signs of cervicocephalic artery dissection before hospital admission among dissection patients with a probable ED misdiagnosis. ED encounters on the same day of hospital admission (day zero) that resulted in discharge to home are included.

To DX the Developing CAD, We Must Consider…

- Risk Factors
- Symptoms
- Signs

Extraordinarily difficult. CADs are rare. Most doctors will never see this problem. Patients often do not provide detailed histories despite our best efforts.

221

NIH Public Access
Author Manuscript
Neurologist. Author manuscript; available in PMC 2014 January 22.

Published in final edited form as:
Neurologist. 2012 September ; 18(5): 245–254. doi:10.1097/NRL.0b013e31826754e1.

Clinical Characteristics of Symptomatic Vertebral Artery Dissection. A Systematic Review

Rebecca F. Gottesman, MD PhD[1], Priti Sharma, MBBS[1], Karen A. Robinson, PhD[2], Martinson Arnan, MD[1], Megan Tsui[1], Karim Ladha, BA[1], and David E. Newman-Toker, MD PhD[1,3]

[1]Department of Neurology, The Johns Hopkins University School of Medicine, Baltimore, MD, USA

[2]Department of Medicine, The Johns Hopkins University School of Medicine, Baltimore, MD, USA

[3]Department of Epidemiology, The Johns Hopkins University School of Medicine, Baltimore, MD, USA

Neurologist. 2012 September ; 18(5): 245–254.

NIH-PA Author Manuscript

Neurologist. Author manuscript; available in PMC 2014 January 22.

Table 2

Symptoms and signs associated with VAD.

	# Studies	Total sample size (N)	Number of subjects with symptom	Pooled proportion (pooled SE)	Range of proportions
Dizziness/ Vertigo	18 [8, 16, 19, 28, 30, 32, 44, 47, 52, 55-57, 60-62, 65, 73, 74]	467	273	0.58 (0.53)	5-100%
Headache	32 [2, 9, 11, 12, 15, 19, 21, 22, 24, 25, 27, 28, 30, 32, 33, 35, 38, 41-46, 52, 53, 57, 60, 64-66, 69, 73]	689	348	0.51 (0.7)	6-93%
Neck Pain	27 [11, 12, 14, 15, 21, 22, 24, 25, 30, 35, 37, 38, 41, 43-45, 52, 53, 56, 57, 60, 61, 64-66, 69, 73]	526	244	0.46 (0.69)	10-80%
Gait problems/ Ataxia	10 [1, 6, 8, 16, 52, 53, 56, 57, 61, 65]	150	57	0.38 (0.43)	7-71%
Visual symptoms	17 [1, 6, 8, 12, 16, 30, 32, 37, 47, 52, 53, 56, 57, 61, 65, 72, 73]	314	114	0.36 (0.53)	4-88%
Nausea/ Vomiting	13 [1, 8, 12, 30, 32, 44, 52, 56, 57, 60, 65, 73, 74]	306	108	0.35 (0.42)	5-79%
Nystagmus	7 [6, 8, 30, 37, 56, 61, 65]	150	44	0.29 (0.30)	4-55%
Horner's syndrome	11 [30, 41, 44, 47, 52, 55, 60, 61, 65, 72, 73]	265	58	0.22 (0.03)	6-36%
Sensory deficits	17 [1, 8, 16, 30, 32, 37, 47, 52, 53, 55-57, 60, 61, 65, 72, 73]	335	70	0.21 (0.43)	4-58%
Cranial nerve palsies	11 [8, 30, 37, 47, 52, 53, 55, 56, 65, 72, 73]	241	51	0.21 (0.32)	4-43%
Dysphagia	6 [16, 53, 57, 60, 65, 74]	102	13	0.13 (0.20)	5-29%
Tinnitus	4 [5, 32, 44, 65]	238	17	0.07 (0.09)	5-13%

222

To DX the Developing CAD, We Must Consider…

SNNOOP10 Red and Orange Flags for Secondary Headaches

Red Flag Clinical Features / Concerns
Systemic symptoms (e.g., fever) suggesting infection or systemic metabolic/vascular/endocrine disorder.
Neoplasm (primary or secondary brain tumor).
Neurological symptoms/signs suggesting vascular, non-vascular, or infectious brain disorder.
Onset suggesting subarachnoid hemorrhage (SAH) or vascular dissection (intracranial/extracranial).
Older age (>50 years) suggesting giant cell arteritis, vascular disorders, neoplasms, or non-vascular disorders.
Pattern change or recent onset suggesting neoplasm or vascular/non-vascular disorder.
Positional headache suggesting intracranial hypertension or hypotension.
Precipitated by sneezing, coughing, or exercise suggesting posterior fossa pathology or Chiari malformation.
Papilloedema suggesting neoplasm, vascular disorder, or idiopathic intracranial hypertension (IIH).
Progressive headache or atypical presentation suggesting neoplasm or other intracranial disorder.
Pregnancy/puerperium suggesting vascular disorders, preeclampsia, CVST, hypothyroidism, anemia, diabetes.
Painful eye with autonomic features suggesting posterior fossa, pituitary, cavernous sinus pathology, Tolosa-Hunt syndrome, or ophthalmic causes.
Post-traumatic onset suggesting acute/persistent post-traumatic headache (PTH), subdural hematoma, or vascular disorder.
Pathology of immune system (e.g., HIV) suggesting opportunistic infection.
Painkiller overuse or new drug suggesting medication overuse headache or drug incompatibility.
Post-COVID headache suggesting persistent neuroinflammation (PCNS/Long COVID).
Post-vaccination headache (within one week) suggesting possible CVST.

Green Flags in Headache Assessment

Green Flag Features
Current headache present since childhood.
Headache occurs in temporal relationship with menstrual cycle.
Presence of headache-free days.
Close family members share the same headache phenotype.
Headache occurred or stopped more than one week ago.

Wijeratne et al. NeurologicalSci 32 (2023) 100473.

223

To DX the Developing CAD, We Must Consider…

	sCeAD	Migraine	Subarachnoid hemorrhage
			
Gender ratio (f:m)	1.4:1	3:1	3:2
Typical age	40 - 45 years	20 - 40 years	45 - 65 years
Duration	< 24 h	4 - 72 h	> 24 h
Quality	pulling / dull	throbbing	thunderclap
Accompanying symptoms	cerebral ischemia cranial nerve affection	nausea photophobia phonophobia aura	nausea cranial nerve affection cerebral ischemia meningeal irritation loss of consciousness
	singular event when unilateral always (100 %) ipsilateral to side of dissection	recurring with symptom-free interval	singular event with possible prodrome

224

Table 5

Outcomes following routine clinical care for VAD in 570 individuals with reported outcome*

	N with outcome	Pooled proportion	SE	Range of proportions
Good outcome (mRS 0-1)	394	0.67	0.60	33-100%
Fair outcome (mRS 2-4)	105	0.18	0.49	0-53%
Poor outcome (mRS 5-6)	59	0.10	0.38	0-35%

*Studies including outcome information:5, 6, 13, 14, 16, 19, 21, 24, 28, 31, 36-38, 41, 43, 45, 47, 50, 51, 55, 62, 69, 70, 72, 73

Neurologist. 2012 September ; 18(5): 245–254.

225

JoS JOURNAL OF STROKE
Journal of Stroke 2019;21(1):112-115
https://doi.org/10.5853/jos.2018.03055
Letter to the Editor

Local Signs and Symptoms in Spontaneous Cervical Artery Dissection: A Single Centre Cohort Study

- Spontaneous cervical artery dissection (sCAD) is one of the main causes of ischemic stroke in young adults.1
- Local symptoms (LSs) are common in sCAD and often predate ischemic events, yet little is known about their frequency and prognosis.2-9

226

Journal of Stroke 2019;21(1):112-115
https://doi.org/10.5853/jos.2018.03055

- Local Symptoms (LSs) were evident in 212 of the 259 sCAD patients (81.9%) with:
  - Head/neck pain being the most frequent (n=205, 79.2%),
  - followed by Horner's syndrome (n=42, 16.2%),
  - tinnitus (n=19, 7.3%), and
  - lower cranial nerve palsy (n=13, 5.0%).
- Multiple LSs were seen in 61 of 259 patients (23.6%).
- Headache was the only LS that was present in all patients with multiple LSs and head/ neck pain combined with Horner's syndrome was the most common combination of symptoms (34 of 61, 55.7%).

227

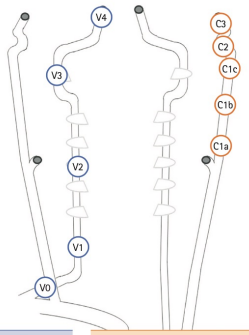

Vertebral artery	% V0-V4 (n=141)
Headache	84.4 (119)
Horner's	0.0
Cranial nerve palsy	0.0
Tinnitus	3.5 (5)

Internal carotid artery	% C1a-C3 (n=127)
Headache	74.8 (95)
Horner's	33.1 (42)
Cranial nerve palsy	10.2 (13)
Tinnitus	13.4 (17)

Vertebral artery	% V0-V2 (n=51)	% V3-V4 (n=119)
Headache	94.1 (48)	82.4 (98)
Horner's	0.0	0.0
Cranial nerve palsy	0.0	0.0
Tinnitus	3.9 (2)	2.5 (3)

Internal carotid artery	% C1a (n=23)	% C1b-C2 (n=118)	% C3 (n=5)
Headache	69.9 (16)	74.6 (88)	80.0 (4)
Horner's	30.4 (7)	33.9 (40)	20.0 (1)
Cranial nerve palsy	0.0	11.0 (13)	0.0
Tinnitus	21.7 (5)	11.9 (14)	40.0 (2)

Figure 2. Frequency of local symptoms according to vessel segment involvement in patients with spontaneous cervical artery dissection (sCAD). Patients with simultaneous anterior and posterior circulation sCAD (n=9) were excluded from this figure. In some patients, a singular dissection involved multiple vessel segments.

228

Stroke
Volume 52, Issue 3, March 2021; Pages 821-829
https://doi.org/10.1161/STROKEAHA.120.031579

CLINICAL AND POPULATION SCIENCES

Clinical Features of Patients With Cervical Artery Dissection and Fibromuscular Dysplasia

Table 2. Clinical Features, Triggering Factors, and Vascular Pathology of Index Cervical Artery Dissection by cFMD Status

Variable	cFMD+ (n=103)	cFMD− (n=1180)	*P* value
Clinical features			
Cervical pain	41 (39.8)	493 (41.8)	0.755
Headache	50 (48.5)	587 (49.7)	0.815
Tinnitus	6 (5.8)	57 (4.8)	0.633
Cranial nerve involvement	8 (7.8)	134 (11.4)	0.327
Horner syndrome	26 (25.2)	229 (19.4)	0.155
TIA	15 (14.6)	147 (12.5)	0.536
Cerebral infarct	73 (70.9)	864 (73.2)	0.607
Subarachnoid hemorrhage	0 (0.0)	18 (1.5)	0.390
Dissection site			0.547
Carotid	63 (61.2)	708 (60.0)	
Vertebral	19 (18.4)	277 (23.5)	
Intracranial arteries	2 (1.9)	25 (2.1)	
Multiple vessel	19 (18.4)	170 (14.4)	
Vascular pathology			≤0.001
Occlusion	33 (32.0)	520 (44.1)	
Stenosis	40 (38.8)	444 (37.6)	
Intimal flap	3 (2.9)	47 (4.0)	
Pseudoaneurysm	9 (8.7)	47 (4.0)	
Other	18 (17.5)	104 (9.0)	
Triggering factors			
Infections, past 30 d*	13 (12.6)	133 (11.3)	0.630
Antibiotics use	8 (61.5)	72 (54.1)	0.773
Trauma, minor	8 (7.8)	176 (14.9)	0.055
Strenuous physical activity	38 (36.9)	544 (46.1)	0.079
Acute-phase treatment			0.517
Antiplatelet therapy	51 (49.5)	538 (45.6)	
Anticoagulant treatment	40 (38.8)	457 (38.7)	
Any recanalization therapy	12 (11.7)	185 (15.7)	

cFMD indicates cerebrovascular fibromuscular dysplasia.

229

Chiropractic Detection

230

Clinical Awareness and Conspicuity

What Raises the Index of Suspicion from Commonality?



231

Myth exploded

CASE REPORT

Vertebral artery dissection in evolution found during chiropractic examination

Dan Futch,[1] Michael J Schneider,[2] Donald Murphy,[3] Allison Grayev[4]

[1]Department of Chiropractic Medicine, Group Health Cooperative of South Central Wisconsin, Madison, Wisconsin, USA
[2]Department of Physical Therapy, University of Pittsburgh, Pittsburgh, Pennsylvania, USA
[3]Department of Family Medicine, Alpert Medical School of Brown University, Pawtucket, Rhode Island, USA
[4]Department of Radiology, University of Wisconsin School of Medicine and Public Health, Madison, Wisconsin, USA

Correspondence to
Professor Michael J Schneider, mjs5@pitt.edu

SUMMARY
A 30-year-old woman presented to an emergency department with sudden onset of transient loss of left peripheral vision. Owing to a history of migraine headaches, she was released with a diagnosis of ocular migraine. Two days later, she sought chiropractic care for the chief symptom of severe neck pain. The chiropractor suspected the possibility of vertebral artery dissection (VAD). No manipulation was performed; instead, MR angiography (MRA) of the neck was obtained, which revealed an acute left VAD with early thrombus formation. The patient was placed on aspirin therapy. Repeat MRA of the neck 3 months later revealed resolution of the thrombus, without progression to stroke. This case illustrates the importance for all healthcare providers who see patients with neck pain and headache to be attentive to the symptomatic presentation of possible VAD in progress.

CASE PRESENTATION
A 30-year-old otherwise healthy woman consulted a chiropractor (DBF), reporting of right-sided neck pain in the suboccipital region. The patient reported that, 3 days previously, she had gone to the local hospital emergency department (ED) because of the sudden onset of loss of left peripheral vision. The visual symptoms interfered with her ability to see through her left eye; this was accompanied by 'numbness' in her left eyelid. About 2 weeks prior to this ED visit, she had experienced an episode of acute left-sided neck pain with severe left-sided headache. She also related a history of migraine headache without progress. Prompt diagnosis and anticoagulant treatment were thought to have averted progression to a stroke.

Futch D, et al. BMJ Case Rep 2015.

232

Myth exploded

CASE REPORT

Vertebral artery dissection in evolution found during chiropractic examination

Dan Futch,[1] Michael J Schneider,[2] Donald Murphy,[3] Allison Grayev[4]

Based on the history of sudden onset of **severe upper cervical pain and headache with visual disturbance and ocular numbness**, the DC was concerned about the possibility of early VAD. Urgent MR angiography (MRA) of the neck and head, along with MRI of the head, was ordered. No cervical spine examination or manipulation was performed…"

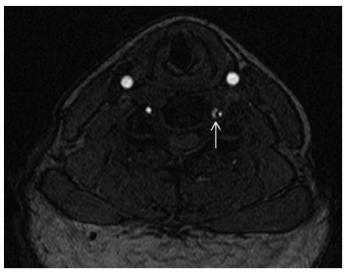

Figure 2 Axial image from three-dimensional time-of-flight MRA demonstrates T1 hypointense dissection flap separating the true lumen (lateral) from the false lumen (medial). MRA, MR angiography.

Futch D, et al. BMJ Case Rep 2015. doi:10.1136/bcr-2015-212568.

233

Sudden onset of headache/neck/face pain that's different than the patient has experienced before?

These are also known as the 5 D's and the 3 N's:

- **Diplopia** → Double vision or other vision problems
- **Dizziness** → Vertigo, light-headedness
- **Drop Attacks** → Sudden numbness/weakness of face/arm/leg
- **Disarthria** → Difficulty speaking
- **Dysphagia** → Difficulty swallowing
- **Ataxia of Gait** → Difficulty walking
- **Nausea** → Vomiting or queasiness
- **Numbness** → Loss of sensation on one side
- **Nystagmus** → Involuntary rapid eye movements

234

Clinical Condition: Headache

Variant 4: Sudden onset of unilateral headache or suspected carotid or vertebral dissection or ipsilateral Horner syndrome.

Radiologic Procedure	Rating	Comments	RRL*
CTA head and neck with IV contrast	8		☢☢☢
MRA head without IV contrast	8		O
MRA neck without and with IV contrast	8	Include T1 fat-saturated axial images in this procedure.	O
MRI head without and with IV contrast	8	Perform this procedure with DWI sequences.	O
MRI head without IV contrast	8	Perform this procedure with DWI sequences.	O
MRA neck without IV contrast	7	Include T1 fat-saturated axial images in this procedure.	O
CT head without IV contrast	7		☢☢☢
MRA head without and with IV contrast	6		O
MRI neck without and with IV contrast	6	Include T1 fat-saturated axial images in this procedure.	O
Arteriography cervicocerebral	6		☢☢☢
CT head without and with IV contrast	6		☢☢☢
CT head with IV contrast	6		☢☢☢
MRI neck without IV contrast	5	Include T1 fat-saturated axial images in this procedure.	O
MRI cervical spine without and with IV contrast	5		O
MRI cervical spine without IV contrast	4		O
CT neck with IV contrast	4		☢☢☢
CT neck without and with IV contrast	4		☢☢☢
CT neck without IV contrast	3		☢☢☢
US duplex Doppler carotid	3		O
Rating Scale: 1,2,3 Usually not appropriate; 4,5,6 May be appropriate; 7,8,9 Usually appropriate			*Relative Radiation Level

235

Journal of Chiropractic Medicine (2015) 14, 183–190
ELSEVIER
JCM Journal of Chiropractic Medicine
www.journalchiromed.com

Topics in Diagnostic Imaging

Chiropractic Response to a Spontaneous Vertebral Artery Dissection

Gary Tarola DC [a], Reed B. Phillips DC, PhD [b,*]

[a] Private Practice, Lehigh Valley Medical Network, Allentown, PA
[b] Adjunct Faculty, Southern California University of Health Sciences, Whittier, CA

Received 28 March 2015; received in revised form 13 October 2015; accepted 13 October 2015

- A 34-year old white woman reported to a chiropractic clinic with a constant burning pain at the right side of her neck and shoulder with a limited ability to turn her head from side to side, periods of **blurred vision, and muffled hearing.**
- **Dizziness, visual and auditory disturbances, and balance difficulty** abated within 1 hour of onset and were not present at the time of evaluation.
- A pain drawing indicated burning pain in the suboccipital area, neck, and upper shoulder on the right and a pins and needles sensation on the dorsal surface of both forearms.
- Turning her head from side-to-side aggravated the pain, and the application of heat brought temporary relief.
- The Neck Disability Index score of 44 placed the patient's **pain in the most severe category.**

236

Journal of Chiropractic Medicine (2014) 13, 90–95

ELSEVIER

JCM Journal of Chiropractic Medicine

www.journalchiromed.com

Recognition of Spontaneous Vertebral Artery Dissection Preempting Spinal Manipulative Therapy: A Patient Presenting With Neck Pain and Headache for Chiropractic Care

Ross Mattox DC [a,*], Linda W. Smith DC [b], Norman W. Kettner DC, DACBR, FICC [c]

[a] *Diagnostic Imaging Resident, Department of Radiology, Logan University, Chesterfield, MO*
[b] *Chiropractic Physician, Private Practice, St. Louis, MO*
[c] *Chair, Department of Radiology, Logan University, Chesterfield, MO*

Received 22 January 2014; received in revised form 13 April 2014; accepted 16 April 2014

- A 45-year-old otherwise healthy female presented for evaluation and treatment of neck pain and headache.
- Within minutes, non-specific musculoskeletal symptoms progressed to **neurological deficits, including limb ataxia and cognitive disturbances.**
- Suspicion was raised for cerebrovascular ischemia and emergent referral was initiated.

237

- A 45-year-old white female, well-nourished and employed as a school administrator, presented to a chiropractic clinic complaining of upper back/neck pain and stiffness as well as headache and pain in the posterior portion of the right arm down to the elbow of 3 days duration.
- Her level of discomfort progressed in severity in the 24 hours prior to presentation, which is what prompted her appointment. Because this was a new complaint, an updated history and examination were performed.
- No history of trauma was disclosed.
- Physical examination revealed painful and limited active range of motion in the cervical region. Palpation was provocative for tenderness.

Journal of Chiropractic Medicine (2014) 13, 90–95.

238

- After the initial examination, a working diagnosis of myofascial pain syndrome was established.
- Therapeutic ultrasound (Chattanooga Medical Supply, TN) was applied (4 minutes, 1 W/cm2 at 1 MHz) in the seated position over the suboccipital and posterior cervical musculature.
- While still in the seated position, soft tissue treatment was performed by a licensed massage therapist on the suboccipital and posterior cervical musculature.
- The patient was shown to a treatment room and was supine when the clinician entered and asked how she felt.
- The patient responded that her neck pain was much better, but she was more aware of her headache.

Journal of Chiropractic Medicine (2014) 13, 90–95.

239

- The patient was assisted to the seated posture, became dizzy, reported visual and cognitive disturbances, and had difficulty speaking.
- She proceeded to lose control of her right leg, which spontaneously assumed a flexion contracture.
- The clinician suspected a vascular etiology at this time and SMT was not performed.
- Paramedics were immediately summoned and the patient was transported to a local hospital with a working diagnosis of acute cerebrovascular ischemia.

Journal of Chiropractic Medicine (2014) 13, 90–95.

240

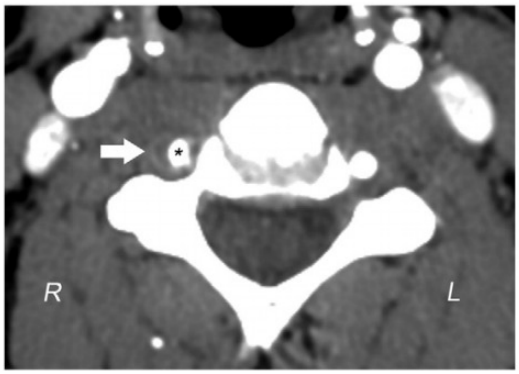

Fig 1. CTA with intravenous contrast at the level of C5 demonstrates a crescent-shaped mural thickening with annular enhancement (arrow) around a narrowed lumen of the right vertebral artery (asterisk).

Journal of Chiropractic Medicine (2014) 13, 90–95.

241



Fig 2. TOF-MRA with intravenous contrast demonstrates a narrowed V_2 segment of the right vertebral artery (arrow), with normal caliber vessel both cranial and caudal to the short stenotic region.



Fig 4. 3D reformat CTA viewed from posterior demonstrates narrowing of the V_2 segment of the right vertebral artery (arrow) extending from C5 to C3, with normal caliber vessel both cranially and caudally.

Journal of Chiropractic Medicine (2014) 13, 90–95.

242

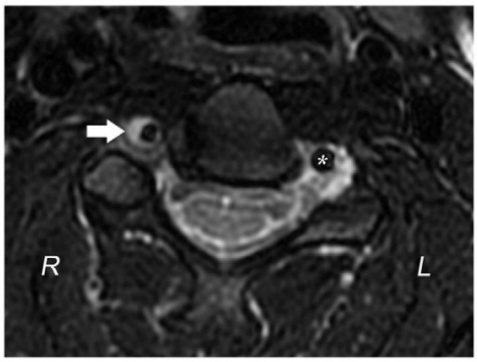

Fig 3. Axial gradient echo MRI demonstrates a narrowed lumen of the right vertebral artery compared to the left (asterisk) with a crescent-shaped mural thickening of high intensity (arrow) compared to the flow void within the lumen.

Journal of Chiropractic Medicine (2014) 13, 90–95.

243

Annals of Medicine

ISSN: 0785-3890 (Print) 1365-2060 (Online) Journal homepage: https://www.tandfonline.com/loi/iann20

A risk–benefit assessment strategy to exclude cervical artery dissection in spinal manual-therapy: a comprehensive review

Aleksander Chaibi & Michael Bjørn Russell

To cite this article: Aleksander Chaibi & Michael Bjørn Russell (2019) A risk–benefit assessment strategy to exclude cervical artery dissection in spinal manual-therapy: a comprehensive review, Annals of Medicine, 51:2, 118-127, DOI: 10.1080/07853890.2019.1590627

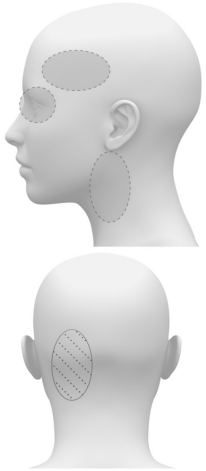

Figure 2. Typical pain distribution due to vertebral artery and internal carotid artery dissections.

244

Chaibi et al. report that history taking is the single most important factor for detecting subtle symptoms of CAD.

Chaibi A, Russell BR. A risk-benefit assessment strategy to exclude cervical artery dissection in spinal-therapy: a comprehensive review. Annals of Medicine. 2019; 51 (2)118-127.

245

Annals of Medicine
ISSN: 0785-3890 (Print) 1365-2060 (Online) Journal homepage: https://www.tandfonline.com/loi/iann20

A risk–benefit assessment strategy to exclude cervical artery dissection in spinal manual-therapy: a comprehensive review

Aleksander Chaibi & Michael Bjørn Russell

To cite this article: Aleksander Chaibi & Michael Bjørn Russell (2019) A risk–benefit assessment strategy to exclude cervical artery dissection in spinal manual-therapy: a comprehensive review, Annals of Medicine, 51:2, 118-127, DOI: 10.1080/07853890.2019.1590627

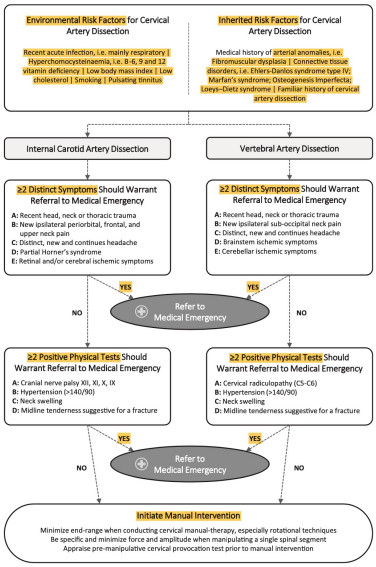

Figure 3. Step-by-step risk–benefit assessment strategy tool to exclude cervical artery dissection.

246

Chaibi and Russell's CAD Assessment Tool

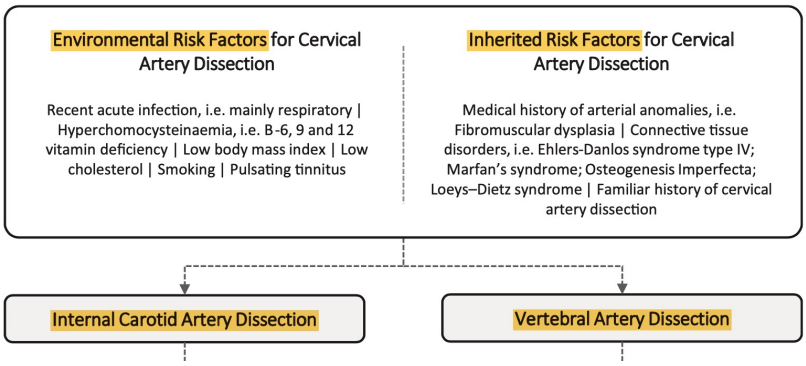

- **Other Risk Factors?:**
  - Age <45
  - Prior incident
  - Fluoroquinolone antibiotics
  - Arteriopathies
  - ?

Chaibi A, Russell BR. Annals of Medicine. 2019; 51 (2)118-127.

247

Stroke
Volume 36, Issue 7, 1 July 2005; Pages 1575-1580
https://doi.org/10.1161/01.STR.0000169919.73219.30

American Heart Association.

COMMENTS, OPINIONS, AND REVIEWS

A Systematic Review of the Risk Factors for Cervical Artery Dissection

Sidney M. Rubinstein, MSc, Saskia M. Peerdeman, MD, PhD, Maurits W. van Tulder, PhD, Ingrid Riphagen, MSc, and Scott Haldeman, MD, PhD

- ***Conclusions***
  - CAD is a multi-factorial disease. Many of the reviewed studies contained 2 or more major sources of bias commonly found in case-control studies.
  - Only one study (of homocysteine) used healthy controls, a robust sample size, and had a low risk of biased results.

248

Stroke
Volume 36, Issue 7, 1 July 2005; Pages 1575-1580
https://doi.org/10.1161/01.STR.0000169919.73219.30

COMMENTS, OPINIONS, AND REVIEWS

A Systematic Review of the Risk Factors for Cervical Artery Dissection

Sidney M. Rubinstein, MSc, Saskia M. Peerdeman, MD, PhD, Maurits W. van Tulder, PhD, Ingrid Riphagen, MSc, and Scott Haldeman, MD, PhD

- **Genetic or Inborn Predisposition/Disorders With a Familial Association**
  - Connective Tissue Disease
  - Gene-association Studies
  - Gene Mutation/Sequencing Studies
  - Homocysteine
  - Migraine
  - Vessel Abnormalities
- **Environmental Exposures**
  - Infection
  - Oral Contraceptive Use
  - Fluoroquinolones - Demetrious
- **Trauma**
  - Trivial Trauma

249

Journal of Clinical Neuroscience 87 (2021) 26–28
Contents lists available at ScienceDirect
Journal of Clinical Neuroscience
journal homepage: www.elsevier.com/locate/jocn

Case report

Unilateral common carotid artery dissection in a patient with recent COVID-19: An association or a coincidence?

Onur Serdar Gencler[a,*], Meltem Refiker Ege[b], Aydın Aslan[c]

[a] Department of Neurology, Medical Park Ankara Hospital, Yuksek Ihtisas University, Kent Koop District, 1868 Street Batikent Avenue. No:15, Yenimahalle, Ankara 06680, Turkey
[b] Department of Cardiology, Medical Park Ankara Hospital, Yuksek Ihtisas University, Kent Koop District, 1868 Street, Batikent Avenue. No:15, Yenimahalle, Ankara 06680, Turkey
[c] Department of Radiology, Liv Hospital, Yuksek Ihtisas University, Kavaklidere Avenue Bestekar Road No:8, Cankaya, Ankara 06680, Turkey

ARTICLE INFO

Article history:
Received 3 December 2020
Accepted 13 February 2021

Keywords:
COVID-19
Carotid artery dissection
Ischemic stroke
Thromboinflammatory changes
Vascular complications

ABSTRACT

The "Corona Virus Disease 2019 (COVID-19)", caused by severe acute respiratory coronavirus 2 (SARS-CoV-2), progressed rapidly since its first outbreak, and quickly developed into a pandemic. Although COVID-19 mostly presents with respiratory symptoms, researchers have started reporting neurologic manifestations such as cerebrovascular diseases in patients, with COVID-19 as the pandemic has progressed. Herein, we report a case of 38-year-old female patient identified with a left common carotid artery dissection, with COVID-19. Clinicians must keep in mind that COVID-19 can cause vascular complications such as carotid artery dissections in the ensuing period, even after the acute phase, although there is currently a lack of sufficient evidence to identify any causal association between COVID-19 and arterial dissections.

© 2021 Elsevier Ltd. All rights reserved.

"It was understood that the patient had presented to an external facility with complaints of fever and fatigue approximately 1 month earlier, and had received therapy after being diagnosed with COVID-19."

References

[1] Ellul MA, Benjamin L, Singh B, Lant S, Michael BD, Easton A, et al. Neurological associations of COVID-19. Lancet Neurol 2020;19(9):767–83. https://doi.org/10.1016/S1474-4422(20)30221-0.
[2] Mao L, Jin H, Wang M, Hu Y, Chen S, He Q, et al. Neurologic manifestations of hospitalized patients with coronavirus disease 2019 in Wuhan, China. JAMA Neurol 2020;77(6):683–90. https://doi.org/10.1001/jamaneurol.2020.1127.
[3] Oxley TJ, Mocco J, Majidi S, Kellner CP, Shoirah H, Singh IP, et al. Large-vessel stroke as a presenting feature of Covid-19 in the young. N Engl J Med 2020;382(20):. https://doi.org/10.1056/NEJMc2009787e60.
[4] Patel P, Khandelwal P, Gupta G, Singla A. COVID-19 and cervical artery dissection-A causative association? J Stroke Cerebrovasc Dis 2020;29(10):. https://doi.org/10.1016/j.jstrokecerebrovasdis.2020.105047105047.
[5] Feigin VL, Forouzanfar MH, Krishnamurthi R, Mensah GA, Connor M, Bennett DA, et al. Global Burden of Diseases, Injuries, and Risk Factors Study 2010 (GBD 2010) and the GBD Stroke Experts Group. Global and regional burden of stroke during 1990-2010: findings from the Global Burden of Disease Study 2010. Lancet 2014;383(9913):245–54. https://doi.org/10.1016/s0140-6736(13)61953-4.
[6] Marini C, Russo T, Felzani G. Incidence of stroke in young adults: a review. Stroke Res Treat 2010:2011:. https://doi.org/10.4061/2011/535672535672.
[7] Tsivgoulis G, Palaiodimou L, Zand R, Lioutas VA, Krogias C, Katsanos AH, et al. COVID-19 and cerebrovascular diseases: a comprehensive overview. Ther Adv Neurol Disord 2020;13. https://doi.org/10.1177/1756286420978004.
[8] Cai X, Guan J, Ren S, Wei Y, Peng X, Qiu W, et al. Treatment of internal carotid artery dissection with Willis covered stent: a case report of recurrent limb weakness and no response to medical therapy. Exp Ther Med 2016;11(5):1983–6. https://doi.org/10.3892/etm.2016.3112.
[9] Demetrious JS. Spontaneous cervical artery dissection: a fluoroquinolone induced connective tissue disorder? Chiropr Man Therap 2018;26:22. https://doi.org/10.1186/s12998-018-0193-z.
[10] Campos CR, Bassi TG, Pinto F, Abrahão DK. Internal carotid artery dissection in a patient with recent respiratory infection: case report of a possible link. Arq Neuropsiquiatr 2005;63(2B):523–6. https://doi.org/10.1590/s0004-282x2005000300029.

250

CAD is the Result of Pre-Existing Arteriopathy

Stroke
Volume 42, Issue 6, June 2011; Pages 1563-1568
https://doi.org/10.1161/STROKEAHA.110.599548

ORIGINAL CONTRIBUTIONS; CLINICAL SCIENCES

Vessel Wall Inflammation in Spontaneous Cervical Artery Dissection

A Prospective, Observational Positron Emission Tomography, Computed Tomography, and Magnetic Resonance Imaging Study

Thomas Pfefferkorn, MD, Tobias Saam, MD, Axel Rominger, MD, Maximilian Habs, MD, Lisa-Ann Gerdes, MD, Caroline Schmidt, MD, Clemens Cyran, MD, Andreas Straube, MD, Jennifer Linn, MD, Konstantin Nikolaou, MD, Peter Bartenstein, MD, Maximilian Reiser, MD, Marcus Hacker, MD, and Martin Dichgans, MD

- In conclusion, a subset of patients with spontaneous CAD showed signs of a generalized transient inflammatory arteriopathy in PET-CT and contrast enhanced hrMRI.
- This subset of patients may be more prone to multiple dissections.

251

CAD is the Result of Pre-Existing Arteriopathy

ELSEVIER
Legal Medicine
Volume 14, Issue 5, September 2012, Pages 249-251

Case Report

Spontaneous bilateral carotid artery dissection following cervical manipulation

Marilyn Carprieaux [a], Alex Michotte [a, b], Dirk Van Varenbergh [a], Miriam Pipeleers Marichal [a]

[a] Department of Pathology, UZ Brussel, Vrije Universiteit Brussel, Brussels, Belgium
[b] Department of Neurology, UZ Brussel, Vrije Universiteit Brussel, Brussels, Belgium

Received 5 February 2012, Revised 29 March 2012, Accepted 8 April 2012, Available online 23 May 2012.

- To establish the etiology of a cervical artery dissection is important in view of possible legal implications and to exclude hereditary disorders, since cervical artery dissection has been linked to several arteriopathies.
- The underlying arteriopathy in the presented case was an idiopathic cystic medial degeneration.
- This report emphasizes the role of the pathologist in defining the underlying arteriopathy in carotid artery dissection.

252

Chaibi and Russell's CAD Assessment Tool

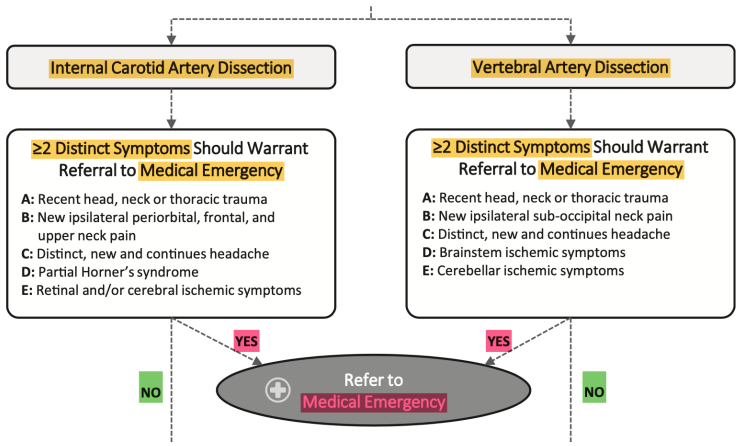

- **Other Symptoms?:**
  - Severity/location
  - Cranial Nerves
  - CNS
  - Bladder/Bowel
  - Gait
  - ?

Chaibi A, Russell BR. Annals of Medicine. 2019; 51 (2)118-127.

253

MAYO CLINIC

CONCISE REVIEW

Craniocervical Artery Dissections: A Concise Review for Clinicians

Zafer Keser, MD; James F. Meschia, MD; and Giuseppe Lanzino, MD

Mayo Clin Proc. ■ April 2022;97(4):777-783 ■ https://doi.org/10.1016/j.mayocp.2022.02.007
www.mayoclinicproceedings.org ■ © 2022 Mayo Foundation for Medical Education and Research



FIGURE 2. Dissection-related headache and neck pain (left). Miosis and ptosis of the left eye without anhidrosis, partial Horner syndrome. It is commonly seen in ipsilateral carotid dissections (right). (Used with permission of Mayo Foundation for Medical Education and Research, all rights reserved.)

254

Asymptomatic CAD Presentations are Rare

Pain as the only symptom of cervical artery dissection

M Arnold, R Cumurciuc, C Stapf, P Favrole, K Berthet, M-G Bousser

J Neurol Neurosurg Psychiatry 2006;**77**:1021–1024. doi: 10.1136/jnnp.2006.094359

See end of article for authors' affiliations

Correspondence to: M Arnold, Department of Neurology, University Hospital of Berne, Inselspital, Freiburgstrasse 18, 3010 Bern, Switzerland; marcel.arnold@insel.ch

Received 27 March 2006
Revised version received 22 June 2006
Accepted 23 June 2006
Published Online First 4 July 2006

Background: Headache or neck pain is a frequent symptom of spontaneous cervical artery dissection (sCAD).
Patients and methods: Patients were drawn from an ongoing hospital-based registry of consecutive cases diagnosed with sCAD. Only patients with isolated pain were included in this series. Pain topography, dynamics, severity and quality, imaging findings and outcome were analysed.
Results: 20 of 245 (8%) patients with sCAD presented with pain as the only symptom (mean (SD) age 39 (8) years; 14 (70%) women). Of them, 12 had vertebral artery dissection, 3 had internal carotid dissection and 5 had multiple dissections. The median delay from symptom onset to diagnosis was 7 days (range 4 h to 29 days). 6 patients presented with headache, 2 with neck pain and 12 with both. Onset of headache was progressive in 6, acute in 8 and thunderclap-type in 4 patients; neck pain was progressive in 7 and acute in 7. Headache was throbbing in 13 and constrictive in 5 patients; neck pain was throbbing in 4 and constrictive in 10. Pain was unilateral in 11 and bilateral in 9. Pain was different from earlier episodes in all but one case. All patients were pain free at 3 months.
Conclusion: Pain may be the only symptom in sCAD, even when multiple arteries are dissected. Pain topography, dynamics, quality and intensity were heterogeneous. Data from this study lend support to recommendations favouring imaging studies of the cervical arteries in patients with new-onset unexplained headache or neck pain.

255

Questions

- What percentage of CAD patients present to chiropractic without head/neck pain, signs or symptoms of neurologic deficits or connective tissue disorders?
- What risk factors or symptoms should we list on our intake forms that may provide insight into CAD?
- Are connective tissue disorder patients absolute contraindications to HVLA-SM of the cervical spine?

256

Opinions Related to Asymptomatic CADs

On Mon, Jul 25, 2022 at 12:37 PM Schneider, Michael Jacob <mjs5@pitt.edu> wrote:

> Hi Jim,
>
> No, I don't know of any reports of CAD cases in asymptomatic patients or those without connective tissue disorders.
> As we have discussed, it appears that almost every reported case of CAD involves a symptomatic patient who presents to a DC with suboccipital pain and an unusual headache.
> The DC does not recognize these symptoms as related to a possible dissection in progress and the ensuing manipulation may aggravate the pre-existing dissection.
>
> Regarding connective tissue disorders, this seems to be the underlying factor in most cases of younger patients who develop dissections.
>
> Mike

257

Opinions Related to Asymptomatic CADs



crisp4psp@gmail.com Mon, Jul 25, 7:30 AM (2 days ago)
to me

Jim,

Good question. I recall seeing one or more cases in the literature of patients who have had stroke post-manip without neck pain/ HA but I don't recall for sure. Certainly the overwhelming majority do have neck pain/HA. And most case reports are so poorly reported that it is always difficult to say. Certainly the majority of cases have no known connective tissue disorder or neurologic symptoms. But, again, the reports are usually poorly documented.

Take care!

Donald R. Murphy, DC, FRCC
Director of Primary Spine Care
Ortho Rhode Island

Clinical Assistant Professor, Dept of Family Medicine
Alpert Medical School of Brown University

258

Asymptomatic CAD Presentations are Rare

Commentary | Open Access | Published: 03 August 2010

Current understanding of the relationship between cervical manipulation and stroke: what does it mean for the chiropractic profession?

Donald R Murphy

Chiropractic & Osteopathy **18**, Article number: 22 (2010) | Cite this article
22k Accesses | **25** Citations | **11** Altmetric | Metrics

- Also, in 20% of cases of VADS [Review of the Lee paper "Three patients were asymptomatic **(6%)**, and neuroimaging was performed for unrelated reasons."] of their cohort the individual does not have neck pain or headache and in a very small percentage of patients vertebral artery dissection can occur in a person who has no symptoms of any kind [48].
  - [48] Lee VH, Brown RD, Mandrekar JN, Mokri B: Incidence and outcome of cervical artery dissection: a population-based study. Neurology. 2006, 67 (10): 1809-12.

259

Asymptomatic CAD Presentations are Rare

PMC Alt No PDF A Rare Case of Isolated, Spontaneous, and Asymptomatic Common ...
J Emerg Trauma Shock. 2021 Oct-Dec; 14(4): 240–242.

Journal of Emergencies, Trauma, and Shock
Wolters Kluwer -- Medknow Publications

A Rare Case of Isolated, Spontaneous, and Asymptomatic Common Carotid Artery Dissection

Iyad Farouji, Hossam Abed, [...], and Addi Suleiman

- Herein, we report a very unique case of isolated, spontaneous, and asymptomatic common carotid artery dissection.

260

Asymptomatic CAD Presentations are Rare

Neurology®
The most widely read and highly cited peer-reviewed neurology journal

Home Latest Articles Current Issue Past Issues Residents & Fellows

November 28, 2006; 67 (10) ARTICLES

Incidence and outcome of cervical artery dissection

A population-based study

Vivien H. Lee, Robert D. Brown, Jayawant N. Mandrekar, Bahram Mokri

First published November 27, 2006, DOI: https://doi.org/10.1212/01.wnl.0000244486.30455.71

- Three patients were asymptomatic (6%), and neuroimaging was performed for unrelated reasons.
- Three patients (6%) had known disorders of connective tissue and an additional three patients had a family history of connective tissue disorder in first-degree relatives.

From the Departments of Neurology (V.H.L., R.D.B., B.M.), and Biostatistics (J.N.M.), Mayo Clinic College of Medicine, Rochester, MN. Dr. Lee is currently with the Department of Neurology, Rush University Medical Center, Chicago, IL.

261

Asymptomatic CAD Presentations are Rare

Neurology®
The most widely read and highly cited peer-reviewed neurology journal

Home Latest Articles Current Issue Past Issues Residents & Fellows

November 28, 2006; 67 (10) ARTICLES

Incidence and outcome of cervical artery dissection

A population-based study

Vivien H. Lee, Robert D. Brown, Jayawant N. Mandrekar, Bahram Mokri

First published November 27, 2006, DOI: https://doi.org/10.1212/01.wnl.0000244486.30455.71

Table 2 *ICAD and VAD patients in Olmsted County, MN (1987–2003)*

	ICAD	VAD	CAD
Demographics			
Total patients	32 (67)	18 (38)	48
Mean age, y	47.0	43.4	45.8
Male	12 (38)	12 (67)	24 (50)
Female	20 (63)	6 (33)	24 (50)
Medical history			
Connective tissue disorder	3 (9)	0	3 (6)
Migraine	13 (41)	4 (22)	16 (33)
Hypertension	6 (19)	3 (17)	9 (19)
Smoker	11 (34)	4 (22)	14 (29)
Clinical symptoms			
Asymptomatic	1 (3)	2 (11)	3 (6)
Pain	25 (78)	15 (83)	38 (80)
Neck pain	6 (19)	7 (39)	13 (27)
HA	23 (72)	12 (67)	33 (69)
Horner syndrome	8 (25)	4 (22)	12 (25)
Cerebral ischemia (stroke or TIA)	19 (59)	14 (78)	32 (67)
TIA	9 (29)	2 (11)	11 (23)
Stroke	13 (41)	15 (83)	27 (56)

262

Chaibi and Russell's CAD Assessment Tool

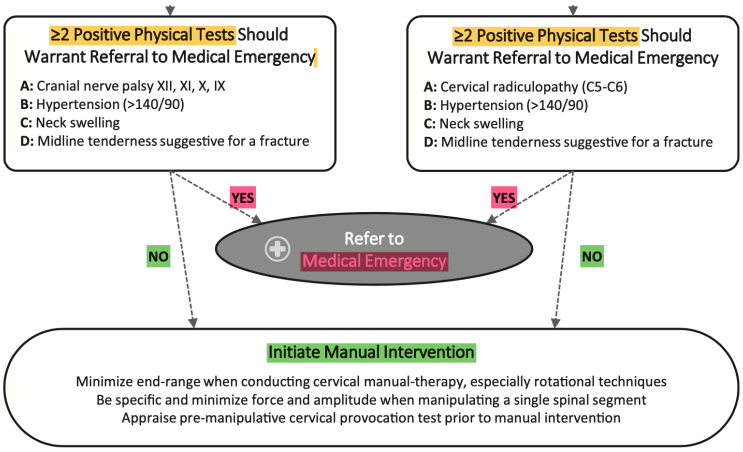

- **Exams:**
  - Neuro exam
  - Connective tissue / Joint Hypermobility Syndrome exam
  - Other Tests?:
    - ~~Provocative tests~~
- **Evidence?**
  - Lacking

Chaibi A, Russell BR. Annals of Medicine. 2019; 51 (2)118-127.

263

Thomas CeAD Assessment Tool



Clinical Neurology and Neurosurgery 247 (2024) 108627

Contents lists available at ScienceDirect

Clinical Neurology and Neurosurgery

journal homepage: www.elsevier.com/locate/clineuro

Validation of a diagnostic support tool for early recognition of cervical arterial dissection in primary care

L. Thomas [a,*], M. Fowler [a], L. Marsh [a], K. Chu [b], Claire Muller [c], A. Wong [c]

[a] School of Health and Rehabilitation Sciences, University of Queensland, Brisbane, Australia
[b] Department of Emergency Medicine, Royal Brisbane and Women's Hospital, Brisbane, Australia
[c] Department of Neurology, Royal Brisbane and Women's Hospital, Brisbane, Australia

ARTICLE INFO

Keywords:
Arterial dissection
Stroke
Headache
Neck pain
Referral and consultation
Diagnosis

ABSTRACT

Background: Cervical arterial dissection (CeAD) is a leading cause of stroke in young adults with an early presentation often mimicking musculoskeletal pain. Currently, no validated tests exist and CAD may be missed. A diagnostic support tool could help guide urgent referral for imaging, when in-emitive, or when safe to proceed with treatment, and ultimately help stroke prevention.
Objectives: To validate a 4-criteria diagnostic support tool for early recognition of CeAD in primary care, to refine tool descriptors as needed, and propose optimal cut-offs for clinical application.
Design: Prospective observational study
Method: Participants with radiologically confirmed CeAD and controls without CeAD were identified from adults >18 years presenting to a tertiary metropolitan hospital with initial diagnosis of headache or neck pain. All were scored with criteria out of7 (acute onset pain [2], recent trauma/infection [1], neurological features [2], age <55 years [2]). Diagnostic values were calculated to determine cut offs and the tool was refined based on the analysis.
Results: Thirty participants with CeAD and 201 controls with non-CeAD causes of headache and neck pain were included. The diagnostic support tool was an 'excellent' predictor of CeAD (AUC 0.85) but demonstrated poor specificity. Refining the tool to 'acute/sudden onset' [3], 'unusual/unfamiliar headache/neck pain' [1], recent trauma/infection [1] and neurological features ≥2 [3], scored out of 8, showed 100 % sensitivity and 79 % specificity to detect CeAD at a cut-off of 3/8 (AUC 0.87).
Conclusions: The refined tool shows acceptable clinical utility at a cut-off ≥3, where referral for vascular imaging is recommended. Further validation in Emergency and primary care is needed.

1. Introduction

Spontaneous Cervical Artery Dissection (CeAD), including dissection of the internal carotid artery (ICAD) or vertebral artery (VAD) is a leading cause of ischaemic stroke in young and middle-aged adults with an annual incidence of 2–3 cases per 100,000 [1–3]. However, this may be an underestimate of the true incidence of CeAD as patients with subtle and transient symptoms may go undiagnosed [4,5]. Incidental findings on imaging suggest CeAD may occur asymptomatically [6]. CeAD causing stroke is a rare but potentially catastrophic adverse event reported in association with cervical musculoskeletal therapies which is a major concern to practitioners, though correlation between exposure and outcome is questioned [6,7]. The clinical dilemma is the early presenting features of CeAD, typically headache and neck pain, may mimic migraine or a musculoskeletal presentation prior to overt neurological features arising days or weeks later [8]. There are two major concerns for practitioners, firstly misdiagnosis of an evolving dissection event delaying medical management to prevent stroke and secondly, that patients may seek musculoskeletal treatment of their neck pain or headache which could exacerbate an underlying dissection, risking potential ischaemic sequelae. There have been calls in the international community for research to direct practice [7,9,10].
Delays in diagnosis and misdiagnosis of CeAD in emergency departments have also been noted by Liberman et al. [11], affecting 1 in 30 cases, particularly when patients present with headache, highlighting the urgent need for diagnostic criteria to aid stroke prevention. Hashimoto et al. [12] proposed criteria for use in an emergency department including unilateral, worsening headache and no improvement with

* Correspondence to: School of Health and Rehabilitation Sciences, University of Queensland, Brisbane, Australia.
E-mail address: l.thomas2@uq.edu.au (L. Thomas).

https://doi.org/10.1016/j.clineuro.2024.108627
Received 7 August 2024; Received in revised form 1 November 2024; Accepted 2 November 2024
Available online 2 November 2024
0303-8467/© 2024 The Authors. Published by Elsevier B.V. This is an open access article under the CC BY license (http://creativecommons.org/licenses/by/4.0/).

- Spectrum bias from the ED setting
- Small case numbers
- No independent validation of the refined tool
- Moderate specificity and false positives
- Design and data quality

264

Snodgrass CeAD Assessment Tool



Snodgrass et al. Chiropractic & Manual Therapies (2026) 34:59
https://doi.org/10.1186/s12998-026-00670-3

Chiropractic & Manual Therapies

RESEARCH Open Access

Preliminary accuracy, inter- and intra-rater reliability of a 4-point cervical artery dissection diagnostic decision support tool in an ambulatory setting using real and simulated cases: a quality improvement project

Tyler H. Snodgrass, Zachary A. Cupler, Christopher J. Farrell and Lindsay R. Rae

Abstract

Background Cervical artery dissection (CeAD) is a rare but life-threatening condition that commonly presents with non-specific symptoms such as neck and head pain, complicating early recognition in ambulatory care settings. The CeAD diagnostic decision support tool (DDST) is a 4-item assessment designed to identify patients that should be referred for advanced diagnostic work-up to rule out CeAD; however, its utility in ambulatory settings has not been established.

Methods This quality improvement project aimed to evaluate the accuracy, inter-rater reliability, and intra-rater reliability of chiropractors applying the CeAD DDST using clinical vignettes simulating a typical ambulatory encounter before deploying the DDST broadly as part of the clinical workflow. Five experienced chiropractors assessed 40 standardized clinical vignettes. CeAD-positive cases (n = 10) were derived from published imaging-confirmed ambulatory care case reports. CeAD-negative cases (n = 30) were developed using generative artificial intelligence and refined by senior authors to reflect common conditions encountered in chiropractic practice. Raters independently assessed cases with the DDST (score 0–4), with a cutoff score of ≥ 3 recommending referral for advanced diagnostic work-up in two rounds, beginning November 11, 2025 and January 07, 2026, with a two-week capture period. Accuracy, inter-rater reliability, and intra-rater reliability were assessed.

Results Accuracy in identification ranged from 72.5% to 95.0% across raters and rounds. false positives and negatives were present across raters in both rounds, with false positives being more prevalent. Inter-rater reliability was moderate to substantial in both rounds (Round 1: κ = 0.609, 95% CI 0.432–0.806, Round 2: κ = 0.540, 95% CI 0.365–0.735). Intra-rater reliability ranged from moderate to almost perfect agreement (range 0.457–0.931).

*Correspondence:
Lindsay R. Rae
Lindsay.Rae@va.gov
Full list of author information is available at the end of the article

BMC

- This preliminary analysis of a validated CeAD DDST demonstrates that accuracy, inter-rater reliability, and intra-rater reliability of chiropractors utilizing the tool in a simulated ambulatory setting may not provide clinical utility at this time.
- This DDST may be useful in an emergency department setting given it was developed with this data, but implementation into the clinical workflow in an ambulatory setting is not currently recommended for the outpatient ambulatory clinic given the wide variability in end user implementation and presence of false negatives.
- Further refinement and testing should be completed prior to introduction into the clinical workflow.

265

CAD Examination

Cervical Artery Dissection: The Elusive Diagnosis

APR 14TH, 2020 JOHN RIGGINS JR CATEGORIES: PRACTICE UPDATES

Authors: John Riggins Jr, MD (EM Resident Physician, SUNY Downstate/Kings County Hospital) and Richard Sinert, DO (Professor of Emergency Medicine, SUNY Downstate/Kings County Hospital) // Reviewed by: Alex Koyfman, MD (@EMHighAK) and Brit Long, MD (@long_brit)

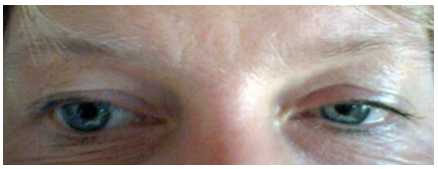

- **Physical Exam:**
  - Look for signs of trauma to neck (ecchymosis, bruising, crepitus) and listen for carotid bruits indicating a disruption in the blood flow of a vessel.
  - Look for a partial's Horner syndrome, evaluate for constriction of the pupils (miosis) and ipsilateral drooping of the eyelid (ptosis).
  - Palpation of the neck, around the bilateral temporal regions or in the occiput region might elicit pain in some patients presenting with CAD.
  - Patients can also present with tongue weakness and dysgeusia resulting from ischemia of the hypoglossal nerve, which is the most common cranial nerve affected.
  - In some cases, patients will present with symptoms of brain ischemia that can include dysphagia, dysarthria, and hemiplegia
  - Patients can also experience signs of optic nerve ischemia which can lead to amaurosis fugax and other visual disturbances when a dissection occurs near the carotid siphon.
  - Weakness and paresthesias.
  - Head, facial and neck pain were seen in up 74% of patients with symptomatic cervical artery dissection.

http://www.emdocs.net/cervical-artery-dissection-the-elusive-diagnosis/

266

VBI Tests?

Musculoskeletal Science and Practice
Volume 49, October 2020, 102181



Professional issue

Yes, we should abandon pre-treatment positional testing of the cervical spine

Nathan Hutting [a], Hendrikus Antonius "Rik" Kranenburg [b], Roger Kerry [c]

[a] Department of Occupation and Health, School of Organisation and Development, HAN University of Applied Sciences, Nijmegen, the Netherlands
[b] Research Group on Healthy Aging, Allied Health Care and Nursing, Hanze University of Applied Sciences, Groningen, the Netherlands
[c] Division of Physiotherapy and Rehabilitation Sciences, University of Nottingham, Nottingham, UK

- VBI tests are not able to predict major adverse events and seem not to have any added value to the patient interview with regard to detecting VBI or another vascular pathology.
- Furthermore, a negative VBI test can be wrongly interpreted as 'safe to manipulate'.
- Therefore, the use of VBI tests cannot be recommended and should be abandoned.

267

MAYO CLINIC

CONCISE REVIEW

Craniocervical Artery Dissections: A Concise Review for Clinicians

Check for updates

Zafer Keser, MD; James F. Meschia, MD; and Giuseppe Lanzino, MD

- Interestingly, many patients with CAD have isolated mild connective tissue abnormalities, such as:
  - joint hypermobility,
  - easy bruising,
  - and poor wound healing,

  suggesting that CAD may be another expression of a yet undefined connective tissue disorder. 9

- Giossi A, Ritelli M, Costa P, et al. Connective tissue anomalies in patients with spontaneous cervical artery dissection. Neurology. 2014;83(22):2032-2037.

Mayo Clin Proc. ■ April 2022;97(4):777-783 ■ https://doi.org/10.1016/j.mayocp.2022.02.007
www.mayoclinicproceedings.org ■ © 2022 Mayo Foundation for Medical Education and Research

268

Connective Tissue / Joint Hypermobility Syndrome Examination

frontiers in Neurology

PERSPECTIVE
published: 31 May 2021
doi: 10.3389/fneur.2021.663830

Cervical Artery Dissection and Sports

Stefan T. Engelter[1,2], Christopher Traenka[1,2], Caspar Grond-Ginsbach[2,3], Tobias Brandt[4], Maani Hakimi[5], Bradford B. Worrall[6], Stephanie Debette[7,8], Alessandro Pezzini[9], Didier Leys[10], Turgut Tatlisumak[11], Christian H. Nolte[12] and Philippe Lyrer[1]*

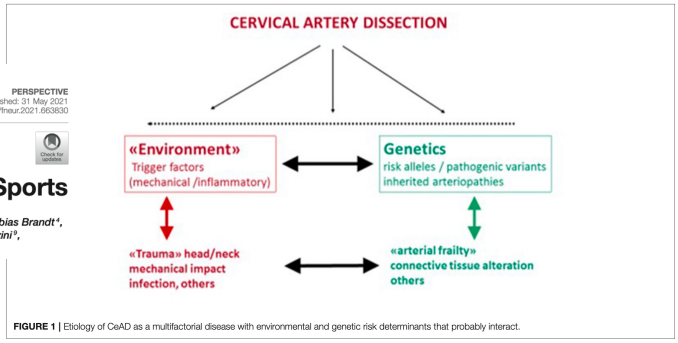

FIGURE 1 | Etiology of CeAD as a multifactorial disease with environmental and genetic risk determinants that probably interact.

269

Connective Tissue / Joint Hypermobility Syndrome Examination

frontiers in Neurology

PERSPECTIVE
published: 31 May 2021
doi: 10.3389/fneur.2021.663830

Cervical Artery Dissection and Sports

Stefan T. Engelter[1,2], Christopher Traenka[1,2], Caspar Grond-Ginsbach[2,3], Tobias Brandt[4], Maani Hakimi[5], Bradford B. Worrall[6], Stephanie Debette[7,8], Alessandro Pezzini[9], Didier Leys[10], Turgut Tatlisumak[11], Christian H. Nolte[12] and Philippe Lyrer[1]*

- However, mild clinical signs of a connective tissue weakness, including slight joint hypermobility, thin and translucent skin, or easy bruising, are common and associated with CeAD (25, 26).

- 25. Grond-Ginsbach C, Debette S. The association of connective tissue disorders with cervical artery dissections. *Curr Mol Med.* (2009) 9:210–4. doi: 10.2174/156652409787581547
- 26. Giossi A, Ritelli M, Costa P, Morotti A, Poli L, Del Zotto E, et al. Connective tissue anomalies in patients with spontaneous cervical artery dissection. *Neurology.* (2014) 83:2032–7. doi: 10.1212/WNL.0000000000001030

270

Connective Tissue / Joint Hypermobility Syndrome Examination

American Journal of Medical Genetics Part C (Seminars in Medical Genetics) 169C:6–22 (2015)

ARTICLE

Differential Diagnosis and Diagnostic Flow Chart of Joint Hypermobility Syndrome/Ehlers–Danlos Syndrome Hypermobility Type Compared to Other Heritable Connective Tissue Disorders

MARINA COLOMBI, CHIARA DORDONI, NICOLA CHIARELLI, AND MARCO RITELLI

TABLE I. The Villefranche Criteria for the Historical EDS Types [Beighton et al., 1998] and the Underlying Molecular Defect

EDS type	Major criteria	Minor criteria	Gene(s)
Classic AD OMIM #130000, #130010	**Skin hyperextensibility** **Widened atrophic scars** JHM	Smooth, velvety skin **Molluscoid pseudotumors** Subcutaneous spheroids Complications of JHM (e.g., sprains, dislocations/subluxations, *pes planus*) Muscle hypotonia, delayed gross motor development Easy bruising Manifestations of tissue fragility (e.g., hiatal hernia, anal prolapse in childhood, cervical insufficiency) Surgical complications (postoperative hernias) Positive family history	*COL5A1* *COL5A2*
Hypermobility AD OMIM #130020	Skin involvement (hyperextensibility and/or smooth, velvety skin) Generalized JHM	Recurring joint dislocations **Chronic joint/limb pain** Positive family history	?
Vascular AD OMIM #130050	Thin, translucent skin **Arterial/intestinal/uterine fragility or rupture** **Extensive bruising** Characteristic facial appearance	**Acrogeria** Hypermobility of small joints Tendon and muscle rupture *Talipes equinovarus* (clubfoot) Early-onset varicose veins Arteriovenous, carotid-cavernous *sinus fistula* **Pneumothorax/pneumohemothorax** Gingival recession Positive family history, **sudden death in (a) close relative(s)**	*COL3A1*
Kyphoscoliotic AR OMIM #225400	Generalized JHM Severe muscle hypotonia at birth **Scoliosis at birth, progressive** **Scleral fragility and rupture of the ocular globe**	Tissue fragility, including atrophic scars Easy bruising Arterial rupture *Marfanoid habitus* **Microcornea** Radiologically considerable osteopenia Family history, i.e., affected sibs	*PLOD1*
Arthrochalasia AD OMIM #130060	Severe generalized JHM, with recurrent subluxations **Congenital bilateral hip dislocation**	Skin hyperextensibility Tissue fragility, including atrophic scars Easy bruising Muscle hypotonia Kyphoscoliosis Radiologically mild osteopenia	*COL1A1* *COL1A2*

271

The Beighton Score

Rheumatology International (2021) 41:1707–1716
https://doi.org/10.1007/s00296-021-04832-4

Rheumatology INTERNATIONAL

REVIEW

The Beighton Score as a measure of generalised joint hypermobility

Sabeeha Malek[1] · Emma J. Reinhold[2] · Gemma S. Pearce[3]

Received: 4 February 2021 / Accepted: 2 March 2021 / Published online: 18 March 2021
© The Author(s) 2021

- The evidence presented here brings into question the validity of the BS as a direct and indirect indicator of GJH and disputes its continued use as a diagnostic tool.
- The BS should be used as intended, i.e. as an initial screening method, after which other notable joints, for example, the shoulder, hips, ankles, and remaining digits, could be examined until the clinician is satisfied that no evidence of systemic JH conclusively exists, nor any associated syndromic features, before excluding Heritable Connective Tissue Disorders (HCTD) as a diagnosis.

272

The Beighton Score

Review

Interrater and Intrarater Reliability of the Beighton Score

A Systematic Review

Lauren N. Bockhorn,* MD, Angelina M. Vera,* MD, David Dong,* BS, Domenica A. Delgado,* MBA, Kevin E. Varner,* MD, and Joshua D. Harris,*† MD

Investigation performed at Houston Methodist Orthopedics and Sports Medicine, Houston, Texas, USA

The Orthopaedic Journal of Sports Medicine, 9(1), 2325967120968099
DOI: 10.1177/2325967120968099

- The Beighton score is a highly reliable clinical tool that shows substantial to excellent inter- and intrarater reliability when used by raters of variable backgrounds and experience levels.

273

Connective Tissue / Joint Hypermobility Syndrome Examination

American Journal of Medical Genetics Part C (Seminars in Medical Genetics) 169C:6–22 (2015)

ARTICLE

Differential Diagnosis and Diagnostic Flow Chart of Joint Hypermobility Syndrome/Ehlers–Danlos Syndrome Hypermobility Type Compared to Other Heritable Connective Tissue Disorders

MARINA COLOMBI, CHIARA DORDONI, NICOLA CHIARELLI, AND MARCO RITELLI

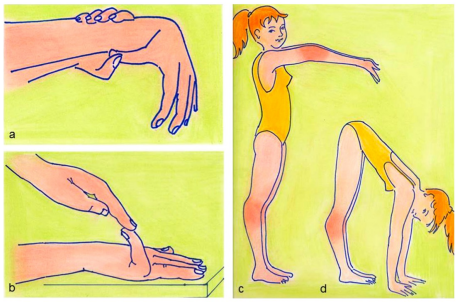

Figure 1. Assessment of joint hypermobility with the Beighton score: (a) passive dorsiflexion of the fifth metacarpophalangeal joint to ≥90°, (b) opposition of the thumb to the volar aspect of the ipsilateral forearm, (c) hyperextension of the elbow to ≥10°, and hyperextension of the knee to ≥10°, d) placement of hands flat on the floor without bending the knees (Figure drawn by L. Manenti). The Beighton score is incorporated into the diagnostic criteria for EDSs, MFS, LDS, ATS, and OI.

274

Connective Tissue / Joint Hypermobility Syndrome Examination



Brighton criteria for JHS

Major criteria

Beighton score ≥4/9

Arthralgia for >3 months in >4 joints

Minor criteria

Beighton score 1–3

Arthralgia in 1–3 joints

History of joint dislocations

Soft tissue lesions >3

Marfan-like *habitus*

Skin *striae*, hyperextensibility, or scarring

Downslanting palpebral fissures, lid laxity, myopia

History of varicose veins, hernia, visceral prolapse

Agreement: both major, or 1 major and 2 minor, or 4 minor criteria. Criteria major 1 and minor 1 are mutually exclusive as/are major 2 and minor 2.

Source: Grahame et al., [2000] and subsequent modifications (see, for example, Tinkle et al., [2009]).

275

Connective Tissue / Joint Hypermobility Syndrome Examination

American Journal of Medical Genetics Part C (Seminars in Medical Genetics) 169C:6–22 (2015)

ARTICLE

Differential Diagnosis and Diagnostic Flow Chart of Joint Hypermobility Syndrome/Ehlers–Danlos Syndrome Hypermobility Type Compared to Other Heritable Connective Tissue Disorders

MARINA COLOMBI, CHIARA DORDONI, NICOLA CHIARELLI, AND MARCO RITELLI

5-point questionnaire for JHM

1. Could you ever place your hands flat on the floor without bending your knees?
2. Could you ever bend your thumb to touch your forearm?
3. As a child did you amuse your friends by contorting your body into strange shapes OR could you do the splits?
4. As a child or teenager did your shoulder or kneecap dislocate on more than one occasion?
5. As a child or teenager did you consider yourself double-jointed?

Agreement: affirmative answer for two or more questions.

Source: modified from Hakim and Grahame [2003].

276

Connective Tissue / Joint Hypermobility Syndrome Examination

American Journal of Medical Genetics Part C (Seminars in Medical Genetics) 169C:6–22 (2015)

ARTICLE

Differential Diagnosis and Diagnostic Flow Chart of Joint Hypermobility Syndrome/Ehlers–Danlos Syndrome Hypermobility Type Compared to Other Heritable Connective Tissue Disorders

MARINA COLOMBI, CHIARA DORDONI, NICOLA CHIARELLI, AND MARCO RITELLI

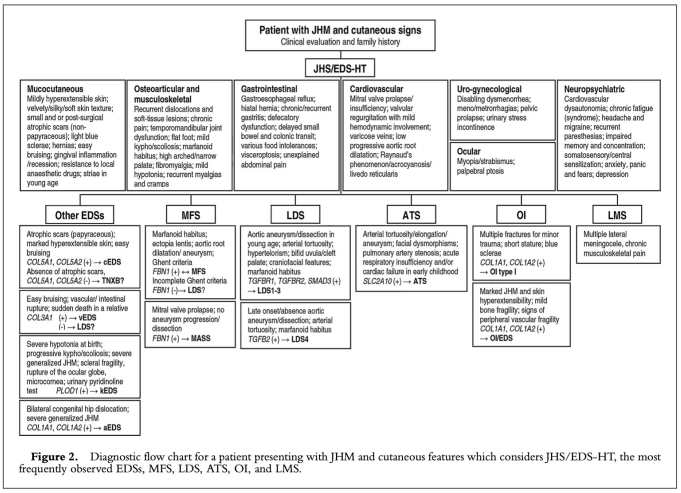

Figure 2. Diagnostic flow chart for a patient presenting with JHM and cutaneous features which considers JHS/EDS-HT, the most frequently observed EDSs, MFS, LDS, ATS, OI, and LMS.

277

Diligence to Identify a Developing CAD...

- Patients may present to physicians with developing CADs.
- While rare and difficult to diagnose the developing CAD, it is vitally important to exert clinical diligence.
- The result of an undiagnosed CAD and resultant stroke can be catastrophic:
  - Death
  - Infarcts
  - Paralysis
  - Locked-in Syndrome

278

POSTGRADDC
EVIDENCE BASED, CLINICALLY INTUITIVE CE

Grand Rounds:
Neurologic Deficits Due to VAD

Presented by James Demetrious, DC, DABCO

www.PostGradDC.com

279

An Unpredictable and Spontaneous Event…



- **Listen to how he describes the onset, symptoms and neurologic compromise due to this acute CAD.**

280

To DX the Developing CAD, We Must Consider…



281

To DX the Developing CAD, We Must Consider…

Initial Stroke and TIA Assessment

NIHSS item	Initial Assessment: What to Do	Findings and Scoring
1a. Level of consciousness	Assess alertness and responsiveness to verbal or physical stimulation.	**0:** Alert. **1:** Arouses with minor stimulation. **2:** Requires repeated or strong stimulation. **3:** Only reflex responses or completely unresponsive.
1b. Orientation questions	Ask the patient's **age and current month**. Score the initial answers without cues.	**0:** Both correct. **1:** One correct. **2:** Neither correct. Special rules apply when speech is prevented by a non-aphasic barrier.
1c. Ability to follow commands	Ask the patient to **open and close the eyes**, then **grip and release the nonparetic hand**. Demonstrate if necessary.	**0:** Both tasks performed. **1:** One task performed. **2:** Neither task performed. Credit an unmistakable attempt limited by weakness.
2. Horizontal gaze	Assess horizontal eye movements and identify gaze restriction or forced deviation.	**0:** Normal. **1:** Partial gaze palsy. **2:** Forced deviation or total gaze paresis not overcome by the prescribed reflex maneuver.
3. Visual fields	Test upper and lower visual fields by confrontation using finger counting or visual threat. Include simultaneous bilateral stimulation.	**0:** No loss. **1:** Partial hemianopia, including quadrantanopia. **2:** Complete hemianopia. **3:** Bilateral hemianopia/blindness. Follow the source's rules for extinction and preexisting blindness.
4. Facial movement	Ask the patient to show teeth, raise eyebrows, and close the eyes. Assess symmetry.	**0:** Normal. **1:** Minor weakness or asymmetric smile. **2:** Total or near-total lower facial paralysis. **3:** Complete upper and lower facial paralysis on one or both sides.
5a/5b. Arm strength—each side	Test each arm separately, palms down: **90° sitting or 45° supine**, held for **10 seconds**. Begin with the nonparetic arm.	**0:** No drift. **1:** Drifts but does not reach support. **2:** Falls to support with some effort against gravity. **3:** No effort against gravity. **4:** No movement. **Record left and right separately.**
6a/6b. Leg strength—each side	With the patient supine, raise each leg to **30°** and assess maintenance for **5 seconds**. Begin with the nonparetic leg.	**0:** No drift. **1:** Drifts without reaching the bed. **2:** Falls to the bed with some effort against gravity. **3:** Falls immediately without effort against gravity. **4:** No movement. **Record left and right separately.**
7. Limb coordination	Perform **finger-nose-finger and heel–shin testing bilaterally**, with eyes open. Score ataxia only when disproportionate to weakness.	**0:** Absent. **1:** Present in one limb. **2:** Present in two limbs. Under NIHSS rules, inability to perform because of paralysis or failure to understand does not itself earn ataxia points.
8. Sensation	Compare pinprick sensation across the face, arms, legs, and other areas as needed. Assess responses in patients with limited communication.	**0:** Normal. **1:** Mild-to-moderate loss; touch remains perceived. **2:** Severe or total loss. Score sensory loss attributable to stroke; apply the document's coma and brainstem-stroke rules.
9. Language—aphasia	Use the supplied picture, naming sheet, and sentences. Assess comprehension throughout the examination.	**0:** Normal. **1:** Mild-to-moderate aphasia. **2:** Severe aphasia with markedly limited communication. **3:** Mute/global aphasia with no usable speech or comprehension.
10. Articulation—dysarthria	Ask the patient to read or repeat the document's word list. Assess clarity of spontaneous speech when severe aphasia limits testing.	**0:** Normal. **1:** Slurred but understandable speech. **2:** Unintelligible speech or mute/anarthric. **UN:** Intubation or another physical barrier prevents testing; document why.
11. Extinction and inattention	Assess awareness of both sides of the body and space. Use bilateral simultaneous visual or tactile stimulation and observations from earlier testing.	**0:** No abnormality. **1:** Inattention or extinction in one sensory modality. **2:** Profound neglect or extinction in more than one modality. This item is never scored untestable.
Total and documentation	Sum numeric scores, including **both arms and both legs**. Record assessment time, side of deficits, and testing limitations.	**NIHSS range: 0–42** when all items are numerically scored. Use **UN** only where permitted; document the reason rather than converting it to zero.

282

CAD...An Extremely Difficult DDX

Cervical Artery Dissection: The Elusive Diagnosis

APR 14TH, 2020 JOHN RIGGINS JR CATEGORIES: PRACTICE UPDATES

Authors: John Riggins Jr, MD (EM Resident Physician, SUNY Downstate/Kings County Hospital) and Richard Sinert, DO (Professor of Emergency Medicine, SUNY Downstate/Kings County Hospital) // Reviewed by: Alex Koyfman, MD (@EMHighAK) and Brit Long, MD (@long_brit)

- **Pearls/Pitfalls:**
  - CAD is a disease process with multiple risk factors. Make sure to keep this diagnosis on your differential for any patient with severe neck pain, new-onset headache and/or neurological abnormalities on exam. Pain may be the only presenting symptom for a cervical artery dissection.

https://www.emdocs.net/cervical-artery-dissection-the-elusive-diagnosis/

283

Epidemiology of sCeAD

- **Clinical manifestations of the 123 patients:**
  - Most patients presented with **headache** (49.6%) and **neck pain** (29.3%).
  - Ischemic stroke occurred at presentation in 45 patients (36.6%), with **infarction** confirmed on imaging in 44, and diagnosed based on clinical findings alone in 1.
  - **15.5% were asymptomatic** from a neurological standpoint or presented with nonspecific symptoms considered to likely not be related to the CeAD.

Table 1. Demographics and Clinical Presentation of Patients With Cervical Artery Dissection

	ICAD (63)	VAD (54)	Total CeAD (123)
Female sex	28 (44.4)	33 (61.1)	63 (51.2)
White race	57 (90.5)	48 (88.9)	111 (90.2)
Hispanic ethnicity	1 (1.6)	0 (0)	1 (0.8)
Presentation			
Found Incidentally	12 (19.1)	4 (7.4)	19 (15.5)
Neck pain	15 (23.8)	19 (35.2)	36 (29.3)
Headache	31 (49.2)	28 (51.9)	61 (49.6)
Horner syndrome	18 (28.6)	0 (0)	18 (14.6)
Pulsatile tinnitus	7 (11.1)	4 (7.4)	11 (8.9)
Cerebral infarction (clinical or imaging)	20 (31.8)	24 (44.4)	45 (36.6)
Transient ischemic attack	7 (11.1)	10 (18.5)	18 (14.6)
Comorbidities			
Hypertension	24 (38.1)	14 (25.9)	44 (35.8)
Hyperlipidemia	19 (30.2)	20 (37.0)	45 (36.6)
Diabetes	5 (7.9)	4 (7.4)	11 (8.9)
Migraine	22 (34.9)	20 (37.0)	46 (37.4)
Former smoking	12 (19.1)	13 (24.1)	30 (24.4)
Active smoking	9 (14.3)	8 (14.8)	19 (15.5)
Family history of dissection	3 (4.8)	0 (0)	3 (2.4)

Values are expressed as n (%). Total CeAD includes patients with ICAD, VAD, and common carotid artery dissection, as well as the 2 patients who presented with both ICAD and VAD. CeAD indicates cervical artery dissection; ICAD, internal carotid artery dissection; and VAD, vertebral artery dissection.

Stroke. 2024;55:670–677. DOI: 10.1161/STROKEAHA.123.043647

284

CAD...An Extremely Difficult DDX

Stroke

CLINICAL AND POPULATION SCIENCES

Epidemiology of Spontaneous Cervical Artery Dissection: Population-Based Study

Kim J. Griffin, MD; William S. Harmsen, MS; Jay Mandrekar, PhD; Robert D. Brown Jr, MD; Zafer Keser, MD

- **Clinical manifestations of the 123 patients:**
  - **15.5% were asymptomatic** from a neurological standpoint or presented with nonspecific symptoms considered to likely not be related to the CeAD.

Stroke. 2024;55:670–677. DOI: 10.1161/STROKEAHA.123.043647

285

Cureus
Open Access Review Article
DOI: 10.7759/cureus.28068

Vertebral Artery Stenosis: A Narrative Review

Venkata Sathya Burle [1], Amelia Panjwani [2], Kesava Mandalaneni [3], Sunitha Kollu [4], Vasavi Rakesh Gorantla [5]

1. Anatomical Sciences, St. George's University School of Medicine, Clarksville, USA 2. Anatomical Sciences, St. George's University School of Medicine, Whitby, CAN 3. Neuroscience, St. George's University School of Medicine, St. George's, GRD 4. Prosthodontics, Mamata Dental College, Khammam, IND 5. Anatomical Sciences, St. George's University School of Medicine, St. George's, GRD

Corresponding author: Vasavi Rakesh Gorantla, gorantla55@gmail.com

Review began 08/08/2022
Review ended 08/12/2022
Published 08/16/2022

© **Copyright** 2022
Burle et al. This is an open access article distributed under the terms of the Creative Commons Attribution License CC-BY 4.0., which permits unrestricted use, distribution, and reproduction in any medium, provided the original author and source are credited.

Clinical manifestations

- Stenosis or occlusion of the vertebral artery unilaterally or bilaterally causes decreased artery perfusion and can result in several symptoms of a posterior circulation transient ischemic attack, such as:
  - vertigo,
  - ataxia,
  - diplopia,
  - disturbance of speech,
  - and bilateral hemianopia [37,38].

286

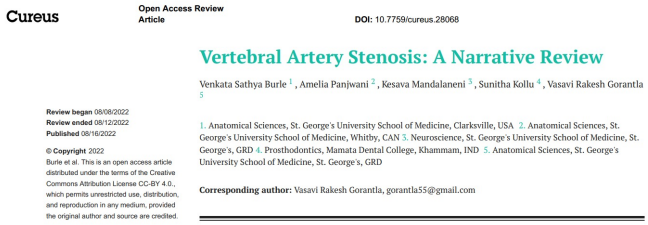

Cureus

Open Access Review Article

DOI: 10.7759/cureus.28068

Vertebral Artery Stenosis: A Narrative Review

Venkata Sathya Burle [1], Amelia Panjwani [2], Kesava Mandalaneni [3], Sunitha Kollu [4], Vasavi Rakesh Gorantla [5]

1. Anatomical Sciences, St. George's University School of Medicine, Clarksville, USA 2. Anatomical Sciences, St. George's University School of Medicine, Whitby, CAN 3. Neuroscience, St. George's University School of Medicine, St. George's, GRD 4. Prosthodontics, Mamata Dental College, Khammam, IND 5. Anatomical Sciences, St. George's University School of Medicine, St. George's, GRD

Corresponding author: Vasavi Rakesh Gorantla, gorantla55@gmail.com

Review began 08/08/2022
Review ended 08/12/2022
Published 08/16/2022

© **Copyright** 2022
Burle et al. This is an open access article distributed under the terms of the Creative Commons Attribution License CC-BY 4.0., which permits unrestricted use, distribution, and reproduction in any medium, provided the original author and source are credited.

- Vertebral artery stenosis can also result in:
  - recurring
  - syncope,
  - headaches,
  - recurrent stroke,
  - palsy of cranial nerves,
  - change in consciousness,
  - altered function of the sensory and pyramidal tracts,
  - cerebellar infarcts,
  - and tinnitus [8,24,27,34].

287

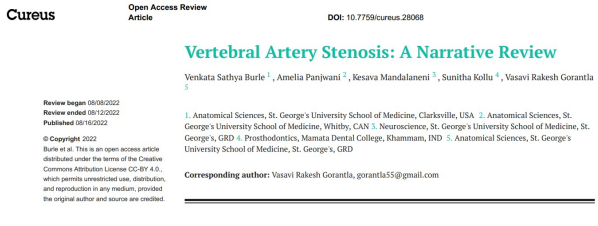

Cureus

Open Access Review Article

DOI: 10.7759/cureus.28068

Vertebral Artery Stenosis: A Narrative Review

Venkata Sathya Burle [1], Amelia Panjwani [2], Kesava Mandalaneni [3], Sunitha Kollu [4], Vasavi Rakesh Gorantla [5]

1. Anatomical Sciences, St. George's University School of Medicine, Clarksville, USA 2. Anatomical Sciences, St. George's University School of Medicine, Whitby, CAN 3. Neuroscience, St. George's University School of Medicine, St. George's, GRD 4. Prosthodontics, Mamata Dental College, Khammam, IND 5. Anatomical Sciences, St. George's University School of Medicine, St. George's, GRD

Corresponding author: Vasavi Rakesh Gorantla, gorantla55@gmail.com

Review began 08/08/2022
Review ended 08/12/2022
Published 08/16/2022

© **Copyright** 2022
Burle et al. This is an open access article distributed under the terms of the Creative Commons Attribution License CC-BY 4.0., which permits unrestricted use, distribution, and reproduction in any medium, provided the original author and source are credited.

- Vertebral artery stenosis can also result in decreased perfusion to the basilar artery and cause several symptoms, including:
  - vertigo,
  - dizziness,
  - diplopia,
  - ataxia,
  - dysarthria,
  - nausea,
  - nystagmus,
  - drop attacks,
  - loss of consciousness,
  - motor symptoms,
  - sensory symptoms such as numbness,
  - and an increased risk of experiencing strokes or transient ischemic attacks [6,16,30,32,39].
  - These symptoms are typically observed when there is stenosis or occlusion of both vertebral arteries [16].

288

CAD...An Extremely Difficult DDX

audiology research

MDPI

Review

Bedside Testing in Acute Vestibular Syndrome—Evaluating HINTS Plus and Beyond—A Critical Review

Alexander A. Tarnutzer [1,2,*] and Jonathan A. Edlow [3,4]

[1] Department of Neurology, Cantonal Hospital of Baden, 5404 Baden, Switzerland
[2] Faculty of Medicine, University of Zurich, 8006 Zurich, Switzerland
[3] Emergency Medicine, Beth Israel Deaconess Medical Center, Boston, MA 02215, USA; jedlow@bidmc.harvard.edu
[4] Emergency Medicine, Harvard Medical School, Boston, MA 02115, USA
* Correspondence: alexander.tarnutzer@access.uzh.ch

- The three-component bedside **HINTS** (**H**ead-**I**mpulse, **N**ystagmus, and **T**est of **S**kew) can accurately identify central causes (mostly ischemic stroke) in AVS patients [19].
- In the hands of a trained oto-neurologist, HINTS was associated with a 100% sensitivity and 96% specificity for detecting a stroke [19].
- Importantly, the presence of one out of these three signs was sufficient to suspect a central cause.

CAD...An Extremely Difficult DDX

audiology research

MDPI

Review

Bedside Testing in Acute Vestibular Syndrome—Evaluating HINTS Plus and Beyond—A Critical Review

Alexander A. Tarnutzer [1,2,*] and Jonathan A. Edlow [3,4]

[1] Department of Neurology, Cantonal Hospital of Baden, 5404 Baden, Switzerland
[2] Faculty of Medicine, University of Zurich, 8006 Zurich, Switzerland
[3] Emergency Medicine, Beth Israel Deaconess Medical Center, Boston, MA 02215, USA; jedlow@bidmc.harvard.edu
[4] Emergency Medicine, Harvard Medical School, Boston, MA 02115, USA
* Correspondence: alexander.tarnutzer@access.uzh.ch

Table 2. H.I.N.T.S. plus bedside testing battery * (modified after [36]).

Test Performed	Property Evaluated	How to Perform This Test	Pointing to a Peripheral Cause	Pointing to a Central Cause	Comments
Horizontal Head-Impulse test (HIT)	Vestibulo-ocular reflex (VOR)	Fast, low amplitude (10–15°) head rotations to the left/right while the patient is looking at a fixed target in space (e.g., the examiner's nose)	Delayed to one side, pathological catch-up saccade	Normal HIT.	Note that central lesions involving the VOR (e.g., lesions in the root-entry zone or of the vestibular nuclei) may show a "pseudo-peripheral pattern"
Testing for Nystagmus	Eccentric gaze-holding on lateral gaze	Fixation of an object (e.g., the tip of a pen) during lateral (eccentric) gaze (~20 to 30°) for at least 5 s.	Stable eccentric gaze-holding	Deficient eccentric gaze-holding with centripetal drift and centrifugal nystagmus (i.e., left-beating on left-gaze and right-beating on right-gaze).	Spontaneous, predominantly horizontal nystagmus (i.e., primary gaze nystagmus) can be found in both peripheral and central causes and thus allows no differentiation.
Alternating cover test ("Test of Skew")	Vertical alignment of the eyes	Rapid covering then uncovering one eye after the other while the patient is looking at a fixed target in space (e.g., the examiner's nose). The examiner should focus on only one eye.	No vertical deviation of the eyes	Vertical realignment of the uncovered eye (one eye goes up while the other eye goes down). This is why it does not matter which eye the examiner focuses on.	Note that rarely a vertical skew can also be observed in peripheral-vestibular deficits, but is usually of smaller amplitude and short-lived.
New-onset unilateral hearing loss (fourth sign—"plus sign")	Hearing	Finger rub on each side	Normal hearing	Hearing loss on the side with the abnormal head-impulse test	Hearing may also be compromised in inner ear disorders such as labyrinthitis or complicated otitis media, emphasizing the need for a dedicated examination of the ear.

* Teaching videos can be found under: http://novel.utah.edu/Newman-Toker/collection.php (accessed on 15 August 2023).

CAD...An Extremely Difficult DDX

Sahu, *et al.*: Beside examination of vertigo

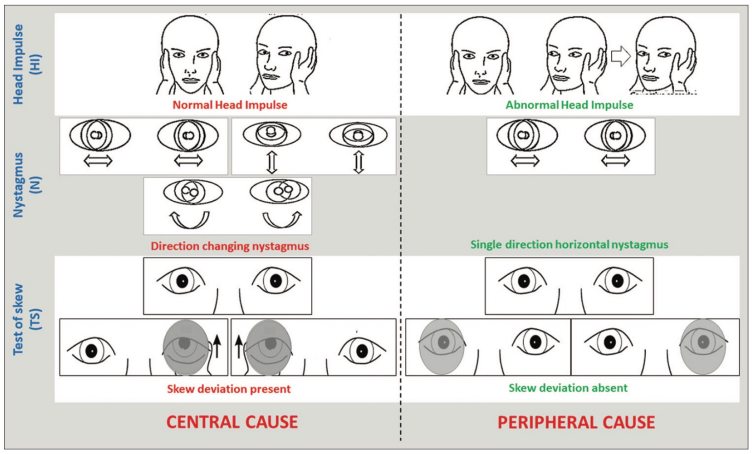

291

CAD...An Extremely Difficult DDX

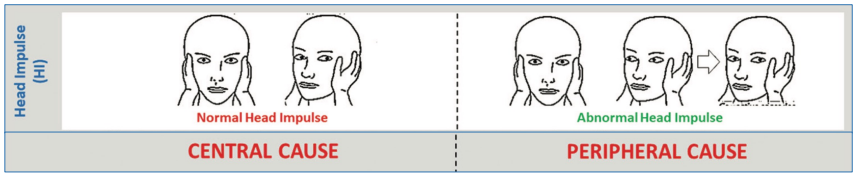

Contraindicated in developing CADs or patients at risk for thromboembolism?

- **HI-**
  - During the head impulse test (HI), the patient sits opposite the examiner and fixes their gaze on the examiner's nose.
  - The examiner then moves the head in one direction, followed by a move to the center and another move in the opposite direction. The head turn should be rapid from an eccentric (lateral) position back to the center (midline) with an excursion angle of 10°.
  - The examiner looks for any quick eye movement sign, a so-called corrective saccade.
  - The absence of saccadic corrections points towards a central cause, whereas, on the contrary, the presence of saccades is suggestive of a peripheral cause.

292

CAD...An Extremely Difficult DDX

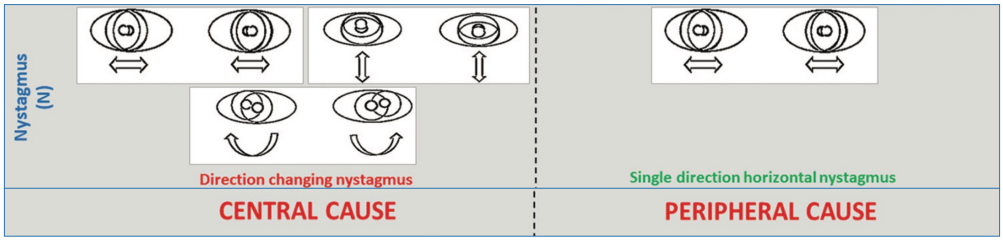

- **N -**
  - For testing nystagmus (N), the patient is asked to look to the left, right, and center position.
  - The direction-changing nystagmus or vertical nystagmus is suggestive of central causes of vertigo, whereas, on the contrary, single directional horizontal nystagmus is suggestive of a peripheral cause.

293

CAD...An Extremely Difficult DDX

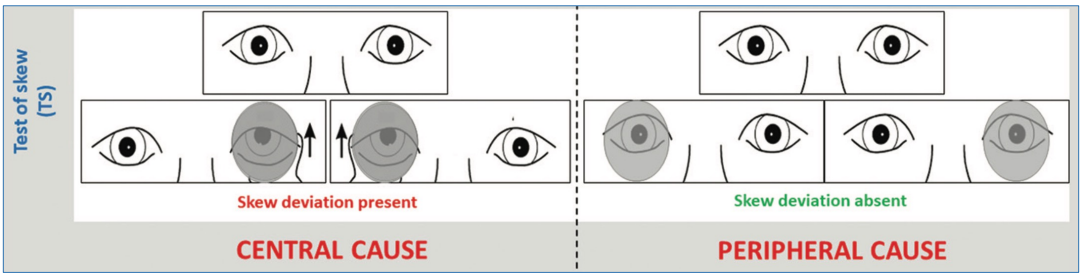

- **TS -**
  - In the test of skew (TS), the eyes of the patient are fixed on a distant target. The eyes of the patient are covered and uncovered in a slow alternating manner.
  - A vertical skew deviation is seen in central causes of vertigo, whereas the absence of any skew deviation suggests a peripheral cause.

294

CAD…An Extremely Difficult DDX

Quimby et al. Journal of Otolaryngology - Head and Neck Surgery (2018) 47:54
https://doi.org/10.1186/s40463-018-0305-8

Journal of Otolaryngology - Head & Neck Surgery

ORIGINAL RESEARCH ARTICLE Open Access

Usage of the HINTS exam and neuroimaging in the assessment of peripheral vertigo in the emergency department

Alexandra E. Quimby[1*], Edmund S. H. Kwok[2], Daniel Lelli[3], Peter Johns[4] and Darren Tse[5]

?

cranial ionizing radiation to which patients were exposed.

The HINTS exam was developed as a means of assessing patients with the acute vestibular syndrome (AVS), defined as acute onset and persistent vertigo, gait instability, nausea/vomiting, nystagmus, and head motion intolerance [9]. This battery of bedside clinical tests consists of three examinations: the head impulse test (HI-), characterization of spontaneous nystagmus (-N-), and test of skew (-TS) [10]. Each of the three components of the HINTS exam is analyzed

10. Newman-Toker, David E. 3-Step HINTS Battery Video 200-4. Neuro-Ophthalmology Virtual Education Library: NOVEL Web Site [online]. Available at: http://www.kaltura.com/index.php/extwidget/preview/partner_id/797802/uiconf_id/27472092/entry_id/0_b9t6s0wh/embed/auto. Accessed 22 Nov 2017.



295

CAD…An Extremely Difficult DDX

frontiers in Neurology

ORIGINAL RESEARCH
published: 07 November 2017
doi: 10.3389/fneur.2017.00590

Differential Diagnosis of Vertigo in the Emergency Department: A Prospective Validation Study of the STANDING Algorithm

Simone Vanni[1], Rudi Pecci[2], Jonathan A. Edlow[3], Peiman Nazerian[1], Rossana Santimone[2], Giuseppe Pepe[1], Marco Moretti[4], Andrea Pavellini[1], Cosimo Caviglioli[1], Claudia Casula[1], Sofia Bigiarini[1], Paolo Vannucchi[2] and Stefano Grifoni[1]*

[1] Department of Emergency Medicine, Ospedale Versilia, Azienda USL Toscana Nord Ovest, Firenze, Italy, [2] Audiology Clinic, Azienda Ospedaliero-Universitaria Careggi, Firenze, Italy, [3] Department of Emergency Medicine, BIDMC, Boston, MA, United States, [4] Neuroradiology Unit, Azienda Ospedaliero-Universitaria Careggi, Firenze, Italy

- **Conclusion:** Using the STANDING algorithm, non-sub-specialists achieved good reliability and high accuracy in excluding stroke and other threatening causes of vertigo/unsteadiness.

296

CAD…An Extremely Difficult DDX

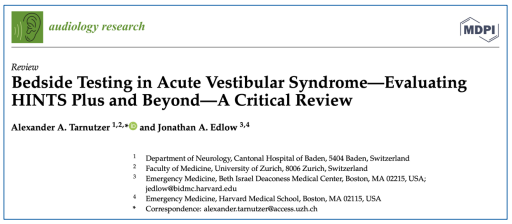

audiology research

MDPI

Review

Bedside Testing in Acute Vestibular Syndrome—Evaluating HINTS Plus and Beyond—A Critical Review

Alexander A. Tarnutzer [1,2,*] and Jonathan A. Edlow [3,4]

1 Department of Neurology, Cantonal Hospital of Baden, 5404 Baden, Switzerland
2 Faculty of Medicine, University of Zurich, 8006 Zurich, Switzerland
3 Emergency Medicine, Beth Israel Deaconess Medical Center, Boston, MA 02215, USA; jedlow@bidmc.harvard.edu
4 Emergency Medicine, Harvard Medical School, Boston, MA 02115, USA
* Correspondence: alexander.tarnutzer@access.uzh.ch

- The **STANDING** algorithm (i.e., a four-step algorithm including
  - 1) the discrimination between **S**pon**TA**neous and positional nystagmus,
  - (2) the evaluation of the **N**ystagmus **D**irection,
  - (3) the head **I**mpulse test, and
  - (4) the evaluation of equilibrium (sta**N**din**G**))

  was designed to be more inclusive to include the diagnosis of benign paroxysmal positional vertigo (BPPV) as well.

297

CAD…An Extremely Difficult DDX

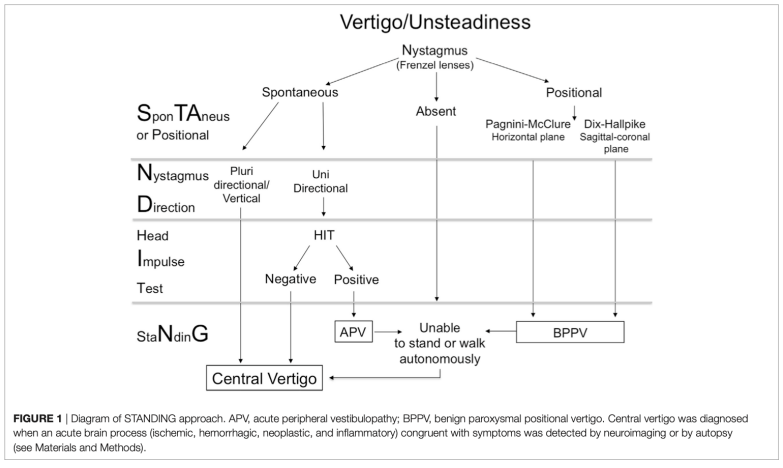

FIGURE 1 | Diagram of STANDING approach. APV, acute peripheral vestibulopathy; BPPV, benign paroxysmal positional vertigo. Central vertigo was diagnosed when an acute brain process (ischemic, hemorrhagic, neoplastic, and inflammatory) congruent with symptoms was detected by neuroimaging or by autopsy (see Materials and Methods).

298

CAD...An Extremely Difficult DDX

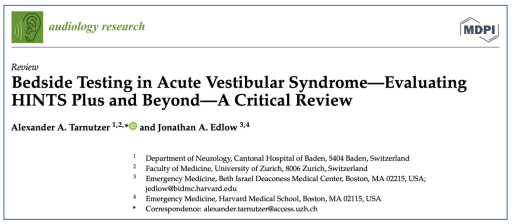

audiology research

MDPI

Review

Bedside Testing in Acute Vestibular Syndrome—Evaluating HINTS Plus and Beyond—A Critical Review

Alexander A. Tarnutzer [1,2,*] and Jonathan A. Edlow [3,4]

1 Department of Neurology, Cantonal Hospital of Baden, 5404 Baden, Switzerland
2 Faculty of Medicine, University of Zurich, 8006 Zurich, Switzerland
3 Emergency Medicine, Beth Israel Deaconess Medical Center, Boston, MA 02215, USA; jedlow@bidmc.harvard.edu
4 Emergency Medicine, Harvard Medical School, Boston, MA 02115, USA
* Correspondence: alexander.tarnutzer@access.uzh.ch

- Missed or delayed diagnosis of posterior circulation stroke is an important and, unfortunately, a common problem.
- For the bedside clinical assessment of acutely dizzy patients meeting the diagnostic criteria of an acute vestibular syndrome, looking for subtle oculomotor signs is key to increasing diagnostic accuracy.
- Both the HINTS(+) exam and the STANDING algorithm are very good exclusion tests in the hands of ***trained*** emergency physicians, non-sub-specialists, and neuro-otology/ neuro-ophthalmology subspecialists [15].
- Thus, in the right circumstances, both HINTS and the STANDING algorithm can distinguish peripheral from central diagnoses, limiting the use of further diagnostic testing to cases where bedside testing points to a central (or equivocal) cause of AVS.

CAD...An Extremely Difficult DDX

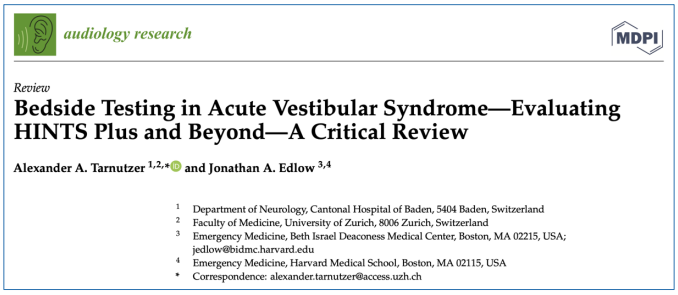

audiology research

MDPI

Review

Bedside Testing in Acute Vestibular Syndrome—Evaluating HINTS Plus and Beyond—A Critical Review

Alexander A. Tarnutzer [1,2,*] and Jonathan A. Edlow [3,4]

1 Department of Neurology, Cantonal Hospital of Baden, 5404 Baden, Switzerland
2 Faculty of Medicine, University of Zurich, 8006 Zurich, Switzerland
3 Emergency Medicine, Beth Israel Deaconess Medical Center, Boston, MA 02215, USA; jedlow@bidmc.harvard.edu
4 Emergency Medicine, Harvard Medical School, Boston, MA 02115, USA
* Correspondence: alexander.tarnutzer@access.uzh.ch

- Importantly, both HINTS(+) [15] and STANDING outperformed early (i.e., within the first 24–48 h) MRI-DWI, which has a sensitivity of 81.1 and a specificity of 99.9 based on a systematic review.

GRACE-3 – Acute Dizziness and Vertigo

Academic Emergency Medicine
A GLOBAL JOURNAL OF EMERGENCY CARE

GRACE CLINICAL PRACTICE GUIDELINE

Guidelines for reasonable and appropriate care in the emergency department 3 (GRACE-3): Acute dizziness and vertigo in the emergency department

Jonathan A. Edlow MD, Christopher Carpenter MD, MSC, Murtaza Akhter MD, Danya Khoujah MD, Evie Marcolini MD, William J. Meurer MD ... See all authors

First published: 11 May 2023 | https://doi.org/10.1111/acem.14728 | Citations: 8

- This **3**rd **G**uideline for **R**easonable and **A**ppropriate **C**are in the **E**mergency Department (GRACE-3) from the Society for Academic Emergency Medicine is on the topic adult patients with acute dizziness and vertigo in the emergency department (ED).



301

Instructive Case

- **60-year-old patient seeks care for lower back pain:**
  - HX and risk factors:
    - Hypertensive
  - Symptoms:
    - Transient dizziness, following massage therapy earlier during the day. Recurrence following lumbar spine SMT. NO cervical spine SMT performed.
  - PE:
    - A&O x 3, BP: 140/90, 74BPM Afebrile
    - - CN
    - + Romberg with drift on walking
    - +Dix-Hallpike
    - - Otoscope
    - - Ortho, remaining - neuro

Consider everything!

302

I was having a nice cup of coffee...



- **Historic Clues...**
  - **Postpartum Preeclampsia**
    - Extremity edema
    - Hypertension
    - Dizziness
    - Blurred vision
    - Confusion
    - Headache
    - Gait abnormality
  - **Missed Clues**
    - Severe unilateral atraumatic neck pain
    - Connective tissue disorder
    - Past history of migraine
    - Persistent symptoms, following preeclampsia care



VAD

303

My VAD Case



Cureus
Part of SPRINGER NATURE

Open Access Case Report

Recognition of Vertebral Artery Dissection in a High-Risk Postpartum Patient by a Chiropractic Physician

James Demetrious [1], Robert J. Trager [2, 3], Stephen Veigh [4], Peter Tuchin [5], David Graber [6]

1. Chiropractic, PostGradDC, Wilmington, USA 2. Family Medicine and Community Health, Case Western Reserve University School of Medicine, Cleveland, USA 3. Chiropractic, Connor Whole Health, University Hospitals Cleveland Medical Center, Cleveland, USA 4. Neuroradiology, Private Practice, Sarasota, USA 5. Chiropractic, Private Practice, Sydney, AUS 6. Chiropractic, Private Practice, Parsippany, USA

Corresponding author: James Demetrious, dr.demetrious@gmail.com

Review began 08/11/2025
Review ended 08/12/2025
Published 08/18/2025

© Copyright 2025
Demetrious et al. This is an open access article distributed under the terms of the Creative Commons Attribution License CC-BY 4.0., which permits unrestricted use, distribution, and reproduction in any medium, provided the original author and source are credited.

DOI: 10.7759/cureus.90389

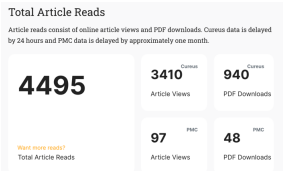

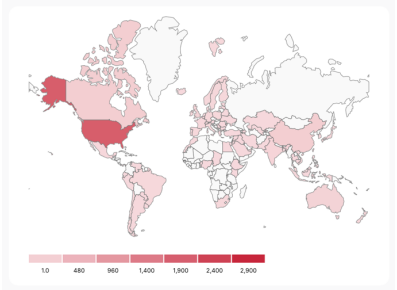

304

Medical Error and Delayed Diagnosis...



Cureus

Open Access Case Report

Recognition of Vertebral Artery Dissection in a High-Risk Postpartum Patient by a Chiropractic Physician

James Demetrious, Robert J. Trager, Stephen Voigt, Peter Tuchin, David Graber

Abstract

We report a case of vertebral artery dissection (VAD) in a patient with postpartum preeclampsia and underscore the contribution of chiropractic assessment in recognizing vascular pathology, facilitating neurovascular imaging, and expediting emergency intervention. A 36-year-old woman with a history of mixed connective tissue disease presented five days postpartum with a constellation of neck pain, facial and peripheral edema, recent onset of hypertension, acute severe neck pain, headache, lightheadedness, confusion, and gait instability. Magnetic resonance angiography (MRA) and magnetic resonance venography of the head were performed. Small, unruptured bilateral internal carotid artery aneurysms were visualized. The patient was admitted and treated for postpartum preeclampsia. Upon discharge, she followed up with a neurovascular specialist. Although the patient improved with preeclampsia management, concerning neurologic symptoms persisted. The patient later consulted a chiropractor, who suspected VAD. Emergent neck MRA was recommended and performed, confirming VAD 12 days after the initial emergency department visit. The patient was initiated on antithrombotic therapy, with subsequent resolution of symptoms and discharge from care. This case highlights the importance of maintaining a sufficiently high index of suspicion for VAD in postpartum patients presenting with new-onset neurological symptoms, particularly in the context of hypertensive disorders of pregnancy and underlying connective tissue disease. It further illustrates the potential role of chiropractic evaluations in the early clinical recognition of vascular pathology, which may facilitate timely diagnosis and intervention, and reduce the risk of stroke.

Categories: Neurology, Radiology, Integrative/Complementary Medicine

Keywords: cervical artery dissection, connective tissue disorders, magnetic resonance angiography, neurovascular imaging, postpartum, preeclampsia, stroke, vertebral artery dissection

Introduction

Vertebral artery dissection (VAD) is a type of cervical artery dissection (CeAD) involving a tear in the wall of the vertebral artery, resulting in hematoma formation. It may cause ischemic stroke, particularly in young adults, and has an incidence rate of approximately two per 100,000 person-years [1]. The clinical presentation of VAD may include occipital headache, neck pain, and other potential features such as visual disturbances, dizziness, and gait abnormalities [1] that can be indicative of brain ischemia. Risk factors for VAD are increasingly understood, such as hypertension, migraine, and connective tissue disorders [2-5].

There is often a delay in the diagnosis of CeAD, with one study reporting a mean time to diagnosis for VAD of 9.8 days (standard deviation of 13.5 days) [6]. CeAD may also be misdiagnosed in the emergency department, with misdiagnosis rates estimated from 1.2% to 5.4% [7]. Other studies have found higher rates of delays of VAD include the potentially nonspecific and variable clinical presentation, a low index of suspicion in young patients, cognitive error (e.g., anchoring, premature closure), and diagnostic overshadowing by more common conditions (e.g., migraine, musculoskeletal neck pain, or tension headache) [4,5,7].

Pregnancy is an increasingly recognized risk factor for CeAD and VAD. One study reported that pregnant women had approximately two times the risk of VAD compared to non-pregnant controls, with an elevated incidence of VAD during a one-year window including pregnancy and postpartum of 1.9 (95% confidence intervals [CI]: 1.7-0.1) per 100,000 person-years [8]. Similarly, a case-control study identified a two-fold increase in CeAD risk associated with pregnancy [5]. In that study, the risk of CeAD was greatest during the postpartum period, with an incidence rate ratio of 1.6 (95% CI: 1.4-11.7) [5]. Despite this increased risk, CeAD and VAD may be particularly underrecognized in postpartum women, given the nonspecific symptoms such as headache and neck pain [2,9].

Patients often present to chiropractic physicians for evaluation of head and neck pain. Accordingly, these clinicians may be positioned to identify red flags suggestive of vascular pathology [11]. In this case report,

How to cite this article

Demetrious J, Trager R J, Voigt S, et al. (August 18, 2020) Recognition of Vertebral Artery Dissection in a High-Risk Postpartum Patient by a Chiropractic Physician. Cureus 12(8): e9588. DOI 10.7759/cureus.9588

- There is often a delay in the diagnosis of CeAD, with one study reporting a mean time to diagnosis for VAD of 9.8 days (standard deviation of 13.5 days) [6].
- CeAD may also be misdiagnosed in the emergency department, with rates of misdiagnosis estimated from 1.2% to 5.4% [7].
- Despite its potential to cause stroke, CeAD is also occasionally misdiagnosed in non-pregnant people, with a study of 7,090 patients reporting a 3.1% initial misdiagnosis rate in emergency settings, often due to symptoms being benign neurological conditions [7].

305

A Case to Consider...my First in 40 Years....

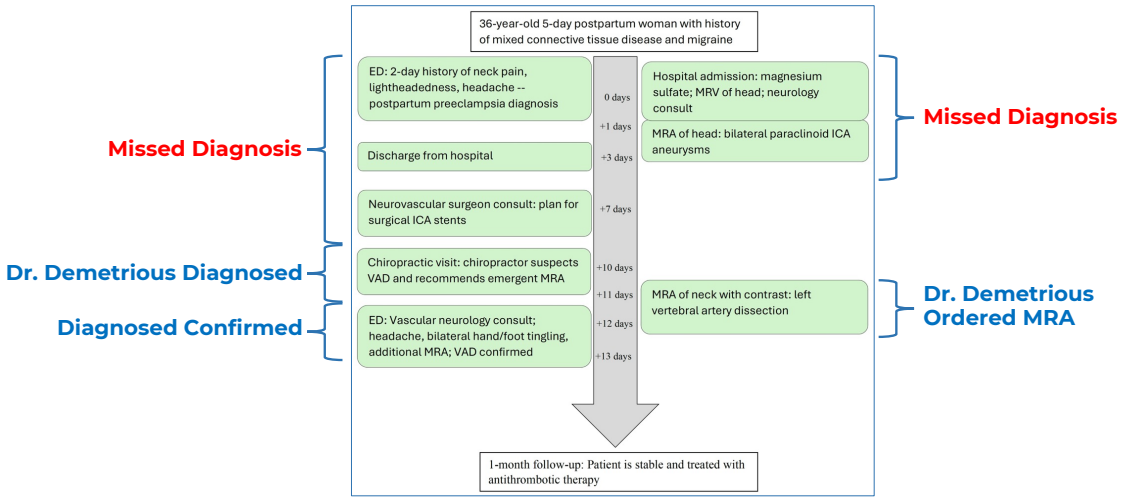

306

A Case to Consider...my First in 40 Years....

Case Report: Delayed Diagnosis of Vertebral Artery Dissection in a Postpartum Patient with Suspected Connective Tissue Disorder

Attending Chiropractor: James Demetrious, DC, DABCO

Abstract:

We present the case of a 35-year-old postpartum female who developed spontaneous vertebral artery dissection (VAD) with concerning neurological symptoms and a complex medical history, including a previously diagnosed connective tissue disorder. This case underscores the need for heightened clinical suspicion and timely vascular imaging in postpartum patients with atypical neck pain and neurological symptoms.

307

VAD Case Presentation

Patient Presentation:

A 35-year-old female, five days postpartum following an uncomplicated vaginal delivery, developed sudden-onset excruciating bilateral posterior neck pain, more prominent on one side (unspecified). The pain was worsened by cervical rotation and movement.

The patient additionally reported transient blurred and spotty vision, dizziness, gait disturbances, confusion, and a general sense of unease, prompting her to seek emergency medical evaluation at the Medical University of South Carolina (MUSC).

308

VAD Case Presentation

Initial Evaluation and Imaging:

At MUSC, the patient underwent MRI/MRA/MRV imaging of the brain. Imaging identified two small intracranial aneurysms. A neurosurgical consultation was obtained, and surgical intervention was discussed as a possibility. Notably, at that time, no imaging of the cervical arteries was performed, and vertebral or cervical artery dissection was not considered.

309

VAD Case Presentation

Medical History:

The patient reported that she was previously diagnosed with systemic lupus erythematosus (SLE) and a possible undifferentiated connective tissue disorder by a physician at Duke University several years prior. However, no treatment was initiated.

Additional history includes:

- Non-smoker
- No history of recent trauma or chiropractic care
- No use of oral contraceptives
- No recent illness
- Postpartum antibiotic use
- Afebrile at presentation; alert and oriented

310

VAD Case Presentation

Clinical Suspicion and Recommendations:

Given the spontaneous onset of severe posterior neck pain, vertigo, visual symptoms, cognitive disturbances, and her postpartum status combined with a possible underlying connective tissue disorder, cervical artery dissection was strongly suspected.

Without the benefit of physical examination (the patient residing four hours away), the following recommendations were urgently made:

1. Immediate consultation with the patient's attending physician and neurosurgeon.
2. Vascular imaging of the cervical arteries via MRA or CTA.
3. Avoidance of chiropractic care due to the suspected diagnosis.
4. Vigilant monitoring of neurological symptoms with instructions to return to the ED should any arise.
5. Continued follow-up with neurosurgery regarding the aneurysms.

311

VAD Case Presentation

Follow-Up and Diagnosis:

The patient underwent cervical MRA on Thursday, June 27. As of Saturday morning, June 29, she had not yet received her imaging results.

At 2:00 AM on June 30, the patient contacted the reporting clinician and stated that she had developed a sudden, severe headache that prompted a return to the hospital. Imaging confirmed a diagnosis of vertebral artery dissection (VAD), and she was admitted for appropriate medical care.

312

VAD Magnetic Resonance Angiography (MRA)

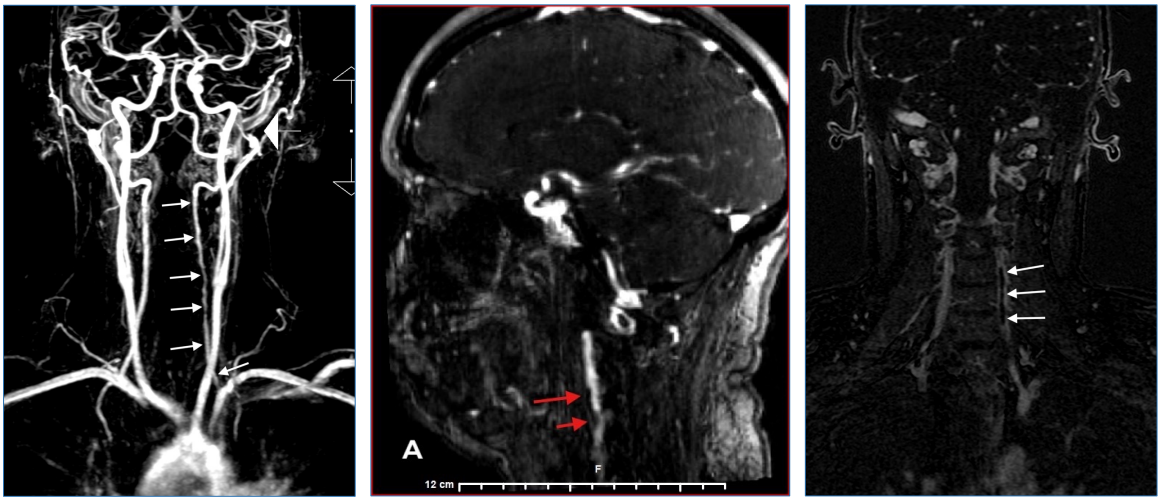

313

Dating the Dissection



- This shows a hyperintense crescent sign in the V2 segment of the left vertebral artery (white arrow), indicating an acute intramural hematoma within the arterial wall.
- Based on signal hyperintensity on a T1-weighted fat-saturated sequence, a consulting neuroradiologist concluded with reasonable medical certainty that the dissection occurred within the two weeks preceding imaging. This timeframe places the vascular event well after the chiropractic intervention performed four weeks earlier [12].
- There is approximately 70–80% stenosis of the arterial lumen present.

314

VAD Case Presentation

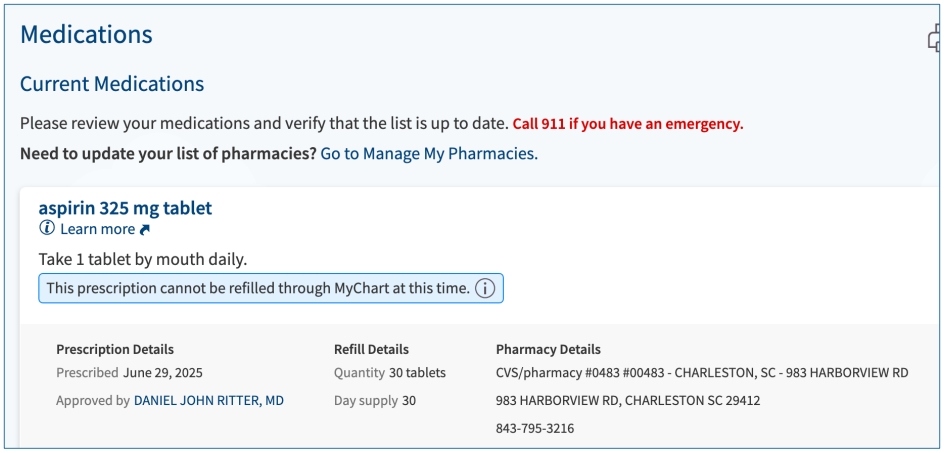

Medications

Current Medications

Please review your medications and verify that the list is up to date. Call 911 if you have an emergency.

Need to update your list of pharmacies? Go to Manage My Pharmacies.

aspirin 325 mg tablet

Learn more

Take 1 tablet by mouth daily.

This prescription cannot be refilled through MyChart at this time.

Prescription Details	Refill Details	Pharmacy Details
Prescribed June 29, 2025	Quantity 30 tablets	CVS/pharmacy #0483 #00483 - CHARLESTON, SC - 983 HARBORVIEW RD
Approved by DANIEL JOHN RITTER, MD	Day supply 30	983 HARBORVIEW RD, CHARLESTON SC 29412
		843-795-3216

315

VAD Case Presentation

Clinical Coordination and Education:

Care was deferred to the attending physicians and neurosurgeon. The patient and her family were advised to remain in close communication with her care team. Educational resources were provided, including literature on cervical artery dissection and general treatment guidelines related to anticoagulant or antiplatelet therapy. Emphasis was placed on ongoing vigilance and symptom monitoring.

A text consultation was sent to a neurosurgeon, neuroradiologist, and emergency physician colleague for additional guidance on clinical management.

316

VAD Case Presentation

Discussion:

This case illustrates the diagnostic challenge of vertebral artery dissection in the postpartum population, particularly when presenting without a classic headache. The patient's history of a possible connective tissue disorder further elevated the clinical suspicion. VAD should remain high on the differential in young females with spontaneous, unexplained neck pain and transient neurologic symptoms, especially during the postpartum period.

317

VAD Case Presentation

Conclusion:

Early recognition and timely vascular imaging are critical in cases of suspected cervical artery dissection, particularly in at-risk populations such as postpartum women and patients with connective tissue disorders. Multidisciplinary coordination and patient education are essential for optimizing outcomes in these potentially life-threatening presentations.

318

Honest Documentation is Important

HPI

Entry Method: ER
Chief Complaint: L vert dissection. ← Missed by Emergency Medicine and Neuro/Neuroendovascular Surgeon
BAT Alert Result: Consult, not BAT criteria

Home Antithrombotics:
Antiplatelet Medications: Patient denies use
Anticoagulant Medications: Patient denies use

CAD S/S began on 6/16/2025.

36 YO F with PMHx of B/L intracranial ICA aneurysms, reported MCTD, pre-eclampsia, and anxiety who presented to the MUSC ART ED with chest pain/pressure and BLE swelling. Vascular Neurology consulted in the setting of reported headaches/neck pain, sensory disturbances, and noted L vertebral artery dissection on Bon Secours MRA neck from 6/27.

Patient received HVLA-SMT on 5/21/2025 with no reported pain or AE.

Patient recently gave birth and course was c/b post-partum pre-eclampsia with high BP. She additionally has had "adjustments" with the chiropractor within the last month. She was admitted post-partum with HA and an MRV obtained did not show CVST, but did mention ICA aneurysms, which were better characterized on subsequent MRA head. She was referred for evaluation by NES. Her PCP, for completeness sake and in the setting of her MCTD and neck/head pain, ordered an MRA neck, which demonstrated a long segment V2 dissection without hemodynamic compromise. Images not available for review. She denies focal neurological deficits, though endorses L sided neck pain and a headache that's bandlike. She also mentions B/L hand and feet tingling.

← The PCP didn't have a CLUE!

Dr. Demetrious sent an urgent message through the patient to the PCP with orders to attain MRA of the neck that revealed the VAD.

POSTGRADDC EVIDENCE BASED, CLINICALLY INTUITIVE CE

James Demetrious, DC, DABCO

319

319

VAD is Rare and Easy to Miss

INCIDENCE

~2

per 100,000 person-years; may cause ischemic stroke, particularly in young adults

TIME TO DIAGNOSIS

9.8 days

mean delay in one study (SD 13.5 days)

ED MISDIAGNOSIS

1.2–5.4%

estimated rate of missed cervical artery dissection in the emergency department

Why it is missed: a nonspecific, variable presentation, low suspicion in young patients, cognitive error (anchoring, premature closure) and more common explanations such as migraine, musculoskeletal neck pain or tension headache.

POSTGRADDC EVIDENCE BASED, CLINICALLY INTUITIVE CE

320

320

Pregnancy Raises Dissection Risk

PREGNANT vs NON-PREGNANT

~2×

risk of VAD in one study; a case-control study also found a two-fold CeAD risk with pregnancy

POSTPARTUM CeAD RISK

5.5

incidence rate ratio, the highest-risk period (95% CI 2.6–11.7)

PREGNANCY + POSTPARTUM YEAR

5.9

VAD per 100,000 person-years (95% CI 3.7–8.1)

Dissection may be underrecognized postpartum because headache and neck pain are nonspecific. Patients often bring head and neck pain to chiropractors, who may be positioned to spot vascular red flags. This case examines that role.

POSTGRADDC
EVIDENCE BASED, CLINICALLY INTUITIVE CE

321

321

My Patient

33

year-old woman

Five days postpartum after an uncomplicated spontaneous vaginal delivery

Relevant history

- Mixed connective tissue disease, diagnosed eight years earlier (first thought to be lupus; positive anti-RNP antibodies, arthralgia, Raynaud phenomenon, intermittent dysphagia)
- She chose not to pursue immunosuppressive therapy or rheumatology follow-up
- Remote migraine without aura in adolescence
- Denied recent infection, fluoroquinolone use, anticoagulants, tobacco, alcohol and illicit drugs
- Unaware whether she had fibromuscular dysplasia or a patent foramen ovale

POSTGRADDC
EVIDENCE BASED, CLINICALLY INTUITIVE CE

322

322

Emergency Visit: Day 0

- Two days of worsening facial and limb edema, home BP persistently above 140/90, band-like temporal headache, blurred vision, dizziness and confusion
- Then, on the day of the visit: severe occipital headache and new, excruciating left posterior neck pain radiating to the shoulder, limiting rotation both ways
- Diplopia, intermittent scotomata, dyspnea and lightheadedness; her mother noted disorientation

BP (ref <120/<80) **150/103 mm Hg**	**Hemoglobin (ref 12.1–15.1)** **10.7 g/dL**
AST (ref 10–40) **50 IU/L**	**LDH (ref 140–280)** **313 IU/L**
Albumin (ref 3.5–5.0) **2.8 g/dL**	**Lower-limb edema** **2+ bilateral**

Venography showed a filling defect read as a benign arachnoid granulation; chest X-ray was normal. Diagnosis: postpartum preeclampsia, with admission.

323

Admission and Follow-Up: Days 0 to 7

Inpatient care (days 0–3)

- 24-hour magnesium sulfate infusion; neurology consulted
- Day 2 head MRA: small unruptured bilateral paraclinoid ICA aneurysms (0.4 × 0.3 cm right, 0.4 × 0.4 cm left)
- Neck MRA was not performed; VAD went unrecognized
- Discharged on furosemide (5 days) and nifedipine 60 mg daily

Neuroendovascular visit (day 7)

- Video consultation with a neurointerventional surgeon
- Advised close monitoring for aneurysm rupture; considered a candidate for staged flow-diverting stents
- VAD was not suspected and no further imaging was ordered

324

Timeline of Events

Days are counted from the first emergency visit.



Day 0

ED: neck pain, headache, visual change, confusion; diagnosed with postpartum preeclampsia

Days 0–3

Admitted; head MRA shows ICA aneurysms; neck MRA not done

Day 7

Surgeon video visit about aneurysms; VAD not suspected

Day 11

Chiropractor suspects VAD; neck MRA confirms left VA dissection

Day 12

Second ED visit; stroke team repeats MRA; aspirin started

Day 31

Independent neuroradiology review; patient stable

325

Chiropractic Consultation: Day 11

What the history showed

- Sudden, atraumatic severe neck and head pain with visual disturbance, lightheadedness and transient gait instability
- Neck pain had eased, but occipital headache and cognitive clouding persisted
- New right facial numbness and right-hand paresthesias

What the chiropractor did

- Suspected VAD, vessel occlusion, pseudoaneurysm or thromboembolism
- Advised an immediate return to hospital
- Recommended neck MRA or CT angiography with a presumptive diagnosis of VAD
- Her primary care physician ordered an MRA that afternoon

Earlier exposure: high-velocity, low-amplitude cervical and lumbar manipulation at a prenatal visit about four weeks before onset, with no symptoms before or after.

326

Neck MRA Confirms Massive Left VA Dissection



Fig 1. Coronal MRA: long signal abnormality with luminal narrowing, left V2

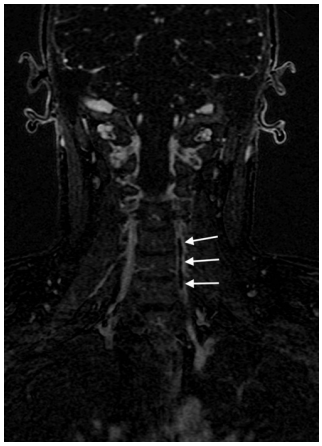

Fig 2. Intra-arterial filling defect, left V2

Day 11 neuroradiology read

- Irregular contour along most of the left V2 segment
- Crescentic T1 fat-saturated hyperintense signal around the vessel: intramural hematoma, diagnostic of dissection
- Long-segment left VA dissection without hemodynamic compromise

Independent Neuroradiology Review: Extent and Age

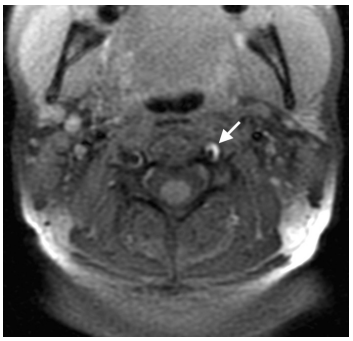

Fig 3. Hyperintense crescent sign, left V2: acute intramural hematoma, about 70–80% lumen stenosis

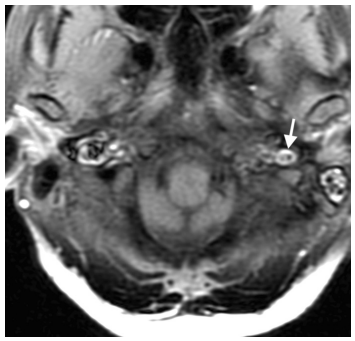

Fig 4. Crescent sign with true and false lumens, left V3: active intramural dissection

Day 31 NR fellowship-trained read

- Large dissection of the left VA from its aortic arch origin through V3
- Intramural hematoma with a V2 filling defect; lumen narrowed by roughly 70–80%
- Signal pattern fits the early to late subacute phase, suggesting dissection within the preceding 14 days

Outcome and Treatment

A missed hand-off

The radiologist entered a critical alert, but the patient received no communication about the VAD finding and went home.

Second ED visit, day 12

Severe left neck pain returned, with band-like headache, chest pain and tingling in hands and feet. Neurologic exam was non-focal and a repeat MRA reconfirmed left VAD.

Treatment and course

Aspirin 325 mg daily began, with no further brain imaging given no overt deficit. Symptoms resolved with no ischemic stroke; stable at one month.

The chiropractor also recommended further rheumatologic and genetic testing for a possible heritable connective tissue disorder and predisposition to recurrent dissection.

POSTGRADDC
EVIDENCE BASED, CLINICALLY INTUITIVE CE

329

329

Why the Diagnosis was Delayed

1. **A plausible first answer**
   Neck pain, visual disturbance and dizziness can occur in preeclampsia, so the initial attribution was justifiable.

2. **Persistence was the turning point**
   Symptoms that continued despite preeclampsia treatment warranted further vascular investigation.

3. **Aneurysms clouded the picture**
   Incidental ICA aneurysms likely confused matters, yet occipital headache, neck pain and gait change are not typical of unruptured ones.

4. **Findings did not reach her**
   The critical MRA result was never communicated to the patient.

The delay sits within the published range: mean 11 days (SD 8) in a series of six postpartum cervical artery dissections. A 7,090-patient study found a 3.1% initial ED misdiagnosis rate.

POSTGRADDC
EVIDENCE BASED, CLINICALLY INTUITIVE CE

330

330

Risk Factors Converged in this Patient

Postpartum

Pregnancy is linked to arterial dissection, with risk potentially heightened after delivery.

Preeclampsia

Arterial dissection risk rises among those with preeclampsia.

Connective tissue disease

Mixed connective tissue disease likely predisposed her; 10% of 57 pregnancy-related CeAD cases had a known connective tissue disorder.

Migraine

Her remote migraine history may be linked to higher CeAD risk.

Bilateral ICA aneurysms in a young postpartum patient may signal a systemic vascular vulnerability and raise the possibility of an underlying connective tissue disorder.

331

How Did Medical Specialists Miss the Diagnosis?

Variant 6: **Headache with new onset or pattern during pregnancy or peripartum period. Initial imaging.**

Procedure	Appropriateness Category	Relative Radiation Level
MRI head without IV contrast	Usually Appropriate	O
CT head without IV contrast	Usually Appropriate	☢☢☢
MRV head without IV contrast	May Be Appropriate	O
CTV head with IV contrast	May Be Appropriate	☢☢☢
Arteriography cervicocerebral	Usually Not Appropriate	☢☢☢
MRA head with IV contrast	Usually Not Appropriate	O
MRA head without and with IV contrast	Usually Not Appropriate	O
MRA head without IV contrast	Usually Not Appropriate	O
MRI head with IV contrast	Usually Not Appropriate	O
MRI head without and with IV contrast	Usually Not Appropriate	O
MRV head with IV contrast	Usually Not Appropriate	O
MRV head without and with IV contrast	Usually Not Appropriate	O
CT head with IV contrast	Usually Not Appropriate	☢☢☢
CT head without and with IV contrast	Usually Not Appropriate	☢☢☢
CTA head with IV contrast	Usually Not Appropriate	☢☢☢



ACR Appropriateness Criteria®

332

What is a Reasonable Standard of Care?

Variant 11: **Adult. Suspected cervical vascular dissection or injury. Initial imaging.**

Procedure	Appropriateness Category	Relative Radiation Level
MRA neck without and with IV contrast	Usually Appropriate	O
MRA neck without IV contrast	Usually Appropriate	O
CT head without IV contrast	Usually Appropriate	☢☢☢
CTA neck with IV contrast	Usually Appropriate	☢☢☢
MRA head without IV contrast	May Be Appropriate	O
MRI head without IV contrast	May Be Appropriate	O
CTA head with IV contrast	May Be Appropriate	☢☢☢
US duplex Doppler carotid artery	Usually Not Appropriate	O
US duplex Doppler transcranial	Usually Not Appropriate	O
Arteriography cervicocerebral	Usually Not Appropriate	☢☢☢
MRA head without and with IV contrast	Usually Not Appropriate	O
MRI head perfusion with IV contrast	Usually Not Appropriate	O
MRI head without and with IV contrast	Usually Not Appropriate	O
MRV head without and with IV contrast	Usually Not Appropriate	O
MRV head without IV contrast	Usually Not Appropriate	O
CT head perfusion with IV contrast	Usually Not Appropriate	☢☢☢
CT head with IV contrast	Usually Not Appropriate	☢☢☢
CT head without and with IV contrast	Usually Not Appropriate	☢☢☢
CTV head with IV contrast	Usually Not Appropriate	☢☢☢



333

Context for the Earlier Manipulation

Approximate positions, not to scale

Estimated dissection window: within 14 days before the day-11 MRA

Prenatal manipulation about 4 weeks before onset

Delivery

ED visit day 0

Neck MRA day 11

No symptoms followed it

She reported no neck pain, headache or other symptoms before or after the manipulation; symptoms began postpartum, alongside preeclampsia.

Imaging fits a later event

The radiologist concluded, with reasonable medical certainty, that the dissection occurred within two weeks before imaging, well after the manipulation.

The authors' reading

The dissection developed postpartum, not as a delayed consequence. High-quality evidence does not support a causal link between cervical manipulation and VAD.

334

Clinical Takeaways

Keep a high index of suspicion
Think of VAD in postpartum patients with new neurologic symptoms, especially with hypertensive disorders of pregnancy or connective tissue disease.

Let persistence prompt a rethink
When symptoms continue despite treatment for the first diagnosis, widen the work-up to the vessels.

Image the neck
Severe posterior headache, neck pain, visual disturbance or dizziness should prompt emergent vascular imaging that includes the neck (MRA or CT angiography).

Work across disciplines
Chiropractors and other outpatient clinicians who spot neurovascular red flags can help speed diagnosis and avoid stroke.

335

Strengths and Limitations

Strengths

- Detailed imaging findings
- A clear timeline of events
- A multidisciplinary author team spanning chiropractic and neuroradiology

Limitations and next steps

- Single-case design limits generalizability
- Possible recall bias
- Future case series, cohort and case-control studies could clarify risk factors and timing of postpartum VAD

336

Conclusion

1. Attributing early symptoms solely to obstetric complications such as preeclampsia can lead to diagnostic oversight of VAD
2. Here the diagnosis was delayed about two weeks, until a chiropractor identified red flags and advocated urgent neck MRA
3. Early vascular imaging, including the neck, is essential to avoid missed or delayed diagnoses that may lead to stroke

VAD should stay on the differential for postpartum patients with headache, neck pain, dizziness or neurologic symptoms.

337

Responsibility, Diligence and Duty

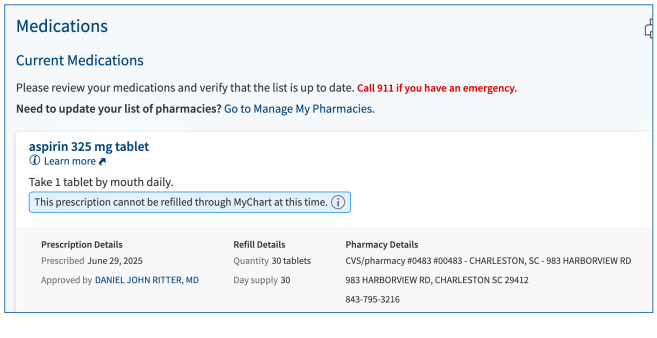



338

POSTGRADDC
EVIDENCE BASED, CLINICALLY INTUITIVE CE

Poor Methodology, and Bad Science
Lessons to Protect Patients

James Demetrious, DC, DABCO
Diplomate, American Board of Chiropractic Orthopedists

www.PostGradDC.com

339

In Defense of Chiropractic…

My first and foremost goal is to protect our patients. I seek to improve clinical acumen to identify those patients most at risk. The following are my opinions based on my experience and my interpretation of the current research literature.

- **My Concerns:**
  - Bias,
  - Poor research methodology,
  - Utilization of low-level evidence, unsubstantiated hypothesis, and opinion,
  - Poorly qualified experts who have falsely elevated their credentials.

340

OPEN ACCESS Freely available online

PLOS ONE

The Quality of Reports on Cervical Arterial Dissection following Cervical Spinal Manipulation

Shari Wynd[1]*, Michael Westaway[2], Sunita Vohra[3,4], Greg Kawchuk[5]

1 Texas Chiropractic College, Pasadena, Texas, United States of America, 2 Lifemark Health, University of Alberta, Calgary, Alberta, Canada, 3 Department of Pediatrics, Faculty of Medicine and Dentistry, University of Alberta, Edmonton, Alberta, Canada, 4 Complementary and Alternative Research and Education Program, Pediatric Complementary and Alternative Medicine Research and Education Network, Alberta Innovates Health Solutions, Edmonton, Alberta, Canada, 5 Department of Physical Therapy, University of Alberta, Edmonton, Alberta, Canada

"This study has demonstrated that the literature infrequently reports useful data toward understanding the association between cSMT, CADs and stroke."

341

In Defense of Chiropractic…



Clinical Case Reports

CASE REPORT OPEN ACCESS

Ischemic Stroke Associated With Vertebral Artery Occlusion Following Cervical Spine Manipulation in a Young Woman With Underlying Vascular Risk Factors: A Case Report

Agussanta González-Delatorre[1] | Joliette Alvarado-Velásquez[1,2] | Bárbara Ruiz-Alayón[1,3] | Cristina López-Sánchez[1,2,3] | José Ayala-Hernández[1,2,3]

[1]Grupo de Investigación Clínica Médica y Terapéutica A—Escuela Luis Razetti, Universidad Central de Venezuela, Caracas, Venezuela | [2]Departamento de Medicina, Escuela de Medicina Luis Razetti, Universidad Central de Venezuela, Caracas, Venezuela | [3]Servicio Medicina I, Hospital Universitario de Caracas—Venezuela, Caracas, Venezuela

Correspondence: José Ayala-Hernández (joayala07@gmail.com; jose.r.ayala@ucv.ve)

Received: 17 September 2026 | **Revised:** 30 September 2026 | **Accepted:** 14 October 2026

Keywords: brain stem infarction | chiropractic manipulation | pontine infarction | stroke | vertebral artery dissection

ABSTRACT

A 35-year-old woman with migraine and oral contraceptive use presented with pontine stroke and right vertebral artery occlusion following cervical manipulation by a lay practitioner. Managed conservatively outside the reperfusion window, she achieved progressive recovery. This case highlights a plausible temporal association between neck manipulation and ischemic events.

1 | Introduction

Cervical manipulation therapy (CMT) is a technique frequently utilized in the management of various musculoskeletal disorders. However, it can lead to severe complications, including cervical artery dissection (CAD), which represents a significant etiology of ischemic stroke, particularly among young adults—accounting for up to 10% of stroke cases in this demographic [1].

The overall pooled incidence of stroke in Latin America and the Caribbean has been reported at 255 per 100,000 individuals. Currently, the global burden of stroke is predominantly concentrated in low- and middle-income countries, which encompass over 65% of Latin American nations. Recent epidemiological data highlight an increasing burden of stroke in young individuals—termed "premature stroke"—representing 10% to 15% of all cases [2, 3]. Furthermore, posterior circulation strokes account for approximately 20% to 25% of all global ischemic strokes [4].

Thromboembolism is the most common pathophysiological mechanism of ischemic stroke secondary to CAD and correlates significantly with neuroimaging signs of thrombus formation [5]. More than 50% of CAD cases occur spontaneously and may be associated with underlying connective tissue disorders, such as fibromuscular dysplasia, Ehlers-Danlos syndrome, Marfan syndrome, and Loeys-Dietz syndrome [6]. Additionally, other conditions have been described, including α1-antitrypsin deficiency, hyperhomocysteinemia, recent infections, vascular anatomical variations, history of migraine, and the use of oral contraceptives (OCs). Nevertheless, robust clinical literature has yet to confirm whether many of these variables represent definitive independent risk factors for arterial dissection [7].

Herein, we report the case of a 35-year-old female patient with a history of migraine and oral contraceptive use who developed a right vertebral artery occlusion accompanied by a pontine infarction following cervical spine manipulation by an unregulated lay practitioner. This report aims to provide clinical insights into the

This is an open access article under the terms of the Creative Commons Attribution License, which permits use, distribution and reproduction in any medium, provided the original work is properly cited.
© 2026 The Author(s). *Clinical Case Reports* published by John Wiley & Sons Ltd.



Critical Review: Errors, Unsupported Opinions, and Conclusions

Review Written by: James Demetrious, DC, DABCO

Article: González-Delatorre A, et al. Ischemic Stroke Associated with Vertebral Artery Occlusion Following Cervical Spine Manipulation in a Young Woman with Underlying Vascular Risk Factors: A Case Report. Clinical Case Reports. 2026;14:e73772.

DOI: 10.1002/ccr3.73772

Overall assessment

The authors describe a clinically important case of pontine ischemic stroke associated with right vertebral artery occlusion following cervical manipulation performed by an unregulated lay practitioner. However, the article contains several important scientific and interpretive weaknesses, particularly regarding causation, diagnostic certainty, chronology, practitioner classification, biomechanical inference, and the application of evidence from case reports to professional chiropractic practice. Importantly, the authors acknowledge some important limitations and that a causal relationship cannot be established.

1. Critical findings

- **Major Deficit - Possible pre-existing vertebral artery dissection or pre-existing unidentified vascular pathology**
  - The patient developed a new, severe, persistent, treatment-resistant headache six days before manipulation. This raises the possibility that arterial pathology was already present before the intervention.
- **Major Deficit - Dissection not definitively demonstrated**
  - CTA identified vertebral artery occlusion but did not demonstrate an intimal flap, double lumen, or pseudoaneurysm. The authors themselves describe dissection as highly compatible rather than confirmed. Cervical MRA with fat-suppressed sequences or high-resolution vessel wall MRI were not performed that could have provided insight and temporal delineation of a dissection event.
- **Major Deficit - Unregulated lay practitioner, not a chiropractor**
  - The report does not establish that a licensed chiropractor performed the procedure. Evidence concerning an unregulated practitioner cannot automatically be generalized to licensed chiropractic practice.
- **Major Deficit - Causal mechanism remains speculative**
  - The authors propose that manipulation may have worsened a vascular tear or dislodged a thrombo-embolus through unsubstantiated strain references that are not supported in the literature. Neither mechanism was demonstrated by the clinical or imaging findings.

342

In Defense of Chiropractic…

2. Detailed appraisal of questionable statements

Article statement or conclusion	Scientific criticism	Assessment
Page 1: Cervical manipulation can lead to severe complications, including CAD.	This categorical wording implies an established causal mechanism. The case and cited observational literature do not independently establish causation.	Causal overstatement
Page 1: Stroke and occlusion occurred following cervical manipulation.	Chronologically correct, but temporal succession alone cannot establish causation.	Association, not causation
Page 2: Manipulation was performed by an unregulated lay practitioner.	The practitioner's training, credentials, procedural competence, and precise technique are not documented.	Important limitation
Page 2: The vascular findings strongly support dissection.	Occlusion and a string sign are compatible with dissection but are not uniquely diagnostic. Alternative causes were considered without definitive exclusion.	Diagnostic uncertainty
Page 2: Migraine and oral contraceptives are underlying vascular risk factors.	These may be relevant to ischemic stroke risk, but their independent contribution to cervical artery dissection is less certain.	Risk-factor conflation
Page 3: High-velocity techniques produce significant mechanical strain on cervical vessels.	The cited study is a retrospective clinical series, not a direct biomechanical measurement of arterial strain.	Citation-to-claim mismatch
Page 3: The Wynd review evaluated causation using Bradford Hill criteria.	Wynd principally evaluated the reporting quality of published cases and their capacity to support causal inference.	Mischaracterization
Page 3: The imaging sequence supports the diagnosis.	CTA was performed nine days after admission, limiting reconstruction of the initial vascular event and its chronology.	Timing limitation
Page 4: Manipulation may have exacerbated a tear or dislodged an embolus.	Neither progression of a tear nor embolic displacement was directly observed.	Mechanistic speculation
Page 4: Several studies suggest increased relative risk.	No pooled risk estimate, comparator definition, or adequate adjustment for confounding is presented to substantiate the broad concluding claim.	Insufficient qualification
Page 4: Stronger regulation may prevent catastrophic complications.	Regulatory oversight is a reasonable policy consideration, but preventive effectiveness cannot be established from this case.	Policy opinion

These assessments concern the strength of the evidence supporting each claim.

3. An important clinical issue: symptoms preceded manipulation

Clinical timeline

1. February 20, 2025 - New, severe, continuous, atypical headache develops following an acute stressful event. The headache differs from her usual migraines and resists medication.
2. February 26, 2025 - Patient seeks care for persistent headache. An unregulated practitioner performs cervical manipulation without a documented prior neurological examination. Acute neurological

343

In Defense of Chiropractic…

deficits follow immediately.

3. February 28, 2025 - Brain MRI confirms acute left pontine ischemic infarction.
4. March 7, 2025 - CTA identifies right vertebral artery occlusion, but no direct signs of dissection.

This chronology supports at least three concurrent hypotheses:

1. A spontaneous vertebral artery dissection developed before manipulation, with subsequent ischemic stroke occurring as part of its natural progression.
2. An underlying vascular lesion existed before manipulation.
3. The unqualified person who delivered the manipulation did not identify possible historic risk factors, did not perform an appropriate evaluation or identify concerning signs or symptoms contributing to an acute vascular event.

The available evidence does not establish which hypothesis is correct. A more defensible conclusion is that the cause of the vertebral artery lesion and ischemic change remain uncertain. While temporally associated, causation is unproven.

4. Additional diagnostic and neurological concerns

A. Dissection versus occlusion

The CTA establishes an important vascular abnormality, but occlusion is not synonymous with dissection. The authors acknowledge that an intimal flap, double lumen, and pseudoaneurysm were absent. Cervical high-resolution vessel-wall MRI, suitable follow-up vascular imaging, might have strengthened the diagnosis. Their absence does not exclude dissection, but it reduces diagnostic certainty.

B. Neurological localization deserves clarification

The report describes a left pontine infarction with right hemiparesis and right central facial weakness, together with motor aphasia. Contralateral hemiparesis and facial palsy can be consistent with a left pontine lesion. However, motor aphasia requires a more careful anatomical explanation that generally indicates dysfunction of dominant-hemisphere language networks rather than an isolated pontine lesion. The most common cause of motor aphasia is an ischemic stroke involving the left middle cerebral artery (MCA), which directly supplies blood to Broca's area in the frontal lobe. Dysarthria, which may accompany pontine stroke, is not equivalent to aphasia. The authors should clarify whether the brain MRI revealed any abnormalities, if formal language testing distinguished aphasia from dysarthria, and whether additional supratentorial ischemic lesions were excluded.

C. Delayed and inadequate vascular and brain imaging

The first reported vascular study was performed nine days after admission. Without vascular imaging before the manipulation or immediately following the neurological deterioration, the authors cannot establish when the occlusion developed or whether it evolved during the intervening period. This is a particularly important limitation when evaluating the proposed causal mechanism. If performed, T1-weighted fat-suppressed MRA

344

In Defense of Chiropractic…

and high-resolution vessel wall imaging could have offered more insight into intramural, hematoma degradation.

5. Problems with the interpretation of cited literature

Two references deserve special scrutiny.

- Wynd et al. (2013). The article uses the review's descriptive findings to discuss the relationship between manipulation and arterial dissection. However, the review concerns the quality of published case reports. Such cases are selected adverse-event reports, not a representative denominator from which incidence or comparative risk can be calculated. The application of Bradford Hill considerations does not overcome these methodological limitations.
- Mitra et al. (2021). The authors cite this clinical study in support of significant mechanical strain produced by cervical thrust procedures and fail to reflect on substantive vessel strain research that refutes this claim. A clinical series of patients with dissection **cannot** directly quantify arterial strain, establish vessel failure thresholds, or prove that the intervention caused the observed dissection.

These distinctions matter because evidence of a clinical event, evidence of a biomechanical mechanism, and evidence of population-level causation are different forms of scientific inquiry. The authors appropriately cite Whedon et al. (2023), recognizing that patients with evolving dissection may seek treatment for headache or neck pain. That observation should have been more prominently integrated into the article's final interpretation.

6. What the article establishes versus what remains uncertain

Question	Evidence from this case
Did the patient experience an ischemic stroke?	Yes. MRI documented acute pontine infarction.
Was a vertebral artery occlusion present?	Yes. CTA documented right vertebral artery occlusion.
Was vertebral artery dissection definitively confirmed?	No. It was considered highly compatible with the imaging findings.
Did the headache begin before manipulation?	Yes, six days earlier.
Did neurological deterioration occur immediately after manipulation?	Yes, according to the clinical history.
Did manipulation cause the dissection?	Not established.
Did manipulation worsen an existing dissection or precipitate embolization?	Possible, but unproven.
Was a licensed chiropractor involved?	Not established; the report identifies an unregulated lay practitioner.
Can this case quantify the risk of chiropractic cervical manipulation?	No.
Does this case demonstrate the importance of screening for vascular warning symptoms?	Yes. It provides a clinically relevant illustration of that need.

345

In Defense of Chiropractic…

7. Conclusions that should be retained

A balanced scientific critique should recognize the article's legitimate contributions. The authors correctly emphasize that severe, unusual, persistent headaches warrant careful clinical evaluation. They acknowledge the possibility of a pre-existing dissection and expressly state that causation cannot be established. The immediate onset of neurological deficits following the procedure should not be dismissed. It merits clinical investigation and accurate adverse-event reporting. The absence of a documented neurological examination before the procedure also represents an important patient-safety concern, particularly given the six-day history of an atypical, refractory headache.

8. Recommended replacement conclusion

This case documents an acute pontine ischemic stroke and right vertebral artery occlusion in a patient who experienced neurological deterioration immediately following cervical manipulation of unknown means performed by an unregulated lay practitioner. The patient had developed a severe, atypical, persistent headache six days before the procedure, raising the possibility of an evolving spontaneous cervical arterial disorder. Although the vascular findings were compatible with dissection, definitive imaging features were not demonstrated, and the timing of the arterial lesion could not be established. Consequently, a causal relationship between manipulation and arterial dissection or ischemic stroke remains unproven. **The case emphasizes the importance of recognizing potential vascular warning symptoms, conducting appropriate neurological assessment, and arranging timely emergency referral, when indicated.**

Final scientific judgment

The central weakness of this article is not the reporting of an adverse neurological event, which is legitimate and clinically important. It is the movement from a documented temporal association toward mechanistic and causal interpretations that the available evidence cannot resolve. **The strongest criticisms concern diagnostic uncertainty, the preceding six-day headache, insufficient evidence for the proposed vascular mechanism, imprecise neurological localization, inadequate imaging, and the potential conflation of an unregulated lay practitioner's intervention with licensed chiropractic care.**

346

In Defense of Chiropractic…



Medical Hypotheses 214 (2026) 112095

Contents lists available at ScienceDirect

Medical Hypotheses

journal homepage: www.elsevier.com/locate/mehy

Letter to Editors

Comment on: Cervical artery dissection: initial asymptomatic phase or healing phase? A counter-hypothesis

Dear Editor,

We read Brown's hypothesis paper with interest and concern. [1] Several aspects of the manuscript warrant clarification to distinguish hypothesis generation from evidence sufficient to support clinical interpretation, recommendations, or standards of care.

The proposed sequence of painful onset, symptom resolution, thrombus organization, loosening of thrombus adherence, and delayed embolization has not, to our knowledge, been demonstrated through prospective longitudinal imaging, serial vessel-wall magnetic residence imaging (MRI), or pathological investigation. [2–5] Consequently, this sequence should be regarded as a testable hypothesis rather than an established pathophysiologic mechanism.

The manuscript presents the healing-phase hypothesis largely as an alternative to asymptomatic onset. However, these mechanisms are not necessarily mutually exclusive. Some dissections may begin with minimal or no symptoms, whereas others may evolve from an initially painful phase into a relatively painless healing stage. Current evidence supports a heterogeneous clinical spectrum rather than a single dominant natural history. [2,3]

The discussion of asymptomatic vertebral artery dissection relies substantially on observations reported by Lee et al. [4] However, the frequently cited estimate of asymptomatic vertebral artery dissection was derived from only three asymptomatic patients among 47 vertebral artery dissection cases. Likewise, the recent population-based study by Griffin et al. [5] identified relatively few asymptomatic spontaneous cervical artery dissections (CeAD) despite its broader epidemiologic scope. Both studies provide important observational data and generate worthwhile hypotheses, but the small number of asymptomatic cases limits the strength and precision of inferences regarding the natural history of CeAD. Greater caution is therefore warranted when extrapolating these observations into broader clinical conclusions or clinical recommendations.

The discussion of migraine similarly appears to extend the implications of the cited literature beyond the conclusions reached by the original investigators. Although systematic reviews demonstrate an association between migraine and CeAD, the underlying pathophysiology remains uncertain, with proposed explanations including shared genetic susceptibility, underlying arteriopathy, medication exposure, and residual confounding. [6] Accordingly, these studies do not establish migraine as a relative contraindication to cervical spine manipulation or support changes in current clinical recommendations.

Likewise, statements suggesting that high-volume manual therapy practice models reduce opportunities for appropriate history-taking appear to reflect opinion rather than conclusions supported by evidence presented in the manuscript. Such assertions would be strengthened by empirical investigation before incorporation into scientific discussion.

Finally, the comparison between a superficial skin laceration and the evolution of CeAD may oversimplify the underlying vascular biology. Unlike cutaneous wound healing, the dissected arterial wall remains highly thrombogenic because of disturbed blood flow, luminal stenosis, and continued exposure of thrombogenic subintimal tissue. [7] These biological differences limit the applicability of this analogy.

Future studies incorporating serial vessel-wall MRI, longitudinal clinical follow-up, and imaging correlated with thrombus morphology may help determine whether incidentally identified dissections more commonly represent silent onset, healing lesions, or a combination of both. Until such evidence is available, caution is warranted before drawing clinical recommendations or altering standards of care based upon an untested hypothesis.

CRediT authorship contribution statement

James Demetrious: Writing – review & editing, Writing – original draft, Conceptualization. **Donald R. Murphy:** Writing – review & editing. **David Graber:** Writing – review & editing. **Ronald Farabaugh:** Writing – review & editing. **Peter Tuchin:** Writing – review & editing. **Jeffrey Wilder:** Writing – review & editing. **Bruce Symons:** Writing – review & editing. **Philip Conway:** Writing – review & editing.

Ethics statement

This manuscript is a scholarly Letter to the Editor and does not involve human participants, patient data, or animal research. Institutional Review Board approval was not required.

Funding

No external funding was received for the preparation of this manuscript.

Declaration of competing interest

The authors declare the following financial interests/personal relationships which may be considered as potential competing interests: JD serves as a postgraduate educator and independent speaker for the National Chiropractic Mutual Insurance Company (NCMIC). He is the CEO of PostGradDC, a provider of postgraduate continuing education for healthcare professionals. He is a consultant related to complex malpractice cases. DRM, RF, PT, JW, BS and PC have served as malpractice expert witnesses. DG reports no known competing financial

https://doi.org/10.1016/j.mehy.2026.112095
Received 15 July 2026; Received in revised form 19 July 2026; Accepted 21 July 2026
Available online 24 July 2026
0306-9877/© 2026 Elsevier Ltd. All rights are reserved, including those for text and data mining, AI training, and similar technologies.



Letter to Editors

Medical Hypotheses 214 (2026) 112095

interests or personal relationships that could have appeared to influence the work reported in this paper.

References

[1] Brown EP. Cervical artery dissection: Initial asymptomatic phase or healing phase? A counter-hypothesis. Medical Hypotheses 2026;214. https://doi.org/10.1016/j.mehy.2026.112095.

[2] Debette S, Mazighi M, Bijlenga P, Pezzini A, Kuga M, Bersano A, et al. ESO guideline for the management of extracranial and intracranial artery dissection. Eur Stroke J. 2021;6(3):XCIX–CLXXIII. https://doi.org/10.1177/23969873211039926.

[3] Lee VH, Brown Jr RD, Mandrekar JN, Mokri B. Incidence and outcome of cervical artery dissection: a population-based study. Neurology 2006;67(10):1809–12. https://doi.org/10.1212/01.WNL.0000244486.30402.73.

[4] Griffin KJ, Harrazo WS, Mandeker J, Brown Jr RD, Kneer J. Epidemiology of Spontaneous Cervical Artery Dissection Population-Based Study. Stroke 2024;55(3):604–7. https://doi.org/10.1161/STROKEAHA.123.045647.

[5] Kan Z, Kleine-Borgmann J, Suk J, Mellerowitz SC, Vidavsky A, Bitt PM. Migraine and the risk of cervical artery dissection: A systematic review and meta-analysis. Eur Stroke J. 2025;10(4):904–14. https://doi.org/10.1177/23969873251319856.

[6] Kneer J, Dining GC, Brown JC, Poynter A, Lacasse G. Cervical Artery Dissection: Risk Factors and Outcomes. Can J Neurol Sci. 2000;27(2):146–50. https://doi.org/10.1017/S0317167100000986.

James Demetrious[a], Donald R. Murphy[b], David Graber[c], Ronald Farabaugh[d], Peter Tuchin[e], Jeffrey Wilder[f], Bruce Symons[g], Philip Conway[h]

[a] PostGradDC, Postgraduate Education
[b] Private Practice
[c] Expert Witness

[*] Corresponding author at: Wilmington, North Carolina, USA.

- **Our Concerns:**
  - Thromboembolic mechanisms
  - Asymptomatic conjecture
  - Migraine association
  - High volume practices
  - Skin laceration analogy

In Defense of Chiropractic…



LETTER TO THE EDITOR

Cervical Artery Dissection and Chiropractic

CERVICAL ARTERY DISSECTION AND CHIROPRACTIC-LETTER TO THE EDITOR

We congratulate the authors on their paper, which addresses an important but contentious clinical question.[1] However, in our opinion, there are some design limitations, statistical misapplications, and possible misinterpretation of observational associations that could affect the conclusions. We are keen to hear the author's opinions on the following issues.

While the dataset is large, the conclusions, particularly those related to absolute risk, causality, and clinical reassurance, may be inappropriate given the study design. For example, antecedent chiropractic manipulation, being de rest as any reported manipulation within 30 days, is a very large interval for adverse effects related to a treatment. Most studies on physical therapies or osteopathic manipulation have the interval for adverse effects around 24 to 72 hours.[2,3] In addition, many studies on pharmaceuticals or vaccinations also have a similar interval for adverse effects of 24 to 72 hours. It would be interesting to compare their data using the smaller interval of 24 to 72 hours.

Another area, there was no comparison between chiropractic scores and primary care practitioner scores, within the same 30-day interval. I would also be interesting to compare these 2 group statistics using the same intervals.[4] The clinical significance of this could also be tested by making a comparison between chiropractic sessions and physical therapy sessions.

In addition, there are also no direct clinical differences between groups, which affect discussions about causality and public health risk. As the authors noted, the rst symptom of CeAD is neck pain or headache, and the chiropractic group differed significantly from the control group in this regard. The chiropractic group was more than double the control group for neck pain, and an additional 10% higher for headache. This could dramatically affect statistical comparisons between groups, as a confounding factor in people presenting to chiropractors for treatment of neck pain or headache, when the CeAD has already commenced.

This ambiguity leads to post hoc hypothesis construction, particularly in the Discussion, where causal and safety inferences are made without appropriate methodological grounding.[5] A retrospective registry comparison cannot establish whether manipulation is a trigger, a risk factor, or merely a marker of care-seeking behaviour. The current script appears to downplay this issue.

Also related to this issue is the potential for recall bias. Patients presenting with neck pain and stroke symptoms may be:

- more likely to recall recent manipulation,
- more likely to be asked about manipulation,
- forget other events before any manipulation, which may be a more signi cant trigger (eg, sports, other daily living activities, all discriminated to trigger a CeAD).

There is also an important issue related to terminology. Your study uses the term "chiropractic manipulation" even though the practitioners profession is not mentioned in the abstract.

Global prevalence and legislation perform manipulation without chiropractic education. For example, countries such as Kenya, Lebanon, Portugal, Italy, Mexico, and Israel (where some of your data was collected) have minimal licensing or regulatory laws regarding manipulation.[6] In addition, none of these countries has chiropractic educational institutions.[7] This means that the person performing the manipulation may have limited diagnostic and safety screening knowledge or education, and therefore increases the risk of misdiagnosing a possible CeAD.

The provider title is also misleading. From only 0% reported prior chiropractic manipulations, therefore, 86% of CeAD cases did not have prior chiropractic manipulation, ~10% of the population had chiropractic manipulation for numerous unrelated conditions.[8] Your data appears to indicate that prior chiropractic treatment may reduce the risk of CeAD. In addition, there was no discussion about the frequency of spontaneous CeAD or common activities of daily living, which have been reported as triggers for CeAD.

Your study appears to con rm that some patients with early CeAD symptoms (neck pain and headache) seek manipulation, with a CeAD having already commenced. Our group would be happy to work with the authors on future projects or a re-work of the current manuscript.

Peter Tuchin, DipOHSc, GradDipClinSupervision, DipOHS, PhD
Jeffrey Wilder, DC, DABCO, CCSP
Ron Farabaugh, DC
James Demetrious, DC, DABCO
David I. Graber, DC, DACBSP
Private Practice

The authors declare no con ict of interest.
DOI: 10.1097/WNL.0000000000209869

REFERENCES

1. Alayadeh R, Zeidie M, Murto JP, et al. Cervical artery dissection diagnosed following cervical manipulative therapy (CMT) advantages. *Neurol Sci*. 2026;47:1–8.
2. Wieneser A, Lund H, Stafne SN, et al. Adverse events of exercise therapy in randomised controlled trials: a systematic review and meta-analysis. *Br J Sports Med*. 2020;54(19):1132–41.
3. Degenhardt BF, Johnson JC, Kravitz MJ, et al. Characterizing adverse events reported immediately after osteopathic manipulative treatment. *J Am Osteopath Assoc*. 2018;118:141–50.
4. Cassidy JD, Boyle E, Cote P, et al. Risk of vertebrobasilar stroke and chiropractic care: results of a population-based case-control and case-crossover study. *Spine*. 2008;33(suppl 4):S176–S183.
5. Andrade C. Types of analysis: planned (prespecified) versus post hoc, primary vs secondary, hypothesis-driven versus exploratory, subgroup and sensitivity, and others. *Indian J Psychol Med*. 2023;45(6):640–641.
6. Stochkendahl MJ, Kjaer W, Torres P, et al. The chiropractic workforce: a global review. *Chiropr Man Therap*. 2019;27:50.
7. Gliedt JD, Green BN, Amorin-Woods LG, et al. Global status of chiropractic education research and scholarly publications: a scoping review. *J Can Chiropr Assoc*. 2020;23(4):748–755.
8. Believau PJH, Wong JJ, Sutton DA, et al. The chiropractic profession: a scoping review of utilization rates, reasons for seeking care, patient profiles, and care provided. *Chiropr Man Therap*. 2017;25:35.

The Neurologist • Volume 00, Number 00, ■■ 2026 www.theneurologist.org | 1
Copyright © 2026 Wolters Kluwer Health, Inc. Unauthorized reproduction of this article is prohibited.

- **Our Concerns:**
  - Risk/causality
  - No DC/PCP comparison
  - Recall bias
  - SMT performed by non-DCs
  - Misleading title

In Defense of Chiropractic…



JOURNAL OF CONTEMPORARY CHIROPRACTIC

Commentary on Informed Consent
Wilder, Demetrious, Conway et al.

INFORMED CONSENT IN CHIROPRACTIC: COMMENTARY ON BROWN & LEHMAN'S "INFORMED CONSENT REGARDING RISK OF STROKE FROM CERVICAL SPINE MANIPULATION"

Jeffrey Wilder, DC, DABCO[1], James Demetrious, DC, DABCO[2], Phillip Conway,BPE, DC, FCCPOR(C)[1], David Graber, DC, DACBSP[1], Peter Tuchin, DC, PhD[1]

ABSTRACT

Background: A recent article by Brown and Lehman (2025) advocates for the universal inclusion of cervical artery dissection (CAD) and stroke risk in informed consent for cervical spine manipulation (CSM). Their narrative review appears to rely on anecdotal and low-level evidence, raising concerns regarding its validity and potential impact on clinical and legal standards.

Objective: To critically evaluate the scientific, ethical, and legal foundations of Brown and Lehman's 2025 recommendations and to propose alternative recommendations based on current evidence-based standards and informed consent jurisprudence.

Methods: A detailed appraisal of the papers cited in Brown and Lehman's review was conducted. High-level evidence, including epidemiologic studies, systematic reviews, and biomechanical analyses, was contrasted against the narrative sources used by the authors. Legal and ethical standards surrounding informed consent across U.S. jurisdictions were also reviewed.

Results: Brown and Lehman's article may exhibit confirmation bias, selective citation, and a reliance on case reports, commentaries, and narrative reviews that do not support the concept of universal informed consent related to CSM, CAD, and stroke. Major epidemiological and biomechanical studies appear to contradict their claims. Their review did not include contrary evidence, may have misinterpreted key studies, and contained logical inconsistencies. Legal analysis reveals that informed consent standards vary by jurisdiction, with no legal mandate for blanket disclosure of statistically unproven risks such as CAD post-CSM.

Conclusion: The conclusions presented in the Brown-Lehman review article appear to be based primarily on low-level evidence, including narrative reports, commentaries, and case series, which may not meet the threshold necessary to guide clinical standards or establish legal norms. Their recommendation for universal disclosure of CAD risk in informed consent, despite the absence of causative evidence, raises important considerations regarding clinical relevance and medicolegal implications. Informed consent practices should be aligned with the best available evidence, applicable jurisdictional statutes, and professional standards. Chiropractors are encouraged to consult current clinical guidelines, review applicable laws and rules, and seek legal counsel when determining appropriate disclosures within the informed consent process. (*J Contemporary Chirop* 2025;8:259-265)

Key Indexing Terms: Cervical spine manipulation, cervical artery dissection, informed consent, chiropractic, medico-legal standards, narrative review, causation, stroke risk

INTRODUCTION

Informed consent is a cornerstone of ethical and legal healthcare practice, empowering patients with the necessary information to make informed decisions

[1] *Private Practice of Chiropractic,* [2] PostGradDC

J Contemp Chirop 2025, Volume 8 259

- **Our Concerns:**
  - Methodologic inadequacies
  - Low-level evidence
  - Bias
  - Jurisdictional concerns



Letter to the Editor
Lehman

By acknowledging this risk and prioritizing informed consent, the chiropractic profession can uphold its commitment to patient-centered, evidence-based care. (2,37,38)

Steven Brown, DC, DIAMA

James Lehman, DC, MBA, DIANM

In Response:

We appreciate the opportunity to respond to Brown and Lehman (JCC, October 2025), who once again advance the hypothesis that cervical spine manipulation (CSM) can dislodge a thrombus from a pre-existing cervical arterial dissection (CAD) and precipitate ischemic stroke. This hypothesis remains unsubstantiated by empirical, biomechanical, and epidemiologic evidence.

Brown and Lehman's reliance on low-level evidence consisting of anecdotal, case-based, or temporal associations, to the exclusion of existing higher-quality evidence, suggests selective author bias. Their interpretation of the current research literature results in erroneous opinions and determinations.

Multiple authors have pointed out that the apparent temporal association of CSM with CAD in case studies is due to protopathic bias. Protopathic bias is "when an exposure is delivered in the early prodrome of a disease before it is diagnosed" as defined by Cassidy et al. This sequence can lead to a mistaken inference of causation rather than coincidence. (1-7)

No epidemiologic, pathological, or biomechanical studies have demonstrated that cervical CSM can cause CAD or dislodge a mural thrombus within a dissected artery.

Several highly powered epidemiologic studies, encompassing over 500 million person-years of data, consistently indicate that patients who experience vertebral or carotid dissection are equally likely to have visited a chiropractor or a primary care physician due to symptomatic expression, typically head or neck pain. These findings strongly indicate that CSM does not increase the risk of CAD or stroke. (1-2, 6, 7-11)

Numerous biomechanical studies have shown that measured forces during skilled high-velocity, low-amplitude adjustments are lower than those of daily head movements and have not been shown to alter arterial integrity or blood flow. (3-5, 12-24) Accordingly, the thromboembolic (TE)-dislodgement theory remains physiologically implausible.

Collectively, these highly-powered studies indicate that CSM has a null effect as a cause of CAD or TE events and affirm the safety of CSM when performed by skilled practitioners. While we strongly encourage clinicians to remain vigilant for neurovascular compromise, spontaneous CAD, or other unusual vascular symptoms, unsubstantiated theories should not inform clinical practice or patient consent.

Advancing a CSM –thromboembolic (TE)-dislodgement theory without sufficient rigor lacks scientific credibility and may undermine evidence-based discourse. Until more compelling evidence of thrombus dislodgement after CSM is collected, we urge against promoting this hypothesis. Clinical decision-making and informed consent should be guided by objective evidence, which overwhelmingly demonstrates no causal relationship between CSM, CAD, TE, and stroke.

Respectfully submitted,

Jeffrey Wilder, DC, DABCO, James Demetrious, DC, DABCO, Phil Conway, DC, BPE, FCCPOR(C), David Graber, DC, DACBSP, Peter Tuchin, DC, PhD

REFERENCES

1. Wilder J, Demetrious J, Conway P, Graber D, Tuchin P. Informed Consent in Chiropractic: Commentary on Brown & Lehman's "Informed Consent Regarding Risk of Stroke from Cervical Spine Manipulation." JCC. 2025;8(1):295-295.
2. Brown S, Lehman J. Informed consent regarding risk of stroke from cervical spine manipulation: a narrative review. JIANM. 2025;1(2):2-12
3. Church EW, Sieg EP, Zalatimo O, Hussain NS, Glantz M, Harbaugh RE. Systematic review and meta-analysis of chiropractic care and cervical artery dissection: no evidence for causation. Cureus. 2018;8(2):e498. doi:10.7759/cureus.498
4. Chaibi A, Russell MB. A risk-benefit assessment strategy to exclude cervical artery dissection in spinal manual-therapy: a comprehensive review. Ann Med. 2019;51(2):118-127. doi:10.1080/07853890.2019.1590627
5. Tavakoli SG, Britt TB, Agarwal S. Vertebral artery dissection. In: StatPearls. StatPearls Publishing; 2025. Accessed August 26, 2025. http://www.ncbi.nlm.nih.gov/books/NBK441827/

J Contemp Chirop 2025, Volume 8 315

349

Proper Methodology



350

Class Outline

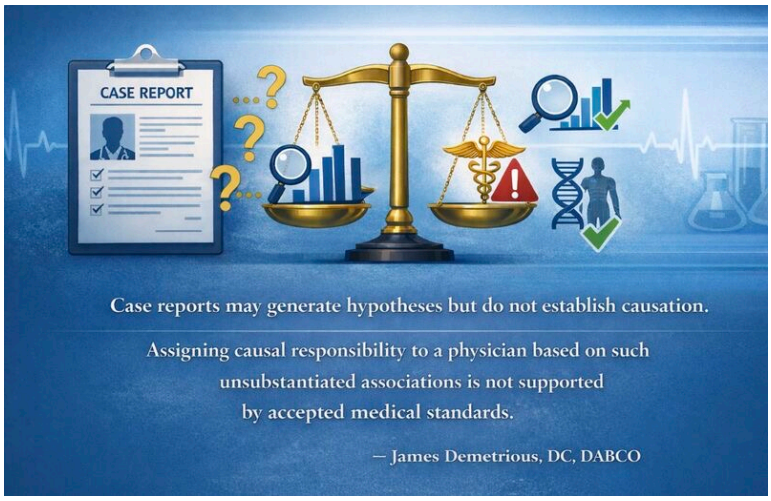

351

Bad Science – A Lack of Causality

Chiropractic Manipulation of the Neck and Cervical Artery Dissection

Background: Chiropractic manipulation of the neck can cause cervical artery dissection and stroke, although the incidence of these complications is unknown (1–4). Patients younger than 45 years with vertebral artery dissection and stroke are 5 times more likely to have visited a chiropractor in the previous 30 days than an age-matched control group (1).

Case Report: In mid-March 2012, a 37-year-old registered nurse with a history of chronic neck pain went to her chiropractor. She had seen the same chiropractor for 12 to 15 years, usually going once a month for cervical spine manipulation. Because of a new symptom (pain when turning her head up and to the right), the current visit had been the fourth in a week. From the patient's perspective, the manipulation done during the current visit was similar to past procedures.

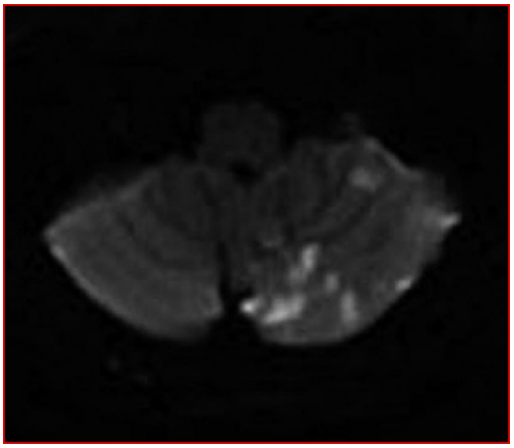

17 July 2012 | Annals of Internal Medicine | Volume 157 • Number 2 | 151

352

Bad Science – A Lack of Causality

Conclusion: Although incidence of cervical artery dissection precipitated by chiropractic neck manipulation is unknown, it is an important risk (3, 4). Given that risk, physical therapy exercises may be a safer option than spinal manipulation for treating patients with neck pain.

Raymond E. Bertino, MD
Arun V. Talkad, MD
Jeffrey R. DeSanto, MD
Jane H. Maksimovic, DO
Shyam G. Patel, MD
University of Illinois College of Medicine at Peoria
Peoria, IL 61637



17 July 2012 | Annals of Internal Medicine | Volume 157 • Number 2 | 151

353

Bad Science – A Lack of Causality

Case report

A near-fatal consequence of chiropractor massage: massive stroke from carotid arterial dissection and bilateral vertebral arterial oedema

Timothy Yap,[1] Li Feng,[2] Dan Xu ,[1,3,4] Jian Zhang[2]

[1]Curtin Medical School, Faculty of Health Sciences, Curtin University, Perth, Western Australia, Australia
[2]Deaprtment of Neurology, First Affiliated Hospital, Sun Yat-sen University, Guangzhou, Guangdong, China
[3]Curtin School of Population Health, Faculty of Health Sciences, Curtin University Bentley Campus, Perth, Western Australia, Australia
[4]Medical Education & General Practice, First Affiliated Hospital, Sun Yat-sen University, Guangzhou, Guangdong, China

Correspondence to
Professor Dan Xu;
daniel.xu@curtin.edu.au

Accepted 27 July 2021

SUMMARY
A 35-year-old Chinese man with no risk factors for stroke presented with a 2-day history of expressive dysphasia and a 1-day history of right-sided weakness. The presentation was preceded by multiple sessions of neck, shoulder girdle and upper back massage for pain relief in the prior 2 weeks. CT of the brain demonstrated an acute left middle cerebral artery infarct and left internal carotid artery dissection. MRI cerebral angiogram confirmed left carotid arterial dissection and intimal oedema of bilateral vertebral arteries. In the absence of other vascular comorbidities and risk factors, massage-induced internal carotid arterial dissection will most likely precipitate the near-fatal cerebrovascular event. The differential diagnosis of stroke in a younger population was consequently reviewed and discussed.

BACKGROUND
Internal carotid artery dissection, the separation of the tunica media and tunica intima of the internal carotid artery, can lead to cerebral infarction in up to two-thirds of patients,[1] accounting for up to in a healthy man, in which symptom onset coincided solely with massage and neck manipulation. We propose that massage and neck manipulation is an independent risk factor for developing internal carotid artery dissection in healthy individuals. Furthermore, our case highlights the importance of including internal carotid artery dissection in the differential diagnosis of cerebral vascular events in younger patients.

CASE PRESENTATION
A 35-year-old Chinese man was brought to the emergency department by a friend, from home alone with a 2-day history of expressive dysphasia and 1 day of right-sided weakness. On collateral history, the presentation was preceded by multiple sessions of neck, shoulder girdle and upper back massage for pain relief in the prior 2 weeks while he was away on a business trip. He denies having any associated fever, headache, nausea, vomiting, palpitations, syncope, incontinence and neck stiffness. His medical history was unremarkable and was not on any medications or herbal remedies.

BMJ Case Rep: first published as 10.1136/bcr-2021-243976 on 6 August 2021. Downloaded from http:

- This study has demonstrated that the literature infrequently reports useful data toward understanding the association between cSMT, CADs and stroke.
- Improving the quality, completeness, and consistency of reporting adverse events may improve our understanding of this important relation.

354

Bad Science – A Lack of Causality

Review > J R Soc Med. 2007 Jul;100(7):330-8. doi: 10.1177/014107680710000716.

Adverse effects of spinal manipulation: a systematic review

E Ernst [1]

Affiliations – collapse

Affiliation

1 Complementary Medicine, Peninsula Medical School, Universities of Exeter & Plymouth, Exeter, UK. Edzard.Ernst@pms.ac.uk

- In conclusion, spinal manipulation, particularly when performed on the upper spine, has repeatedly been associated with serious adverse events.

355

Refuting Bad Science

Tuchin *Chiropractic & Manual Therapies* 2012, **20**:30
http://chiromt.com/content/20/1/30

CHIROPRACTIC & MANUAL THERAPIES

RESEARCH Open Access

A replication of the study 'Adverse effects of spinal manipulation: a systematic review'

Peter Tuchin*

- The number of errors or omissions in the 2007 Ernst paper, reduce the validity of the study and the reported conclusions.
- The omissions of potential risk factors and the timeline between the adverse event and SMT could be significant confounding factors.
- Greater care is also needed to distinguish between chiropractors and other health practitioners when reviewing the application of SMT and related adverse effects.

356

Refuting Bad Science

Review > J Manipulative Physiol Ther. 2015 Nov-Dec;38(9):672-676.
doi: 10.1016/j.jmpt.2013.09.005. Epub 2014 Jan 3.

The Association Between Cervical Spine Manipulation and Carotid Artery Dissection: A Systematic Review of the Literature

Chadwick L R Chung [1], Pierre Côté [2], Paula Stern [3], Georges L'Espérance [4]
Affiliations + expand
PMID: 24387889 DOI: 10.1016/j.jmpt.2013.09.005

- Although several case reports and case series raise the hypothesis of an association, we found no epidemiologic studies that validate this hypothesis.

357

Refuting Bad Science

- A few case studies have reported serious AEs following cervical spinal manipulative therapy (SMT), but whether there is a causal relationship between cervical SMT and CAD has not been determined because of the methodological design, low level of evidence and low prevalence [40,42,43].
  - [40] Rubinstein SM. Adverse events following chiropractic care for subjects with neck or low-back pain: do the benefits outweigh the risks? J Manipulative Physiol Ther. 2008;31:461–464.
  - [41] Tuchin P. A replication of the study 'Adverse effects of spinal manipulation: a systematic review'. Chiropr Man Ther. 2012;20:30.
  - [42] Wynd S, Westaway M, Vohra S, et al. The quality of reports on cervical arterial dissection following cervical spinal manipulation. PLoS One. 2013;8:e59170.
  - [43] Chung CL, Cote P, Stern P, et al. The association between cervical spine manipulation and carotid artery dissection: a systematic review of the literature. J Manipulative Physiol Ther. 2015;38:672–676.

Chaibi and Russell. ANNALS OF MEDICINE. 2019, VOL. 51, NO. 2, 118–127.

358

Bad Science – A Lack of Causality



PLOS ONE

PUBLISH ABOUT

OPEN ACCESS PEER-REVIEWED

RESEARCH ARTICLE

The Quality of Reports on Cervical Arterial Dissection following Cervical Spinal Manipulation

Shari Wynd, Michael Westaway, Sunita Vohra, Greg Kawchuk

Published: March 20, 2013 • https://doi.org/10.1371/journal.pone.0059170

- This study has demonstrated that the literature infrequently reports useful data toward understanding the association between cSMT, CADs and stroke.
- Improving the quality, completeness, and consistency of reporting adverse events may improve our understanding of this important relation.

359

Bad Science – A Lack of Causality

Case Reports › Vasc Endovascular Surg. 2022 Apr;56(3):303-307.
doi: 10.1177/15385744211072660. Epub 2021 Dec 31.

Carotid Artery Dissection and Ischemic Stroke Following Cervical Chiropractic Manipulation: Two Case Reports

Yimin Chen [1], Mohammad Mofatteh [2], Thanh N Nguyen [3], Jack Wellington [4], Wenlong Wei [1], Wenjun Liang [1], Gan Chen [1], Zhaohui Hu [5], Kexun Ouyang [6], Shuiquan Yang [1]

Affiliations + expand

PMID: 34971321 DOI: 10.1177/15385744211072660

- Although there is no direct evidence that chiropractic manipulation causes cervical artery dissection, clinical reports have found that mechanical forces may contribute to cervical artery dissections.

360

No Excess Risk of CAD

- However, several extensive cohort studies and meta-analyses have found no excess risk of CAD resulting in secondary ischaemic stroke for chiropractic SMT compared to primary care follow-up [39,44,68].
  - [39] Cassidy JD, Boyle E, Cote P, et al. Risk of vertebrobasilar stroke and chiropractic care: results of a population-based case–control and case-crossover study. Spine (Phila, PA, 1976). 2008;33:S176–S183.
  - [44] Cassidy JD, Boyle E, Cote P, et al. Risk of carotid stroke after chiropractic care: a population-based case-crossover study. J Stroke Cerebrovasc Dis. 2017; 26:842–850.
  - [68] Church EW, Sieg EP, Zalatimo O, et al. Systematic review and meta-analysis of chiropractic care and cervical artery dissection: no evidence for causation. Cureus. 2016;8:e498.

361

HEAD TO HEAD

Should we abandon cervical spine manipulation for mechanical neck pain? No

Benedict Wand and colleagues (doi:10.1136/bmj.e3679) argue that the risks of cervical spine manipulation are not justified, but **David Cassidy and colleagues** think it is a valuable addition to patient care

J David Cassidy *professor* [1], Gert Bronfort *professor*[2], Jan Hartvigsen *professor*[3]

[1]Division of Epidemiology, Dalla Lana School of Public Health, University of Toronto, Toronto, Ontario, Canada; [2]Department of Research, Northwestern Health Sciences University, Bloomington, Minnesota, USA; [3]Institute of Sports Science and Clinical Biomechanics, University of Southern Denmark, Odense, Denmark

BMJ 2012;344:e3680

362

- The most recent study, by Cassidy et al, replicated the results of the two previous studies using the Ontario population over nine years—that is, over 100 million person years at risk.9
- They confirmed a strong association between chiropractic care and subsequent vertebrobasilar stroke in people under 45 years old using both case-control and case-crossover designs (odds ratio 3.60, 1.46 to 10.84) for those consulting a chiropractor in the previous month.
- However, they found a similar association between family physician care and vertebrobasilar strokes.

BMJ 2012;344:e3680

363

Proper Methodology



Child's Nervous System (2026) 42:181
https://doi.org/10.1007/s00381-026-07299-5

CASE REPORT

Pediatric vertebral artery dissection and ischemic stroke following chiropractic manipulation

Jonathan C. Arnold[1,2] · Andrew M. Brumett[1] · Kylie J. Ortiz Rodriguez[1,2] · Raj Swaroop Lavadi[1,2] · Rabia Qaiser[1,2]

Received: 11 November 2025 / Accepted: 20 March 2026
© The Author(s) 2026

Abstract

Pediatric vertebral artery dissection (VAD) following chiropractic cervical manipulation (CCM) is a rare phenomenon. As chiropractic care of pediatric populations grows internationally, it is imperative to increase awareness of this cause of VAD. The patient encountered in our institution is a 20-month-old male who presented nonspecifically with acute onset of lethargy, vomiting, cyanosis, and respiratory distress. Cerebrovascular imaging revealed a luminal irregularity in the V4 segment of the right vertebral artery, consistent with dissection. The patient's guardian later provided history of taking the child for cervical chiropractic corrections immediately prior to the patient's presentation to the emergency department. The patient was managed non operatively and was later discharged without neurological deficit. Non-specific presentations were also noted in the other two cases described in the literature. Accurate diagnosis of pediatric VAD requires increased surveillance in response to a thorough history and an acknowledgement of the plethora of possible patient presentations and etiologies.

Keywords Chiropractor · Cervical manipulation · Vertebral artery dissection · VAD · Pediatric

Introduction

Vertebral artery dissection (VAD) following chiropractic cervical manipulation (CCM), although well-documented in adults, is less reported in children [1]. Unlike adults, where neck pain is common, children often present with nonspe-

Case presentation

A 20-month-old male with history of poor weight gain and asthma attacks presented to the emergency room with acute onset of lethargy, vomiting, cyanosis, and respiratory distress. On the day of presentation, the parents took

In my opinion, this dubious paper has significant limitations:

- The report demonstrates temporal association without establishing causation.
- The single-case design lacks controls and cannot assess risk or generalizability.
- Insufficient procedural detail prevents evaluation of biomechanical plausibility.
- The intracranial V4 location is not reconciled with a credible mechanical mechanism.
- Key confounders, including vascular anomaly and systemic illness, are not adequately addressed.
- Spontaneous dissection and reverse causation are not meaningfully considered.
- The analysis relies on low-level evidence without incorporating higher-quality epidemiologic data.
- Absence of incidence context and reproducibility limits the interpretation of risk.
- Retrospective history introduces recall and attribution bias.
- No standardized causality framework or mechanistic pathway is presented.

✉ Raj Swaroop Lavadi
rslavadi@iu.edu

[1] Department of Neurological Surgery, Indiana University School of Medicine, 355 West 16th Street, Goodman Hall 5100, Indianapolis, IN 46202, USA

[2] Department of Neurological Surgery, Riley's Children's Hospital, Indianapolis, IN, USA

Published online: 31 March 2026

Springer

BAD Science

364

Proper Methodology



LETTER TO THE EDITOR

Cervical Artery Dissection and Chiropractic

CERVICAL ARTERY DISSECTION AND CHIROPRACTIC:LETTER TO THE EDITOR

We congratulate the authors on their paper, which addresses an important but contentious clinical question.[1] However, in our opinion, there are some design limitations, statistical misapplications, and possible over-interpretation of observational associations that could affect the conclusions. We are keen to hear the author's opinions on the following issues.

While the dataset is large, the conclusions, particularly those related to absolute risk, causality, and clinical reassurance, may be inappropriate given the study design. For example, antecedent chiropractic manipulation, being defined as any reported manipulation within 30 days, is a very large interval for adverse effects related to a treatment. Most studies on physician therapies or osteopathic manipulation have the interval for adverse effects around 24 to 72 hours.[2,3] In addition, many studies on pharmaceuticals or vaccinations also have a similar interval for adverse effects of 24 to 72 hours. It would be interesting to compare their data using the smaller interval of 24 to 72 hours.

In another area, there was no comparison between chiropractic sessions and primary care practitioner sessions. Given the large dataset, it would also be interesting to compare these 2 group statistics using the same intervals.[4] The clinical significance of this could also be tested by making a comparison between chiropractic sessions and physical therapy sessions.

In addition, there are also significant clinical differences between groups, which affect discussions about causality and public health risk. As the authors noted, the first symptom of CeAD is neck pain or headache, and the chiropractic group differed significantly from the control group in this regard. The chiropractic group was more than double the control group for neck pain, and an additional 10% higher for headache. This could dramatically affect statistical comparisons between groups, as a significant number of people presenting to chiropractors for treatment of neck pain or headache, when the CeAD has already commenced.

This ambiguity leads to post hoc hypothesis construction, particularly in the Discussion, where causal and safety inferences are made without appropriate methodological grounding.[5] A retrospective registry comparison cannot adjudicate whether manipulation is a trigger, a risk factor, or merely a marker of care-seeking behavior, yet the manuscript appears to downplay this issue.

Also related to this issue is the potential for recall bias. Patients presenting with neck pain and stroke symptoms may be:

- more likely to recall recent manipulation,
- more likely to be asked about manipulation,
- forget other events before any manipulation, which may be a more significant trigger (eg, sports, other daily living activities, all documented to trigger a CeAD).

There is also an important issue related to terminology. Your study uses the term "chiropractic manipulation" even though the practitioner's profession or education has not been determined. Several professions and laypeople perform manipulation without chiropractic education, for example, veterinarians such as Dr Rossignol in Fortaleza, Italy, Mexico, and Israel (where some of your data was collected) have minimal licensing or regulatory laws regarding manipulation.[6] In addition, none of those countries has chiropractic educational institutions.[7] This means that the person performing the manipulation may have limited diagnostic and safety screening knowledge or education, and therefore increases the risk of misdiagnosing a possible CeAD.

The article's title is also misleading, since only 5% reported prior chiropractic manipulation. Therefore, 95% of CeAD cases did not have prior chiropractic manipulation. ~10% of the population receives chiropractic treatment for numerous unrelated conditions.[8] Your data appears to indicate that prior chiropractic treatment may reduce the risk of CeAD. In addition, there was no discussion about the frequency of spontaneous CeAD or common activities of daily living, which have been reported as triggers for CeAD.

We appreciate the opportunity to confirm that some patients with early CeAD symptoms (neck pain and headache) seek manipulation, with a CeAD having already commenced. Our group would be happy to work with the authors on future projects or a re-work of the current manuscript.

Peter Tuchin, (Ref)BSc, GradDipChiro DipOHS, PhD
Jeffrey Wilder, DC, DABCO, CCSP
Ron Farshough, DC
James Demetriou, DC, DABCO
David I. Gruber, DC, DACBSP
Private Practice

The authors declare no conflict of interest.
DOI: 10.1097/NRL.0000000000000680

REFERENCES

1. Alsyaideh R, Zeidle M, Murto JP, et al. Cervical artery dissection diagnosed following chiropractic manipulation: a STOP-CAD substudy. *Neurologist*. 2026;30:1007.
2. Nienajjer A, Lund H, Stalter SN, et al. Adverse events of exercise therapy in randomised controlled trials: a systematic review and meta-analysis. *Br J Sports Med*. 2020;54:1071–1080.
3. Degenhardt BF, Johnson JC, Brooks WJ, Snider E. Characterizing adverse events reported immediately after osteopathic manipulative treatment. *J Am Osteopath Assoc*. 2018;118:141–149.
4. Cassidy JD, Boyle E, Cote P, et al. Risk of vertebrobasilar stroke and chiropractic care: results of a population-based case-control and case-crossover study. *Spine*. 2008;33(suppl 4):S176–S183.
5. Andrade C. Types of analysis: planned (prespecified) versus post hoc, primary vs secondary, hypothesis-driven versus exploratory, subgroup and sensitivity, and others. *Indian J Psychol Med*. 2023; 45:109–111.
6. Stochkendahl MJ, Rossi M, Torres P, et al. The chiropractic workforce: a global review. *Chiropr Man Therap*. 2019;27:36.
7. Johnson CD, Green BN, Amorin-Woods LG, et al. Global status of chiropractic education research and scholarly publications: a scoping review. *JBI Evid Synth*. 2021;19:1–15.
8. Beliveau PJH, Wong JJ, Sutton DA, et al. The chiropractic profession: a scoping review of utilization rates, reasons for seeking care, patient profiles, and care provided. *Chiropr Man Therap*. 2017;25:35.

365

Proper Methodology

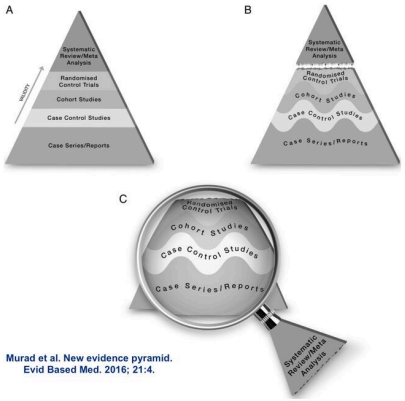

Figure 1 The proposed new evidence-based medicine pyramid. (A) The traditional pyramid. (B) Revising the pyramid: (1) lines separating the study designs become wavy (Grading of Recommendations Assessment, Development and Evaluation), (2) systematic reviews are 'chopped off' the pyramid. (C) The revised pyramid: systematic reviews are a lens through which evidence is viewed (applied).

366

Proper Methodology



Method and Protocol

The Use of Causal Language in Case Reports and Case Series Reporting Ischemic Stroke Following Cervical Manual Therapy: A Qualitative Study Protocol

Nora Bakas[1,2], Melissa Atkinson-Graham[3], Joshua Plener[1,4,5], Pierre Côté[1,6,7,12], Carol Cancelliere[1], L. Rachid Salmi[8], Jan Hartvigsen[7,9], J. David Cassidy[6], Chiara Arienti[11], Marco Campello[1,2], Sheilah Hogg-Johnson[1,2,6], Fred Johansson[14,15], Heather M. Shearer[1,2,16], Eva Skillgate[13,17], Jessica J. Wong[1,2,18,19], Cecilie K. Øverås[20,21], Iben Axén[17,22], Manav V. Vyas[23], Cesar A. Hincapié[24,25], and Silvano Mior[1,6]

Abstract

Objective: This study aims to investigate how authors attribute causality in case reports and case series describing ischaemic stroke following cervical manual therapy. **Methods:** This qualitative, document-based study is nested within a larger epidemiological investigation evaluating the association between cervical manual therapy and ischaemic stroke

[1]Institute of Disability and Rehabilitation Research, Faculty of Health Sciences, Ontario Tech University, Oshawa, ON, Canada
[2]School of Physical Therapy, Faculty of Health Sciences, Western University, London, ON, Canada
[3]Canadian Memorial Chiropractic College, Department of Research and Innovation, Toronto, ON, Canada
[4]Institute of Health Policy, Management and Evaluation, Dalla Lana School of Public Health, University of Toronto, Toronto, ON, Canada
[5]Canadian Memorial Chiropractic College, Department of Clinical Education, Toronto, ON, Canada
[6]Univ. Bordeaux, ISPED, Centre INSERM U1219, Bordeaux Population Health, Bordeaux, France
[7]Center for Muscle and Joint Health, Department of Sports Science and Clinical Biomechanics, University of Southern Denmark, Odense, Denmark
[8]Chiropractic Knowledge Hub, Odense, Denmark
[9]Division of Epidemiology, Dalla Lana School of Public Health, University of Toronto, Toronto, ON, Canada
[10]Danish Institute for Advanced Study, University of Southern Denmark, Odense, Denmark.
[11]Clinical Epidemiology Research Center (CERC), Department of Biomedical Sciences, Humanitas University, Milan, Italy
[12]IRCCS Humanitas Research Hospital, Rozzano, Milan, Italy
[13]NYU Langone Orthopaedic Hospital, Occupational and Industrial Orthopaedic Center (OIOC), New York University, New York, USA
[14]Centre for Psychiatry Research, Department of Clinical Neuroscience, Stockholm Health Care Services, Region Stockholm, Karolinska Institutet, Stockholm, Sweden
[15]Department of Health Promotion Science, Sophiahemmet University, Sweden
[16]Holland Bloorview Kids Rehabilitation Hospital, Bloorview Research Institute, Toronto, ON, Canada
[17]Institute of Environmental Medicine, Karolinska Institutet, Stockholm, Sweden
[18]Department of Epidemiology and Biostatistics, Schulich School of Medicine & Dentistry, Western University, London, ON, Canada
[19]Populations and Public Health Research Program, ICES Western, London, ON, Canada
[20]Department of Public Health and Nursing, Norwegian University of Science and Technology, Trondheim, Norway
[21]The Norwegian Chiropractors' Research Foundation, Et Lin i Bevegelse (ELIB), Oslo, Norway
[22]Division of Neurology, University of Toronto, Toronto, ON, Canada
[23]Epidemiology, Biostatistics and Prevention Institute (EBPI), University of Zurich, Zurich, Switzerland

Corresponding author
Nora Bakas, Institute of Disability and Rehabilitation Research, Ontario Tech University, 2000 Simcoe Street North, Oshawa, ON L1G 0C5, Canada.
Email: noorahuda.bakas@ontariotechu.net.

Creative Commons Non Commercial CC BY-NC: This article is distributed under the terms of the Creative Commons Attribution-NonCommercial 4.0 License (https://creativecommons.org/licenses/by-nc/4.0/) which permits non-commercial use, reproduction and distribution of the work without further permission provided the original work is attributed as specified on the SAGE and Open Access pages (https://us.sagepub.com/en-us/nam/open-access-at-sage).

367

Proper Methodology

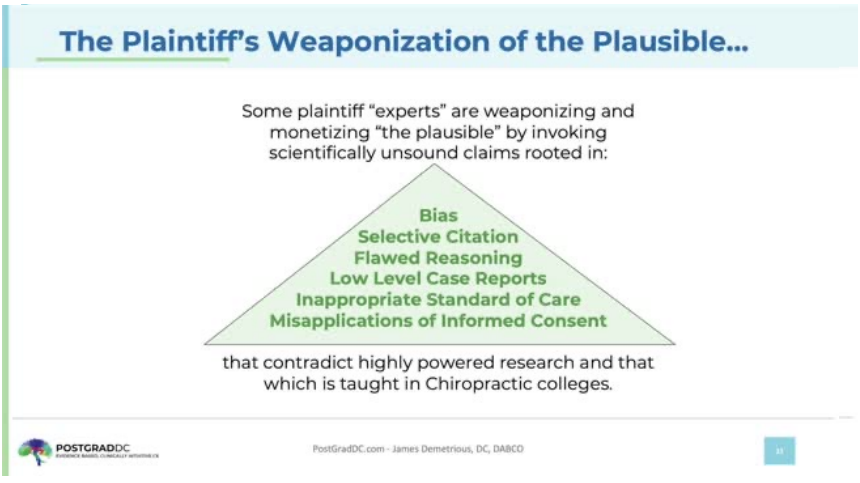

368

State Court of Fulton County
E-FILED
17EV004146
8/29/2017 5:36:43 PM
LeNora Ponzo, Clerk
Civil Division

IN THE STATE COURT OF FULTON COUNTY
STATE OF GEORGIA

JONATHAN BUCKELEW and CHRISTIN BUCKELEW,

Plaintiffs,

v.

MICHAEL AXT; ADVANCED INTEGRATIVE MEDICINE, INC.; MATTHEW WOMACK, MD; NORTH FULTON EMERGENCY PHYSICIANS, LLC; JAMES WALDSCHMIDT, MD; JAMES WALDSCHMIDT, MD, P.C.; PETER FUTRELL, MD; NORTH FULTON NEUROLOGY, P.C.; SACHIN LAVANIA, MD; CHRISTOPHER NICKUM; NORTH FULTON PULMONARY SPECIALISTS, LLC; NORTH FULTON MEDICAL CENTER, INC. d/b/a NORTH FULTON REGIONAL HOSPITAL; and TENET HEALTHCARE CORPORATION;

Defendants.

CIVIL ACTION FILE NO. _____

COMPLAINT

For their Complaint against Defendants, Plaintiffs, Jonathan Buckelew and Christin Buckelew, allege as follows:

FACTUAL ALLEGATIONS

18.

On October 26, 2015, in the afternoon, Jonathan Buckelew went to see Dr. Michael Axt, a chiropractor at Advanced Integrative Medicine, for complaints of neck pain. Dr. Axt recorded in his notes of that visit that Buckelew reported neck pain and headache for four days after working out at the gym. Dr. Axt also recorded in his notes that Buckelew reported bouts of blurred vision and ringing in the ears.

19.

Dr. Axt indicated in his notes that he adjusted Buckelew's neck while

6

Buckelew was lying down and then asked Buckelew to sit up. Dr. Axt noted that when Buckelew sat up he reported that he felt dizzy, and he seemed disoriented. Dr. Axt then left Buckelew and went to find help. When he returned, Buckelew appeared less responsive and Axt called 911.

369

20.

It appears that 911 was called at 3:53 pm on October 26, 2015, and Buckelew was then transported by ambulance to North Fulton Hospital where he arrived at approximately 4:20 pm.

21.

When Buckelew arrived at the emergency department, he was alert and oriented to person, place, time and situation and was in no acute distress. His Glasco Coma Scale score was recorded at 11 and his pupils were equal, round and reactive to light.

22.

Buckelew was first seen by emergency department physician, Dr. Matthew Womack, and at 4:39 pm, Dr. Womack ordered a CT of the brain and a CTA of the neck.

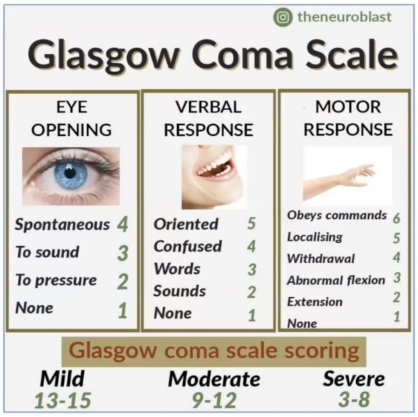

370

23.

The CT and CTA were performed at around 5:15 pm and the CTA was read

7

by neuroradiologist, Dr. James Waldschmidt. Dr. Waldschmidt dictated his findings at 6:46 pm. The clinical indication listed by Dr. Womack for the CTA study was "pain/disscetion" (sic).

24.

In Dr. Waldschmidt's report on the CTA, he noted, among other things, a potential dissection of the right vertebral artery.

25.

In fact, the imaging study showed that the right vertebral artery was very small in caliber and abnormalities in both vertebral arteries.

26.

The study showed thrombosis of the basilar artery.

27.

After Dr. Womack read Dr. Waldschmidt report, he called Dr. Futrell, the neurologist on call, for a neurology consultation.

28.

Dr. Womack recorded in his notes that at approximately 6:50 pm he discussed with Dr. Futrell the findings on both the CT and the CTA and that Dr. Futrell recommended a lumbar puncture to rule out meningitis and or encephalitis and recommended that the patient be admitted.

8

29.

Dr. Futrell later records, on October 29, 2015, in his notes, that Dr. Womack did not discuss the CTA with him and that he in fact did not know that a CTA had been performed. He notes that he has checked his phone log and that the phone call with Dr. Womack took place before the results of the CTA were available. He also notes that Dr.Womack never told him that the patient had just been to a chiropractor.

371

30.

Before the lumbar puncture was performed, Dr. Womack witnessed Buckelew have what he described as a seizure, and intubated Buckelew at 7:27 pm.

31.

Dr. Womack then performed a lumbar puncture. The lumbar puncture showed normal opening pressure and clear cerebral spinal fluid. Dr. Womack ordered the CSF fluid to be examined STAT.

32.

Dr. Womack then contacted the critical care service and spoke to Christopher Nickum, a Physicians Assistant working with Dr. Sachin Lavinia, a critical care specialist working in the ICU.

9

33.

It appears that either Dr. Lavania and or Mr. Nickum saw and examined Buckelew at around 8:30 pm on October 26, while Buckelew was still in the emergency department, and dictated a History and Physical for his admission into the ICU. It is noted in the history and physical that although Buckelew was somnolent, he was arousable while in the ER and was still following commands. At the time of the History and Physical, Buckelew was sedated and intubated and a neurological exam was not recorded. ?

34.

At 9:00 pm the results of the analysis of the CSF from the lumbar puncture were reported as normal. However, it appears that the results of the CSF tests were not reported to Dr. Womack or to the emergency department.

35.

Buckelew was discharged from the emergency department and transferred to the ICU at 10:56 pm with a diagnoses of encephalitis and altered mental status, without mention of the normal CSF findings.

372

36.

In the ICU the nurses note at 12:20 am that Buckelew's pupils are sluggish.

10

37.

Once in the ICU it appears that Buckelew was not seen or evaluated by a physician until the following morning, sometime after 10:00 am, when he was seen by Dr. Lavania who at that time ordered an MRI of the brain as well as an MRA.

38.

The MRA demonstrated a massive non-hemorrhagic stroke of the posterior circulation of the brain, including thrombosis of the basilar artery which had blocked circulation to the pons and to both hemispheres of the brain.

39.

The MRA was read at around 1:00 pm and the results discussed with Dr. Drexinger of Neurology and Dr. Lavania. At 1:37 pm on October 27, 2015, the first treatment for stroke, a heparin drip, was initiated, over 21 hours after Buckelew arrived at North Fulton Hospital.

40.

The heparin drip was ineffective in resolving any of the damage done by the lack of blood flow to areas of Buckelew's brain.

41.

Because of the delay in diagnoses, no other treatment options were

11

available.

373

42.

Mr. Buckelew sustained extensive and permanent brain damage as a result of the delay in diagnoses and treatment of his stroke. He is unable to move any part of his body other than his eyes, but is cognitively intact. This condition, known as Locked-in syndrome (LIS), is permanent and non-reversible.

43.

Mr. Buckelew has expended millions of dollars for medical expenses for his care and he will need 24 hour a day care for the rest of his life.

374

Salient Points that Led to the Verdict...

- Plaintiff's attorney Shamp told jurors **ER doctor Womack knew Buckelew had symptoms of a stroke.**
- But she said he **failed to tell neurologist** Futrell that Buckelew had a chiropractic neck adjustment - which is a stroke risk - or properly communicate the results of imaging.
- Shamp added Womack later **altered medical records** when he learned of Buckelew's true condition.
- Meanwhile, she said, radiologist **Waldschmidt admitted** that he **missed seeing the stroke when examining imaging.**
- Further, Shamp argued, **breakdowns in communication** between those and other defendants all led to Buckelew's paralysis.

375

The Verdict



State Court of Fulton County
"E-FILED"
17EV004146
10/20/2022 5:30 PM
Donald Talley, Clerk
Civil Division

IN THE STATE COURT OF FULTON COUNTY
STATE OF GEORGIA

JONATHAN BUCKELEW,
Plaintiff
v.
MATTHEW WOMACK, MD; NORTH FULTON EMERGENCY PHYSICIANS, LLC; JAMES WALDSCHMIDT, MD; JAMES WALDSCHMIDT, MD, P.C.; PETER FUTRELL, MD; NORTH FULTON NEUROLOGY, P.C.; CHRISTOPHER NICKUM; NORTH FULTON PULMONARY SPECIALISTS, LLC; and NORTH FULTON MEDICAL CENTER, INC. d/b/a NORTH FULTON REGIONAL HOSPITAL,
Defendants.

CIVIL ACTION NO. 17EV004146
JUDGE ERIC RICHARDSON

VERDICT

We, the jury, return the following verdict:

PART A – LIABILITY:

1. Do you find by clear and convincing evidence that MATTHEW WOMACK, MD was grossly negligent, and find by a preponderance of the evidence that such gross negligence was a proximate cause of injury to Plaintiff?
   Yes ✓ No
   If you answered "YES" to Question 1, proceed to Questions 2 through 7. If you answered "NO" to Question 1, skip Question 2 and proceed to Questions 3 through 7.
2. Do you find that MATTHEW WOMACK, MD, at the time he provided care and treatment to Jonathan Buckelew, was as an employee and NOT an independent contractor of North Fulton Emergency Physicians, LLC?
   Yes No ✓

Page 1 of 3



3. Do you find by clear and convincing evidence that JAMES WALDSCHMIDT, MD was grossly negligent, and find by a preponderance of the evidence that such gross negligence was a proximate cause of injury to Plaintiff?
   Yes ✓ No
4. Do you find by clear and convincing evidence that PETER FUTRELL, MD was grossly negligent, and find by a preponderance of the evidence that such gross negligence was a proximate cause of injury to Plaintiff?
   Yes No ✓
5. As to CHRISTOPHER NICKUM:
   a) Do you find by clear and convincing evidence that CHRISTOPHER NICKUM was grossly negligent while Jonathan Buckelew was in the Emergency Department, and find by a preponderance of the evidence that such gross negligence was a proximate cause of injury to Plaintiff?
   Yes No ✓
   b) Do you find by a preponderance of the evidence that CHRISTOPHER NICKUM was negligent while Jonathan Buckelew was in the Intensive Care Unit, and find by a preponderance of the evidence that such negligence was a proximate cause of injury to Plaintiff?
   Yes No ✓
6. Do you find by a preponderance of the evidence that NORTH FULTON MEDICAL CENTER, INC., by and through its ICU nurses, was negligent, and find by a preponderance of the evidence that such negligence was a proximate cause of injury to Plaintiff?
   Yes No ✓
7. Do you find by a preponderance of the evidence that non-party MICHAEL AXT, DC was negligent, and find by a preponderance of the evidence that such negligence was a proximate cause of injury to Plaintiff?
   Yes No ✓
   If you answered "Yes" to any of Questions 1-7, please continue and answer all of the remaining questions in the verdict form. If you answered "No" to all of Questions 1-7, STOP here and sign the verdict form.

Page 2 of 3



PART B – DAMAGES:

We the jury award Plaintiff Jonathan Buckelew

Past Medical Expenses in the amount of $ 9,000,000
Future Medical Expenses in the amount of $ 20,000,000
Past and Future Pain and Suffering in the amount of $ 40,000,000

PART C – APPORTIONMENT OF FAULT

We find the percentages of fault as follows:

If you checked "NO" for any Defendant(s) or non-party in Part A, you should place a "0" beside that Defendant or non-party. If you checked "YES" in Part A for any Defendant(s) or non-party, you should find a percentage for each of those Defendant(s) or non-party that you found against. The total of the percentages must equal 100%.

60% MATTHEW WOMACK, MD and NORTH FULTON EMERGENCY PHYSICIANS LLC.
40% JAMES WALDSCHMIDT, MD and JAMES WALDSCHMIDT M.D., P.C.
0 PETER FUTRELL, MD and NORTH FULTON NEUROLOGY, P.C.
0 CHRISTOPHER NICKUM and NORTH FULTON PULMONARY SPECIALISTS, LLC.
0 NORTH FULTON MEDICAL CENTER, INC.
0 MICHAEL AXT, DC

SO SAY WE ALL this 20 **day of October, 2022.**

CAROL SHAMON
FOREPERSON (print name)
FOREPERSON (sign name)

Page 3 of 3

376

The Verdict

- After a 3-week trial, the jury delivered a plaintiff's verdict in the amount of $75 million:
  - $29 million in medical expenses;
  - $46 million in non-economic damages.
- Fault:
  - ER Physician – 60%;
  - Radiologist – 40% - for missing the arterial blockage causing the stroke on images.
  - Chiropractor - 0% - Amicable resolution?

377

Known/Unknown Case Bullets

- Male, 32 years old;
  - Pre-existing risk factors?
- S/S: neck pain, headache, blurred vision, tinnitus for several preceding days;
  - More detail? Location, character, severity of neck and head pain? Prior Hx? Familial Hx?
  - Examination details?
  - Differential diagnosis? Recommendations? Informed consent discussion?

378

Known/Unknown Case Bullets

- Recumbent cervical spine adjustment with reported vertigo, disorientation, and subsequent patient later became less responsive;
  - Details of chiropractic care?
  - Assessment of new symptoms?
  - New differential assessment/discussion?

379

Known/Unknown Case Bullets

- Attending chiropractor called 911 and an ambulance transported the patient to North Fulton Medical Center:
  - Appropriate referral?
  - Conveyance of clinical impression and recommendations?
  - Follow up with attending medical providers and patient/family?
  - Documentation?

380

Cases Often Lack Vital Historic Information

yahoo!



Rebecca Barlow won a $1.1 million jury verdict for injuries caused by routine chiropractic adjustments.Jan. 28, 2023

By a 9-3 vote, the jury awarded her **$1,030,900**, including **$380,000** in medical expenses and **$750,000** for pain and suffering.

- **Error of Commission?:**
  - Treatment failure:
    - Excessive force?
    - Incorrect or poor technique?
- **Error of Omission?**
  - Failure to diagnose?
    - Failure to identify symptoms or signs?
    - Failure to identify risk factors including pre-existing genetic or acquired connective tissue disorders?
    - Failure to identify arteriopathy?
    - Exercised poor clinical acumen?
    - Failure to refer to MD?

381

Important Considerations?

- **Pre-existing predispositions?**
- **Prevalence and commonality of S/S?**
- Proper examination?
- Mechanisms of injury?:
  - Dissection/occlusion?;
  - sPSA or Thromboemboli?;
  - Coagulopathy – Heritable or acquired?;
- Temporal relationships?
- **An impossible diagnosis?**
  - Poor disclosure - despite best efforts?;
  - The asymptomatic dissection?
- Standard(s) of care?
- Recommendations?
- **Referral - Communication**
- Informed consent?

382

Focus on Susceptibility

Vascular Health and Risk Management Dovepress
open access to scientific and medical research
Open Access Full Text Article REVIEW

Cervical Artery Dissections: Etiopathogenesis and Management

Zafer Keser[1], Chia-Chun Chiang[1], John C Benson[2], Alessandro Pezzini[3], Giuseppe Lanzino[4]

[1]Department of Neurology, Mayo Clinic, Rochester, MN, USA; [2]Department of Radiology, Mayo Clinic, Rochester, MN, USA; [3]Department of Clinical and Experimental Sciences, Neurology Clinic, University of Brescia, Brescia, Italy; [4]Department of Neurosurgery, Mayo Clinic, Rochester, MN, USA

- **Pre-Existing Predispositions?**
  - Isolated mild connective tissue abnormalities in skeletal, ocular, and skin systems (i.e., joint hypermobility or multiple dislocations, easy bruising, poor wound healing, or easy bruising) are frequently observed in patients with spontaneous CeAD (**50–96%**).
    - Keser et al. Cervical Artery Dissections: Etiopathogenesis and Management Vascular Health and Risk Management. 2022:18 685–700.

383

Carotid vs. Vertebral Dissection S/S

Carotid Artery Dissection:

- Ipsilateral neck pain or headache and a,
- Partial Horner's followed by,
- Retinal or cerebral ischemia.

The presence of any 2 of the 3 elements in the triad strongly suggests the diagnosis of carotid dissection.

Vertebral Artery Dissection:

- Occipito-cervical pain, which may be followed by a variety of posterior circulation ischemic symptoms including;
- Vertigo;
- Dysarthria;
- Visual field deficit;
- Ataxia, and;
- Diplopia.

Arch Neurosci. 2015 October ; 2(4): . doi:10.5812/archneurosci.26670.

384

Prevalence and Commonality of S/S in the Population?

- **Headache - ages 18-44 - 18%**
  - Headache. 2018 Apr;58(4):496-505.
- **Neck pain – 30%**
  - Mayo Clin Proc. n February 2015;90(2):284-299.
- **Transient Visual Impairment – 34.5%**
  - Clin Ophthalmol. 2016; 10: 297–303.
- **Tinnitus – 9.6%**
  - JAMA Otolaryngol Head Neck Surg. 2016 Oct 1; 142(10): 959–965.
- **Vertigo – 20-56%**
  - Acta Otorhinolaryngol Ital. 2016 Jun; 36(3): 215–219.
- **Nausea and Vomiting - >50%**
  - https://www.wikidoc.org/index.php/Nausea_and_vomiting_epidemiology_and_demographics

385

An Impossible Diagnosis?

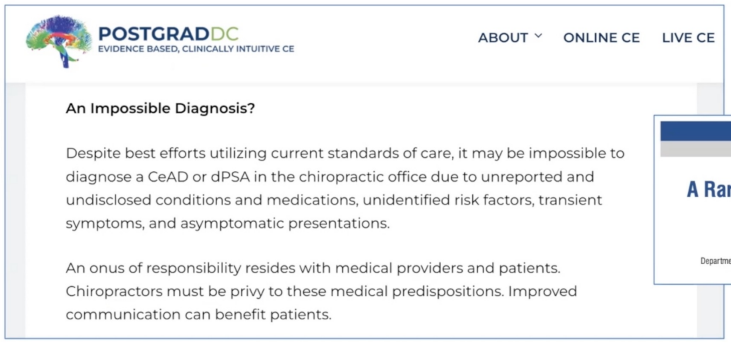

https://postgraddc.com/thromboembolism-stroke-demetrious-postgraddc-chiropractic/



Farouji I. J Emerg Trauma Shock 2021;14:240-2.

386

Referral - Communication

- Informed Consent Processes
- Clear Communication with Downstream Providers
- Follow-Up



State Court of Fulton County
E-FILED
17EV004[illegible]
8/29/2017 5:36:4[illegible] PM
LeNora Ponzo, Clerk
Civil Division

IN THE STATE COURT OF FULTON COUNTY
STATE OF GEORGIA

JONATHAN BUCKELEW and CHRISTIN BUCKELEW,

Plaintiffs,

v.

CIVIL ACTION FILE NO. _____

MICHAEL AXT; ADVANCED INTEGRATIVE MEDICINE, INC.; MATTHEW WOMACK, MD; NORTH FULTON EMERGENCY PHYSICIANS, LLC; JAMES WALDSCHMIDT, MD; JAMES WALDSCHMIDT, P.C.; PETER FUTRELL, MD; NORTH FULTON NEUROLOGY, P.C.; SACHIN LAVANIA, MD; CHRISTOPHER NICKUM; NORTH FULTON PULMONARY SPECIALISTS, LLC; NORTH FULTON MEDICAL CENTER, INC. d/b/a NORTH FULTON REGIONAL HOSPITAL; and TENET HEALTHCARE CORPORATION;

Defendants.

Poor Communication?

387

The Process of Informed Consent



James Demetrious, DC, DABCO
Diplomate, American Board of Chiropractic Orthopedists
4837 Carolina Beach Road, Suite 205 • Wilmington, NC 28412 • Telephone: 910-790-8020

Informed Consent Document

Patient's Name: _____

It is our goal to help you to the best of our ability. Please read this entire document prior to signing it. It is important that you understand the information contained in this document. Please ask questions before you sign if there is anything that is unclear.

What to Expect

With your permission, Dr. Demetrious will carefully assess your health. He will talk with you about your health history, examine you, consider and order necessary tests based on standards of practice and his clinical experience. He will develop a differential diagnosis and make recommendations for care. With your consent, he will provide you care to the best of his ability.

Chiropractic Care

The primary treatment offered by Dr. Demetrious is chiropractic adjustments. He may use his hands or a mechanical instrument upon your body in such a way as to move your joints. That may cause a "pop" or "crack" sensation. You may feel a sense of movement. If you feel discomfort with any adjustment, please inform Dr. Demetrious.

The most common side effect of chiropractic care is soreness and stiffness following the first few days of treatment. Sometimes patients experience headache. This is usually short-term discomfort that is followed by relief.

Risks Inherent to Chiropractic Care

Disc herniations, pinched nerves, arthritic change, and spinal biomechanical issues are very common in many people. Many patients without symptoms have these problems and then aggravate their conditions through their activities of daily living causing them to seek chiropractic care.

Rarely complications from chiropractic care include but are not limited to fractures, disc injuries, dislocations, muscle strain, spinal cord injury, rib, and joint pain. Arterial dissections and stroke are rare and can lead to death and paralysis. The most current biomechanical research reveals that chiropractic care does not cause arterial dissections or stroke. It has been reported that patients with arterial dissections experience neck pain, headache, and neurologic symptoms that cause them to see chiropractic care. We do our best to be assured that you do not have a developing dissection or stroke.

Please inform us of any risk factors or health issues prior to and during your care:

___ Connective tissue disorder, loose joints, Ehlers-Danlos, or Marfan syndrome?
___ Recent head or neck trauma?
___ Worst headache of your life?
___ Elevated homocysteine?
___ Recent infection?
___ Fluoroquinolone medication in the past (Cipro, Levaquin, Levofloxacin, Noroxin, Avelox, etc.)?
___ Trouble seeing or blurred vision?
___ Dizziness?
___ Difficulty talking, difficulty swallowing?
___ Nausea?
___ Numbness or loss of sensation?
___ Change in bladder or bowel function?
___ Weakness of face, arm, or leg?
___ Difficulty walking?
___ Atrial fibrillation or atrial septal defect?
___ Coagulation disorders or medicines?

This Document is a work in progress. Improvements are necessary.

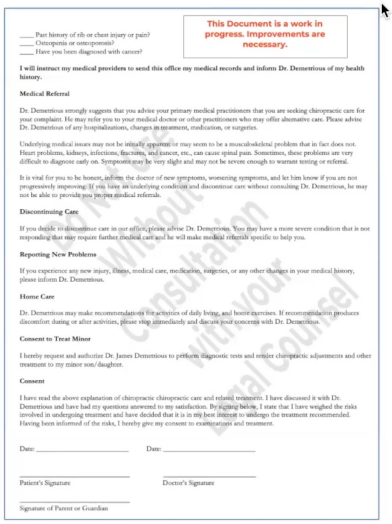

___ Past history of rib or chest injury or pain?
___ Osteopenia or osteoporosis?
___ Have you been diagnosed with cancer?

This Document is a work in progress. Improvements are necessary.

I will instruct my medical providers to send this office my medical records and inform Dr. Demetrious of my health history.

Medical Referral

Dr. Demetrious strongly suggests that you advise your primary medical practitioners that you are seeking chiropractic care for your complaint. He may refer you to your medical doctor or other practitioners who may offer alternative care. Please advise Dr. Demetrious of any hospitalizations, changes in treatment, medication, or surgeries.

Underlying medical issues may not be initially apparent or may seem to be a musculoskeletal problem that in fact does not. Heart problems, kidneys, infections, fractures, and cancer, etc., can cause spinal pain. Sometimes, these problems are very difficult to diagnose early on. Symptoms may be very slight and may not be severe enough to warrant testing or referral.

It is vital for you to be honest, inform the doctor of new symptoms, worsening symptoms, and let him know if you are not progressively improving. If you have an underlying condition and discontinue care without consulting Dr. Demetrious, he may not be able to provide you proper medical referrals.

Discontinuing Care

If you decide to discontinue care in our office, please advise Dr. Demetrious. You may have a more severe condition that is not responding that may require further medical care and he will make medical referrals specific to help you.

Reporting New Problems

If you experience any new injury, illness, medical care, medications, surgeries, or any other changes in your medical history, please inform Dr. Demetrious.

Home Care

Dr. Demetrious may make recommendations for activities of daily living, and home exercises. If recommendation produces discomfort during or after activities, please stop immediately and discuss your concerns with Dr. Demetrious.

Consent to Treat Minor

I hereby request and authorize Dr. James Demetrious to perform diagnostic tests and render chiropractic adjustments and other treatment to my minor son/daughter.

Consent

I have read the above explanation of chiropractic chiropractic care and related treatments. I have discussed it with Dr. Demetrious and have had my questions answered to my satisfaction. By signing below, I state that I have weighed the risks involved in undergoing treatment and have decided that it is in my best interest to undergo the treatment recommended. Having been informed of the risks, I hereby give my consent to examinations and treatment.

Date: _____ Date: _____

_____ _____
Patient's Signature Doctor's Signature

_____
Signature of Parent or Guardian

388

Challenges...

- **Protect our Patients**
  - Take Advanced CE
- **Can Plaintiff's Attorneys make us Look Foolish?**
  - Exceed the "Standard of Care"
- **Protopathic Bias and Bad Science?**
  - Refute Bad Science
- **Association vs. Cause?**
  - Define Predispositions/Apportionment
- **Errors of Omission or Commission?**
  - Exceed the "Standard of Care"
- **Asymptomatic Population?**
  - Identify Predispositions and S/S
- **Limitations in Research:**
  - Be Prepared
- **Temporality of Event?**
  - EB Causality?
- **Informed Consent?**
  - It is a Constant Discussion and Process
- **Emergent Care**
  - Make/Document Emergent Referrals

389

Case Reports are Weak

- With a deficit of highly powered research, plaintiffs' attorneys and expert witnesses utilize case reports to substantiate their claims.
- Case reports offer weaknesses that include the inability to generalize results or to assess causality. [1]
- Journals, editorial boards, authors, expert witnesses, plaintiff attorneys, and patients should refrain from assigning causality based on information gleaned from case reports.

1.) Lowenfels et al. Grad Med Educ (2022) 14 (5): 529–532.



CASE REPORT

Self-Chiropractic Cervical Spinal Manipulation Resulting in Fatal Vertebral Artery Dissection

A Case Report and Review of the Literature

Cameron Fink, BHS, Clare H. Bryce, MD,* and Laura D. Knight, MD*†*

390

Standard of Care

Innovations in CLINICAL NEUROSCIENCE
A peer-reviewed journal providing evidence-based information

Innov Clin Neurosci. 2021 Jul-Sep; 18(7-9): 50–51. PMCID: PMC8667701
PMID: 34980995

The Standard of Care

Donna Vanderpool, MBA, JD[a]

- The standard of care is a legal term that refers to the degree of care a prudent and reasonable person would exercise under the circumstances.
- Very few states have retained the locality standard...
- Note that the standard of care is not optimal care. Rather, it is a continuum, with barely acceptable care at one end, and the ultimate in care at the other end.

391

HHS Public Access
Author manuscript
Arch Neurosci. Author manuscript; available in PMC 2015 October 14.

Published in final edited form as:
Arch Neurosci. 2015 October ; 2(4): . doi:10.5812/archneurosci.26670.

Cervical Artery Dissection: A Review of the Epidemiology, Pathophysiology, Treatment, and Outcome

Christina A. Blum[1] and **Shadi Yaghi**[2]
[1] University of Pennsylvania Health System, Department of Neurology, Stroke division
[2] Columbia University Medical Center, Department of Neurology, Stroke division

Conclusion

Given the relatively rare incidence of this disease, multicenter studies and meta-analyses with collaborative effort among stroke centers worldwide should be considered to enroll patients with cervical artery dissection in a randomized trial comparing the two treatments. This may provide the foundation for an evidence-based approach to the evaluation and treatment of this disease.

392

Diligence to Identify a Developing CAD...

- Patients may present to physicians with developing CADs.
- While rare and difficult to diagnose the developing CAD, it is vitally important to exert clinical diligence.
- The result of an undiagnosed CAD and resultant stroke can be catastrophic:
  - Death
  - Infarcts
  - Paralysis
  - Locked-in Syndrome

393

If Possible...Let's Study Harder to Protect Our Patients...



394

POSTGRADDC
EVIDENCE BASED, CLINICALLY INTUITIVE CE

Demetrious CeAD-R³ Clinical Algorithm

James Demetrious, DC, DABCO
Diplomate, American Board of Chiropractic Orthopedists

www.PostGradDC.com

395

Syllabus

- CeAD Misdiagnosis/Delays
- **Recognition-Risk-Referral**
- Predictor Domains
- Follow-Up

396

Purpose

Current research indicates that chiropractic care is NOT causal of CeAD.

However, it is imperative to improve graduate and postgraduate education in the detection of a dissection, ischemic or stroke events.

Healthcare providers must receive active training to identify susceptibility, recognize impending events, initiate emergency referrals, monitor and support patients while waiting for EMS, and communicate with emergency support personnel and physicians.

397

Demetrious CeAD-R³ Clinical DDX Algorithm

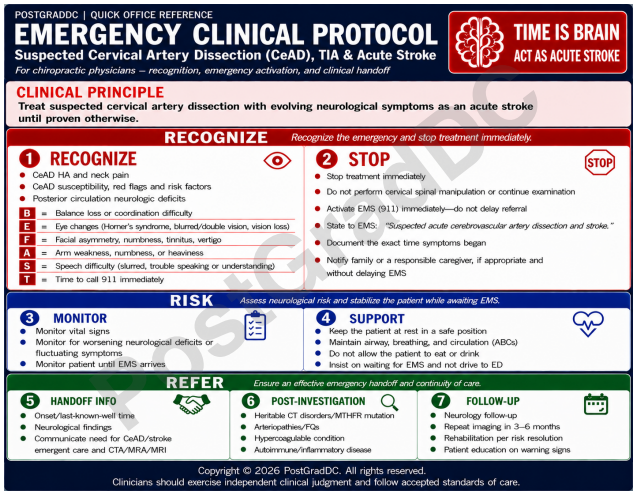

To Be Validated

398

Demetrious CeAD-R³ Clinical DDX Algorithm

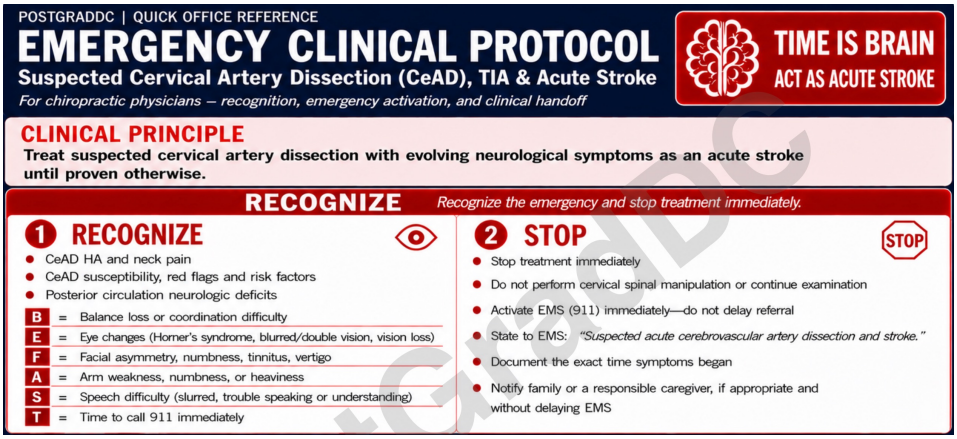

To Be Validated

399

Demetrious CeAD-R³ Clinical DDX Algorithm

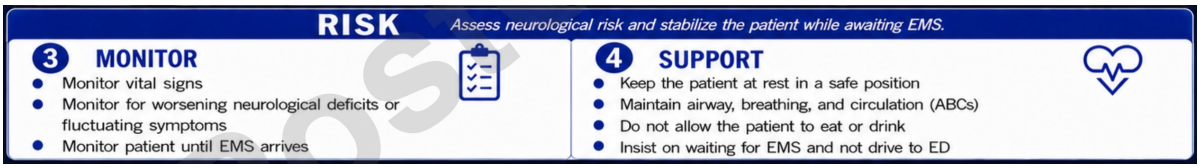

To Be Validated

400

Demetrious CeAD-R³ Clinical DDX Algorithm

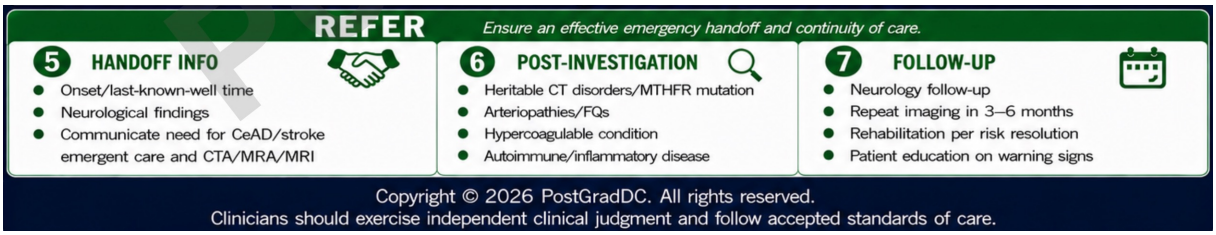

To Be Validated

401

Demetrious CeAD-R³ Clinical Algorithm



- 3.1% (218 of 7,090 patients; 95% CI 2.7%–3.5%) had a probable delayed or missed emergency department diagnosis within the 14 days preceding the diagnosis of cervical artery dissection.
- Because outpatient delays, false-negative imaging, and prolonged diagnostic intervals were not captured, this figure likely underestimates the true frequency of delayed recognition.

Liberman et al. Misdiagnosis of Cervicocephalic Artery Dissection in the Emergency Department. Stroke. 2020 (6):1876-1878.

402

Delays in CeAD Diagnosis



Check for updates

Misdiagnosis of Cervicocephalic Artery Dissection in the Emergency Department

Ava L. Liberman, MD; Babak B. Navi, MD, MS; Charles C. Esenwa, MD, MS; Cenai Zhang, MS; Justin Song, BS; Natalie T. Cheng, MD; Daniel L. Labovitz, MD; Hooman Kamel, MD; Alexander E. Merkler, MD

Background and Purpose—Cervicocephalic artery dissection is an important cause of stroke. The clinical presentation of dissection can resemble that of benign neurological conditions leading to delayed or missed diagnosis.

Methods—We performed a retrospective cohort study using statewide administrative claims data from all Emergency Department visits and admissions at nonfederal hospitals in Florida from 2005 to 2015 and New York from 2006 to 2015. Using validated *International Classification of Diseases, Ninth Revision, CM* codes, we identified adult patients hospitalized for cervicocephalic artery dissection. We defined probable misdiagnosis of dissection as having an Emergency Department treat-and-release visit for symptoms or signs of dissection, including headache, neck pain, and focal neurological deficits in the 14 days before dissection diagnosis. Multivariable logistic regression was used to compare adverse clinical outcomes in patients with and without probable misdiagnosis.

Results—Among 7090 patients diagnosed with a dissection (mean age 52.7 years, 44.9% women), 218 (3.1% [95% CI, 2.7%–3.5%]) had a preceding probable Emergency Department misdiagnosis. After adjustment for demographics and vascular risk factors, there were no differences in rates of stroke (odds ratio, 0.82 [95% CI, 0.62–1.09]) or in-hospital death (odds ratio, 0.26 [95% CI, 0.07–1.08]) between dissection patients with and without a probable misdiagnosis at index hospitalization.

Conclusions—We found that ≈1 in 30 dissection patients was probably misdiagnosed in the 2 weeks before their diagnosis. (***Stroke.* 2020;51:1876-1878. DOI: 10.1161/STROKEAHA.120.029390.)**

Key Words: diagnosis ■ diagnostic errors ■ dissection ■ headache

Cervicocephalic artery dissection is uncommon in the general population but a frequent cause of stroke in the young.[1,2] While many patients with cervicocephalic artery dissection present with cerebral ischemia, symptoms can be nonspecific including isolated headache and cervical pain.[3,4]

Rates of cervicocephalic artery dissection misdiagnosis in the Emergency Department (ED) have not been systematically evaluated despite the fact that early identification of dissection represents an important opportunity for stroke prevention.[5] We, therefore, sought to measure the rate of cervicocephalic artery dissection misdiagnosis in the ED using a large, heterogeneous cohort. We also evaluate the effect of probable ED misdiagnosis on the clinical outcomes of dissection patients.

Methods

The data that support the findings of this study are available from the corresponding author upon reasonable request.

Design

We conducted a retrospective cohort study using statewide administrative claims data collected by the Florida Agency for Health Care Administration and the New York Statewide Planning and Research Cooperative System (Methods in the Data Supplement). The Weill Cornell Medicine institutional review board approved this study and granted a waiver of informed consent.

Subjects

We identified all patients >18 years of age with an index hospitalization for cervicocephalic artery dissection using previously validated *International Classification of Diseases, Ninth Revision, Clinical Modification* (ICD-9-CM) diagnosis codes (Methods in the Data Supplement).

Measurements

We defined a probable ED misdiagnosis as having had an ED treat-and-release visit for signs and symptoms related to dissection in the 14 days before dissection hospitalization. ED visits for these signs and symptoms were identified using the primary *ICD-9-CM* discharge diagnosis codes detailed in Table 1 in the Data Supplement.

Received December 12, 2019; final revision received February 12, 2020; accepted February 29, 2020.

From the Department of Neurology, Montefiore Medical Center, Albert Einstein College of Medicine, Bronx, NY (A.L., C.C.E., N.T.C., D.L.L.); Albert Einstein College of Medicine, Montefiore Medical Center, Bronx, NY (J.S.); and Clinical and Translational Neuroscience Unit, Department of Neurology, Feil Family Brain and Mind Research Institute, Weill Cornell Medicine, New York, NY (B.B.N., C.Z., H.K., A.E.M.).

Correspondence to Ava L. Liberman, MD, Department of Neurology, Montefiore Medical Center, Albert Einstein College of Medicine, 3316 Rochambeau Ave., Bronx, NY 10467. Email avliberm@montefiore.org

© 2020 American Heart Association, Inc.

***Stroke* is available at https://www.ahajournals.org/journal/str** **DOI: 10.1161/STROKEAHA.120.029390**

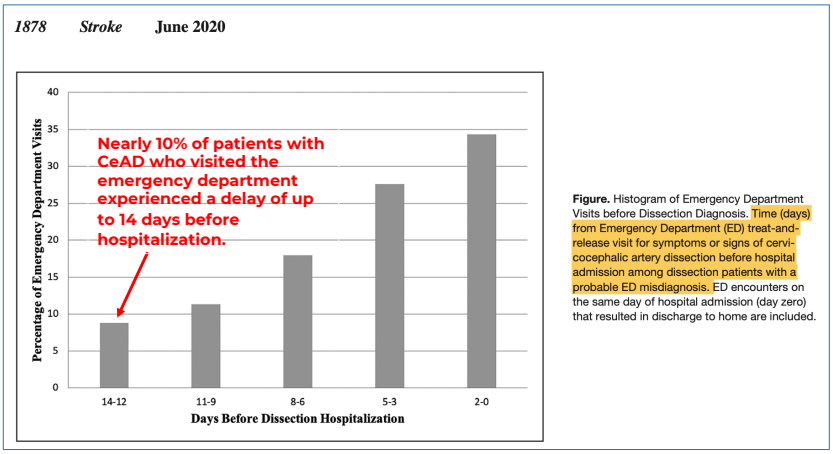

Figure. Histogram of Emergency Department Visits before Dissection Diagnosis. Time (days) from Emergency Department (ED) treat-and-release visit for symptoms or signs of cervicocephalic artery dissection before hospital admission among dissection patients with a probable ED misdiagnosis. ED encounters on the same day of hospital admission (day zero) that resulted in discharge to home are included.

403

Delays in CeAD Diagnosis



Check for updates

Misdiagnosis of Cervicocephalic Artery Dissection in the Emergency Department

Ava L. Liberman, MD; Babak B. Navi, MD, MS; Charles C. Esenwa, MD, MS; Cenai Zhang, MS; Justin Song, BS; Natalie T. Cheng, MD; Daniel L. Labovitz, MD; Hooman Kamel, MD; Alexander E. Merkler, MD

Background and Purpose—Cervicocephalic artery dissection is an important cause of stroke. The clinical presentation of dissection can resemble that of benign neurological conditions leading to delayed or missed diagnosis.

Methods—We performed a retrospective cohort study using statewide administrative claims data from all Emergency Department visits and admissions at nonfederal hospitals in Florida from 2005 to 2015 and New York from 2006 to 2015. Using validated *International Classification of Diseases, Ninth Revision, CM* codes, we identified adult patients hospitalized for cervicocephalic artery dissection. We defined probable misdiagnosis of dissection as having an Emergency Department treat-and-release visit for symptoms or signs of dissection, including headache, neck pain, and focal neurological deficits in the 14 days before dissection diagnosis. Multivariable logistic regression was used to compare adverse clinical outcomes in patients with and without probable misdiagnosis.

Results—Among 7090 patients diagnosed with a dissection (mean age 52.7 years, 44.9% women), 218 (3.1% [95% CI, 2.7%–3.5%]) had a preceding probable Emergency Department misdiagnosis. After adjustment for demographics and vascular risk factors, there were no differences in rates of stroke (odds ratio, 0.82 [95% CI, 0.62–1.09]) or in-hospital death (odds ratio, 0.26 [95% CI, 0.07–1.08]) between dissection patients with and without a probable misdiagnosis at index hospitalization.

Conclusions—We found that ≈1 in 30 dissection patients was probably misdiagnosed in the 2 weeks before their diagnosis. (***Stroke.* 2020;51:1876-1878. DOI: 10.1161/STROKEAHA.120.029390.)**

Key Words: diagnosis ■ diagnostic errors ■ dissection ■ headache

Cervicocephalic artery dissection is uncommon in the general population but a frequent cause of stroke in the young.[1,2] While many patients with cervicocephalic artery dissection present with cerebral ischemia, symptoms can be nonspecific including isolated headache and cervical pain.[3,4]

Rates of cervicocephalic artery dissection misdiagnosis in the Emergency Department (ED) have not been systematically evaluated despite the fact that early identification of dissection represents an important opportunity for stroke prevention.[5] We, therefore, sought to measure the rate of cervicocephalic artery dissection misdiagnosis in the ED using a large, heterogeneous cohort. We also evaluate the effect of probable ED misdiagnosis on the clinical outcomes of dissection patients.

Methods

The data that support the findings of this study are available from the corresponding author upon reasonable request.

Design

We conducted a retrospective cohort study using statewide administrative claims data collected by the Florida Agency for Health Care Administration and the New York Statewide Planning and Research Cooperative System (Methods in the Data Supplement). The Weill Cornell Medicine institutional review board approved this study and granted a waiver of informed consent.

Subjects

We identified all patients >18 years of age with an index hospitalization for cervicocephalic artery dissection using previously validated *International Classification of Diseases, Ninth Revision, Clinical Modification* (ICD-9-CM) diagnosis codes (Methods in the Data Supplement).

Measurements

We defined a probable ED misdiagnosis as having had an ED treat-and-release visit for signs and symptoms related to dissection in the 14 days before dissection hospitalization. ED visits for these signs and symptoms were identified using the primary *ICD-9-CM* discharge diagnosis codes detailed in Table 1 in the Data Supplement.

Received December 12, 2019; final revision received February 12, 2020; accepted February 29, 2020.

From the Department of Neurology, Montefiore Medical Center, Albert Einstein College of Medicine, Bronx, NY (A.L., C.C.E., N.T.C., D.L.L.); Albert Einstein College of Medicine, Montefiore Medical Center, Bronx, NY (J.S.); and Clinical and Translational Neuroscience Unit, Department of Neurology, Feil Family Brain and Mind Research Institute, Weill Cornell Medicine, New York, NY (B.B.N., C.Z., H.K., A.E.M.).

Correspondence to Ava L. Liberman, MD, Department of Neurology, Montefiore Medical Center, Albert Einstein College of Medicine, 3316 Rochambeau Ave., Bronx, NY 10467. Email avliberm@montefiore.org

© 2020 American Heart Association, Inc.

***Stroke* is available at https://www.ahajournals.org/journal/str** **DOI: 10.1161/STROKEAHA.120.029390**

- **Conclusions**
  - We found that ≈1 in 30 patients with cervicocephalic artery dissection had a probable ED misdiagnosis in the 14 days before their hospitalization for dissection.
  - **After adjustment for demographics and vascular comorbidities, probable ED misdiagnosis of dissection was not associated with increased odds of stroke or death at index hospitalization.**

404

Previous Algorithms...



A risk–benefit assessment strategy to exclude cervical artery dissection in spinal manual-therapy: a comprehensive review

Aleksander Chaibi and Michael Bjørn Russell



Clinical Neurology and Neurosurgery

Validation of a diagnostic support tool for early recognition of cervical arterial dissection in primary care

L. Thomas, M. Fowler, I. Marsh, K. Chu, Claire Muller, A. Wong

Limitations



?

405

Demetrious CeAD-R³ Clinical Algorithm

Cervical artery dissection should be understood as a **heterogeneous**, **multivariable** syndrome rather than a singular disease entity. Clinical presentation is governed by the **temporal** interplay of **predisposing factors**, **precipitating events**, **evolving symptoms**, and **progressive neurological findings,** not by a single, predictable natural history.

~ James Demetrious, DC, DABCO

406

Multivariate and Heterogenous



Cureus

Open Access Case Report

Recognition of Vertebral Artery Dissection in a High-Risk Postpartum Patient by a Chiropractic Physician

Abstract

Introduction

What Raises the Index of Suspicion from Commonality?



407

Demetrious CeAD-R³ Clinical Algorithm

- **CeAD-R³ Clinical Differential Diagnostic Algorithm**
  - **Recognition • Risk • Referral**
    - Differential Assessment of Patients Presenting with Headache, Neck Pain, Dizziness, and/or Neurological Symptoms

408

Demetrious CeAD-R³ Clinical DDX Algorithm

RECOGNITION – SYMPTOMS AND SIGNS

- **Identify the Clinical Presentation**
  - **Initial Presenting Complaint -** Evaluate any patient presenting with one or more of the following:
    - Sudden or progressive unilateral neck pain
    - New occipital headache
    - Severe unilateral headache
    - Facial pain
    - Dizziness or vertigo
    - Visual disturbance
    - Diplopia
    - Pulsatile tinnitus
    - Ataxia
    - Cranial nerve symptoms
    - Transient neurologic symptoms
    - Acute focal neurological deficits

409

Demetrious CeAD-R³ Clinical DDX Algorithm

RISK STRATIFICATION – ONSET AND PROGRESSION

- **Determine Symptom Evolution and Chronology**
  - Exact onset
  - Sudden vs gradual
  - Maximum intensity at onset?
  - Progressive worsening?
  - Intermittent symptoms
  - Recurrent transient episodes
  - New neurological progression
  - Pain preceding neurological symptoms
  - Hours-to-days-to weeks evolution

410

Demetrious CeAD-R³ Clinical DDX Algorithm

RISK STRATIFICATION – COMORBIDITIES

- **10 Predictor Domains**

1) Patient's Age
2) Comprehensive Medical History
   a. Heritable / Acquired Susceptibility
3) Symptom Onset
   a. Pain Characteristics/Location
4) Temporal Evolution
5) Non-Dissection Stroke Causation
6) Neurologic Findings:
7) Physical Examination
8) Prior Interventions / DX Tests
9) Compounded Co-Morbidities
10) Alternative Diagnoses

411

Demetrious CeAD-R³ Clinical DDX Algorithm

REFERRAL - FOLLOW-UP

- **Clinical Suspicion**
  - Referral Priorities - Low/Intermediate/High
  - Recommended Diagnostic Studies – ACR Criteria
  - Patient Instructions
  - Communication with Receiving personnel/facility
  - Follow-Up After Emergency Evaluation
    - Imaging?
    - Lab/Genetic testing?

412

Demetrious CeAD-R³ Clinical DDX Algorithm

Risk Stratification

- Risk stratification should represent the cumulative integration of all predictor domains rather than the presence or absence of any single finding.
- Cervical artery dissection is a heterogeneous, multivariable syndrome in which diagnostic probability increases as independently modest predictors converge into a coherent clinical pattern.
- Clinical decisions should therefore be based on the overall constellation of historical, neurological, physical examination, vascular susceptibility, and temporal features rather than isolated symptoms or individual risk factors.

413

Demetrious CeAD-R³ Clinical DDX Algorithm

- **Risk Stratification**
  - The integration of all predictor domains into an overall estimate of the probability that a patient's presentation represents evolving, established, or impending cervical artery dissection requiring urgent vascular imaging and specialist referral.

- Overall Clinical Probability
- Symptom Burden
- Neurological Burden
- Susceptibility (Risk) Burden
- Temporal Pattern
- Diagnostic Concordance
- Response to Previous Care
- Imaging Need
- Clinical Action Threshold
- Diagnostic Confidence
- Clinical Integration
- Risk Escalators

Emergent Referral

414

Demetrious CeAD-R³ Clinical DDX Algorithm



415

Demetrious CeAD-R³ Clinical DDX Algorithm

Predictor Domains

- **Domain 1**
  - Age – Young adults <50 years old
- **Domain 2**
  - Heritable/acquired susceptibility
- **Domain 3**
  - Symptoms Onset
- **Domain 4**
  - Temporal Evolution
- **Domain 5**
  - Non-Dissection Stoke Causation
- **Domain 6**
  - Neurologic S/S
- **Domain 7**
  - Physical Examination
- **Domain 8**
  - Prior Interventions
- **Domain 9**
  - Compounded Co-Morbidities
- **Domain 10**
  - Alternative Diagnoses

416

Demetrious CeAD-R³ Clinical DDX Algorithm

RISK STRATIFICATION

- **Predictor Domain 1**
  - Age – Young adults <50 years old

Yaghi et al. Stroke. 2024;55:e91–e106. DOI: 10.1161/STR.0000000000000457

417

Demetrious CeAD-R³ Clinical DDX Algorithm

- **Predictor Domain 2**
  - **Dissection - Heritable Susceptibility:**
    - Assess for inherited conditions associated with arterial fragility or connective tissue abnormalities:
      - Previous cervical artery dissection or spontaneous arterial dissection
      - Family history of cervical artery dissection, aneurysm, early stroke, or arterial rupture
      - Heritable connective tissue disorders (e.g., vascular Ehlers-Danlos syndrome, Marfan syndrome, Loeys-Dietz syndrome)
      - Fibromuscular dysplasia
      - Known inherited arteriopathy or vascular dysplasia
      - Personal or family history of spontaneous arterial aneurysms
      - Congenital vascular anomalies
      - Genetic disorders affecting collagen or elastin integrity
      - Multiple unexplained vascular events at a young age
      - History suggestive of generalized connective tissue laxity or fragility

418

Demetrious CeAD-R³ Clinical DDX Algorithm



Open access Systematic review

SVN Stroke & Vascular Neurology

Risk factors for cervical artery dissection: a systematic review with meta-analysis

Wilco Jacobs ,[1,2] Debbie S Wright,[3] Katherine Pohlman ,[3] Rob Rosenbaum,[4] Barbara A Hutten,[5] Gwendolyne GM Scholten-Peeters,[6] Scott Haldeman,[7] Johannes CF Ket,[8] Sidney M Rubinstein [9,10]

To cite: Jacobs W, Wright DS, Pohlman K, *et al*. Risk factors for cervical artery dissection: a systematic review with meta-analysis. *Stroke & Vascular Neurology* 2025;0. doi:10.1136/svn-2025-004186

► Additional supplemental material is published online only. To view, please visit the journal online (https://doi.org/10.1136/svn-2025-004186).

Received 5 March 2025
Accepted 16 July 2025

ABSTRACT

Background Cervical artery dissection (CAD) is a rare cause of stroke. This is an update of an earlier systematic review, which focuses on the risk of CAD in the general population. The objective was to identify the risk factors for CAD.

Methods A comprehensive search was conducted in MEDLINE, EMBASE and Web of Science on 20 September 2024. Observational studies (cohort, case-control studies and case-crossover studies) that studied patients with CAD and a control group were included. Risk of bias was assessed with the ROBINS-E tool, and certainty of the evidence was assessed using Grading of Recommendations Assessment, Development and Evaluation (GRADE). The results were stratified by healthy controls (primary analyses) and other control groups, notably ischaemic non-CAD stroke (secondary analyses).

Findings In total, 128 study reports were identified, of which 54 used one or more healthy control groups. Of these reports, 49 (91%) used a case-control design. The risk of bias was generally high (93%). For the following categories, effects were identified: (1) genetic factors or factors with a familial predisposition: migraine, methylenetetrahydrofolate reductase (MTHFR), TT homozygosity, matrix metalloproteinases (MMP) concentration, and connective tissue disorders; (2) external factors: recent infection, winter or autumn–winter season and oral contraceptive use; (3) minor trauma; (4) cardiovascular factors: hypertension, hypercholesterolaemia, relative vasodilatation of internal carotid, coronary artery disease and other cardiac diseases. For other risk factors (5), there were no significant pooled estimates. The certainty of the evidence was moderate for migraine and MTHFR TT, low for minor trauma and very low certainty for all others.

Interpretation This is the first review that comprehensively examined the risk of CAD in the general population. Genetic factors, cardiovascular risk factors, recent infection and minor trauma are risk factors for CAD. Caution is needed in interpretation as the evidence is overall low to very low certainty, except for migraine and MTHFR TT homozygosity.

WHAT IS ALREADY KNOWN ON THIS TOPIC

⇒ Cervical artery dissection (CAD) is a rare vascular pathology which affects about 8 in 100 000 young and otherwise healthy people per year. A recent study suggests that most are asymptomatic, with up to two of 100 cases of CAD resulting in ischaemic intracerebral stroke.

⇒ Several potential risk factors of CAD have been suggested based on case series and cross-sectional studies using all source stroke populations as controls. Still, a comprehensive review of risk factors in the general population is lacking as many of these studies based on stroke populations have a high risk of bias.

WHAT THIS STUDY ADDS

⇒ We included cohort, case-crossover studies and case-control studies with healthy control groups or stroke control groups.

⇒ Genetic factors, cardiovascular risk factors, recent infection and minor trauma are risk factors for CAD in the general population. The best evidence with a moderate level of certainty shows that migraine and methylenetetrahydrofolate reductase TT homozygosity are important risk factors for CAD.

HOW THIS STUDY MIGHT AFFECT RESEARCH, PRACTICE OR POLICY

⇒ Knowledge of risk factors may help identify those at risk of CAD and may assist general practitioners in clinical reasoning and determining when to refer patients for hospital care.

INTRODUCTION

Cervical artery dissection (CAD) is a vascular condition involving a false, blood-filled lumen between the vessel wall layers, most commonly occurring in the vertebral and carotid arteries.[1] Spontaneous CAD refers to occurrence without obvious major trauma. Knowledge about the incidence of CAD is limited due to the underdiagnosis of asymptomatic cases. In the healthy adult population, CAD occurs at a rate of 8.95 per 100 000 person-years,[2] while CAD accompanied by stroke occurs at a rate of 2.97 per 100 000 person-years.[3] Between 0 and 15.5% of adult CAD patients experience a stroke within the first 8 weeks,[4–6] but this estimate is dependent on the hospital setting with stroke centres

Stroke and Vascular Neurology: first published as 10.1136/svn-2025-004186 on 2 Protected by copyright, including for uses

Table 1 Summary of findings table: Genetic factors or factors with a familial predisposition

Risk factor	Pooled estimate (95% CI)	Number of participants (Studies)	Certainty of the evidence (GRADE)*	Comments
MMP lab (SMD)	2 (0.74 to 3.27)	356 (2)[25 43]	Very low[1 2 6]	
Connective tissue disorder (OR)	2.21 (1.06 to 4.59)	485 (3)[37 42 50]	Very low[1 4 6]	
Migraine (OR)	2.34 (1.58 to 3.48)	2218 (5)[18 27 30 36 52]	Moderate[1 6 7]	
MTHFR TT (OR)	2.94 (1.8 to 4.78)	533 (3)[54 57 58]	Moderate[1 6 8]	
Extra cellular Matrix regulating genes (OR)	3.59 (0.49 to 26.3)	33610 (2)[33 48]	Very low[1 2 4]	
TGFB genes (OR)	–	134630 (2)[33 55]	Very low[1 2 4 6]	Too few observations, individual studies used Fisher exact analyses

Summary of findings: Risk factors for cervical artery dissection - Genetic factors or factors with a familial predisposition.
Patient population: Patients with cervical artery dissection with or without stroke Exposed (Control) populations: General healthy population
Outcome: Cervical artery dissection.
GRADE Working Group grades of evidence: High certainty: We are very confident that the true effect lies close to that of the estimate of the effect. Moderate certainty: We are moderately confident in the effect estimate: The true effect is likely to be close to the estimate of the effect, but there is a possibility that it is substantially different. Low certainty: Our confidence in the effect estimate is limited: The true effect may be substantially different from the estimate of the effect. Very Low certainty: We have very little confidence in the effect estimate: The true effect is likely to be substantially different from the estimate of effect.
*Downgraded for 1 Risk of bias 2 Inconsistency 3 Indirectness 4 Imprecision 5 Publication bias. Upgraded for 6 Large effect 7 Plausible residual confounding 8 Dose response gradient
MMP, matrix metalloproteinases; MTHFR, methylenetetrahydrofolate reductase; OR, odds ratio; SMD, standardised mean difference; TGFB, transforming growth factor β.

419

Demetrious CeAD-R³ Clinical DDX Algorithm

- **Predictor Domain 2**
  - **Dissection - Acquired Susceptibility:**
- Evaluate medical conditions and exposures that may increase the likelihood of cervical artery dissection:
- Hypertension
- Migraine (particularly migraine with aura)
- Recent upper respiratory or systemic infection
- Pregnancy or postpartum state
- Preeclampsia or eclampsia
- Recent major surgery or invasive vascular procedures
- Recent minor cervical trauma or repetitive cervical loading
- Recent vigorous physical exertion
- Fluoroquinolone antibiotic exposure
- Smoking or other vascular risk factors
- Hyperhomocysteinemia or MTHFR-related metabolic abnormalities (when documented)
- Autoimmune or inflammatory vasculopathies
- Recent chiropractic, medical, or athletic cervical interventions (temporal association only)
- Prior transient ischemic attack or ischemic stroke
- History of arterial aneurysm or other vascular abnormalities
- Multiple concurrent susceptibility factors that may compound overall risk

420

Demetrious CeAD-R³ Clinical DDX Algorithm



Open access Systematic review

SVN Stroke & Vascular Neurology

Risk factors for cervical artery dissection: a systematic review with meta-analysis

Wilco Jacobs ,[1,2] Debbie S Wright,[3] Katherine Pohlman ,[3] Rob Rosenbaum,[4] Barbara A Hutten,[5] Gwendolyne GM Scholten-Peeters,[6] Scott Haldeman,[7] Johannes CF Kat,[8] Sidney M Rubinstein [3,9]

To cite: Jacobs W, Wright DS, Pohlman K, *et al*. Risk factors for cervical artery dissection: a systematic review with meta-analysis. *Stroke & Vascular Neurology* 2025;0. doi:10.1136/svn-2025-004186

► Additional supplemental material is published online only. To view, please visit the journal online (https://doi.org/10.1136/svn-2025-004186).

Received 5 March 2025
Accepted 16 July 2025

Check for updates

© Author(s) (or their employer(s)) 2025. Re-use permitted under CC BY-NC. No commercial re-use. See rights and permissions. Published by BMJ Group.

For numbered affiliations see end of article.

Correspondence to
Dr Wilco Jacobs
wilcodl@hetnet.nl

ABSTRACT

Background Cervical artery dissection (CAD) is a rare cause of stroke. This is an update of an earlier systematic review, which focuses on the risk of CAD in the general population. The objective was to identify the risk factors for CAD.

Methods A comprehensive search was conducted in MEDLINE, EMBASE and Web of Science on 20 September 2024. Observational studies (cohort, case-control studies and case-crossover studies) that studied patients with CAD and a control group were included. Risk of bias was assessed with the ROBINS-E tool, and certainty of the evidence was assessed using Grading of Recommendations Assessment, Development and Evaluation (GRADE). The results were stratified by healthy controls (primary analyses) and other control groups, notably ischaemic non-CAD stroke (secondary analyses).

Findings In total, 128 study reports were identified, of which 54 used one or more healthy control groups. Of these reports, 49 (91%) used a case-control design. The risk of bias was generally high (63%). For the following categories, effects were identified: (1) genetic factors or factors with a familial predisposition: migraine, methylenetetrahydrofolate reductase (MTHFR), TT hemozygosity, matrix metalloproteinases (MMP) concentration, and connective tissue disorders; (2) external factors: recent infection, winter or autumn–winter season and oral contraceptive use; (3) minor trauma; (4) cardiovascular factors: hypertension, hypercholesterolaemia, relative vasodilatation of internal carotid, coronary artery disease and other cardiac diseases. For other risk factors (3), there were no significant pooled estimates. The certainty of the evidence was moderate for migraine and MTHFR TT, low for minor trauma and very low certainty for all others.

Interpretation This is the first review that comprehensively examined the risk of CAD in the general population. Genetic factors, cardiovascular risk factors, recent infection and minor trauma are risk factors for CAD. Caution is needed in interpretation as the evidence is overall low to very low certainty, except for migraine and MTHFR TT hemozygosity.

WHAT IS ALREADY KNOWN ON THIS TOPIC

⇒ Cervical artery dissection (CAD) is a rare vascular pathology which affects about 9 in 100 000 young and otherwise healthy people per year. A recent study suggests that most are asymptomatic, with up to two of 100 cases of CAD resulting in ischaemic intracranial stroke.

⇒ Several potential risk factors of CAD have been suggested based on case series and cross-sectional studies using all source stroke populations as controls. Still, a comprehensive review of risk factors in the general population is lacking as many of these studies based on stroke populations have a high risk of bias.

WHAT THIS STUDY ADDS

⇒ We included cohort, case-crossover studies and case-control studies with healthy control groups or stroke control groups.

⇒ Genetic factors, cardiovascular risk factors, recent infection and minor trauma are risk factors for CAD in the general population. The best evidence with a moderate level of certainty shows that migraine and methylenetetrahydrofolate reductase TT homozygosity are important risk factors for CAD.

HOW THIS STUDY MIGHT AFFECT RESEARCH, PRACTICE OR POLICY

⇒ Knowledge of risk factors may help identify those at risk of CAD and may assist general practitioners in clinical reasoning and determining when to refer patients for hospital care.

INTRODUCTION

Cervical artery dissection (CAD) is a vascular condition involving a false, blood-filled lumen between the vessel wall layers, most commonly occurring in the vertebral and carotid arteries.[1] Spontaneous CAD refers to occurrence without obvious major trauma. Knowledge about the incidence of CAD is limited due to the underdiagnosis of asymptomatic cases. In the healthy adult population, CAD occurs at a rate of 8.95 per 100 000 person-years,[2] while CAD accompanied by stroke occurs at a rate of 2.97 per 100 000 person-years.[3] Between 0 and 13.5% of adult CAD patients experience a stroke within the first 6 weeks,[4–6] but this estimate is dependent on the hospital setting with stroke centres

Protected by copyright, including for uses related to text and data mining, AI training, and similar technologies. For commercial use, see rights and permissions. Published by BMJ Group. Stroke & Vascular Neurology: first published as 10.1136/svn-2025-004186 on 27 August 2025. Downloaded from http://svn.bmj.com/ on August 27, 2025 at Universitaire Bibliotheken Leuven. Protected by copyright, including for uses related to text and data mining, AI training, and similar technologies.

Table 4 Summary of findings table: cardiovascular factors

Risk factor	Pooled estimate (95% CI)	Number of participants (Studies)	Certainty of the evidence (GRADE)*	Comments
Common carotid artery diameter (SMD)	0.13 (-0.25 to 0.51)	154 (3)[19 22 36]	Very low[1 2 4]	
Intima-media thickness (SMD)	−0.18 (-0.54 to 0.18)	116 (2)[22 36]	Very low[1 4]	
Relative Vasodilation of the ICA (SMD)	−1.17 (-2.13 to -0.21)	102 (2)[19 22]	Very low[1 2 4]	Not upgraded due to substantial downgrades
Smoking (OR)	1.08 (0.92 to 1.27)	8641 (21)[17 18 22 25–27 29–31 36 42 46 49 50 52 53 56–58 66 70]	Very low[1 2 4]	
Hypertension (OR)	1.58 (1.43 to 1.75)	22379 (23)[17 18 22 23 25–29 31 36 42 46 47 49 50 52 53 56–58 66 70]	Low[1 7]	
Bleeding (OR)	1.08 (0.26 to 4.48)	293 (2)[43 50]	Very low[1–4]	
Hypercholesterolaemia (OR)	1.29 (1.04 to 1.61)	20603 (18)[17 22 23 25 26 29–31 47 49 50 52 53 56–58 66 70]	Very low[1 2]	
Coronary artery disease (OR)	1.81 (1.47 to 2.22)	9328 (2)[47 50]	Very low[1 3]	
Other cardiac diseases (OR)	1.85 (1.65 to 2.08)	13 124 (2)[23 47]	Very low[1–3]	
BMI (SMD)	−0.14 (-0.41 to 0.13)	1201 (5)[17 22 36 50 56]	Very low[1 3 4]	
Obesity (OR)	0.41 (0.31 to 0.56)	4996 (3)[28 29 58]	Very low[1 3]	Not upgraded due to substantial downgrades
Overweight (OR)	0.81 (0.62 to 1.06)	4796 (2)[28 29]	Very low[1–3]	Not upgraded due to substantial downgrades
DM (OR)	1.09 (0.7 to 1.69)	12421 (20)[17 18 22 23 25 26 29–31 42 46 49 50 52 53 56–58 66 70]	Very low[1 2 4]	Not upgraded due to substantial downgrades

Summary of findings: Risk factors for cervical artery dissection: Cardiovascular factors.

Patient population: Patients with cervical artery dissection with or without stroke Exposed (Control) populations: General healthy population Outcome: Cervical artery dissection

For GRADE decisions see table 1 footnote.
BMI, body mass index; DM, Diabetes Mellitus; ICA, internal carotid artery; OR, odds ratio; SMD, standardised mean difference.

421

Demetrious CeAD-R³ Clinical DDX Algorithm

Predictor Domain 2 - Susceptibility

- **Clinical Pearl**
  - The cumulative burden of susceptibility factors is generally more informative than any single risk factor.
  - Risk stratification should consider the interaction of:
    - heritable predisposition,
    - acquired medical conditions,
    - symptom evolution,
    - and current neurological findings rather than isolated historical variables.

Blum. *Arch Neurosci*. 2015 October ; 2(4): . doi:10.5812/archneurosci.26670.

422

Demetrious CeAD-R³ Clinical DDX Algorithm

- **Predictor Domain 3**
  - **Symptom Onset**
    - Exact time and date of symptom onset
    - Abrupt ("thunderclap") versus progressive development
    - First symptom experienced
    - Initial symptom severity
    - Location and distribution of pain
    - Pain preceding neurological symptoms
    - Neurological symptoms preceding pain
    - Simultaneous onset of pain and neurological symptoms
    - New symptoms unlike previous episodes

423

Demetrious CeAD-R³ Clinical DDX Algorithm

- **Predictor Domain 4**
  - **Temporal Evolution – S/S**
    - Stable
    - Improving
    - Progressive
    - Fluctuating
    - Recurrent
    - Intermittent
    - Rapidly evolving
    - Sequentially accumulating over hours to days
    - Recalcitrant

424

Demetrious CeAD-R³ Clinical DDX Algorithm

- **Predictor Domain 4**
  - **Temporal Evolution – Neurological**
    - Transient
    - Persistent
    - Progressive
    - Fluctuating
    - Recurrent
    - Associated with worsening pain
    - Increasing in frequency or severity

425

Demetrious CeAD-R³ Clinical DDX Algorithm

Predictor Domain 4 - Temporal Evolution

Clinical Pearl

Progressive or sequential development of unilateral pain, cranial nerve abnormalities, transient ischemic symptoms, or neurological deficits over hours to days should substantially increase clinical suspicion for cervical artery dissection, occlusion and thromboembolism, particularly when occurring in the presence of predisposing susceptibility factors.

Trager et al. Cureus 15(12): e51297. DOI 10.7759/cureus.51297

426

Demetrious CeAD-R³ Clinical DDX Algorithm

- **Predictor Domain 5**
  - **Non-Dissection Stroke Causation**
    - Cardioembolic Sources
    - Hypercoagulable States
    - Premature Atherosclerotic Disease
    - Inflammatory and Autoimmune Vasculopathies
    - Genetic and Non-Atherosclerotic Vasculopathies
    - Drug-Related and Toxic Causes
    - Hematologic Disorders
    - Other Stroke Mechanisms

427

Demetrious CeAD-R³ Clinical DDX Algorithm

- **Predictor Domain 5**
  - **Non-Dissection Stroke Causation**
    - **Cardioembolic Sources**
      - Atrial fibrillation or atrial flutter
      - Patent foramen ovale (PFO)
      - Atrial septal aneurysm
      - Cardiomyopathy
      - Valvular heart disease
      - Infective endocarditis
      - Recent myocardial infarction
      - Intracardiac thrombus
      - Cardiac tumors (e.g., atrial myxoma)

428

Demetrious CeAD-R³ Clinical DDX Algorithm

- **Predictor Domain 5**
  - **Non-Dissection Stroke Causation**
    - **Hypercoagulable States**
      - Inherited thrombophilia
      - Antiphospholipid antibody syndrome
      - Factor V Leiden mutation
      - Prothrombin G20210A mutation
      - Protein C deficiency
      - Protein S deficiency
      - Antithrombin III deficiency
      - Active malignancy
      - Pregnancy or postpartum hypercoagulability
      - Estrogen-containing oral contraceptives or hormone therapy

429

Demetrious CeAD-R³ Clinical DDX Algorithm

- **Predictor Domain 5**
  - **Non-Dissection Stroke Causation**
    - **Premature Atherosclerotic Disease**
      - Hypertension
      - Diabetes mellitus
      - Dyslipidemia
      - Cigarette smoking
      - Obesity
      - Metabolic syndrome
      - Chronic kidney disease
      - Strong family history of premature cardiovascular disease

430

Demetrious CeAD-R³ Clinical DDX Algorithm

- **Predictor Domain 5**
  - **Non-Dissection Stroke Causation**
    - **Inflammatory and Autoimmune Vasculopathies**
      - Primary CNS vasculitis
      - Systemic vasculitis
      - Giant cell arteritis (when clinically appropriate)
      - Systemic lupus erythematosus
      - Behçet disease
      - Takayasu arteritis
      - Sarcoidosis
      - Other inflammatory arteriopathies

431

Demetrious CeAD-R³ Clinical DDX Algorithm

- **Predictor Domain 5**
  - **Non-Dissection Stroke Causation**
    - **Genetic and Non-Atherosclerotic Vasculopathies**
      - Moyamoya disease
      - CADASIL - cerebral autosomal dominant arteriopathy with subcortical infarcts and leukoencephalopathy
      - MELAS - mitochondrial encephalomyopathy, lactic acidosis, and stroke-like episodes
      - Sickle cell disease
      - Other inherited cerebrovascular disorders

432

Demetrious CeAD-R³ Clinical DDX Algorithm

- **Predictor Domain 5**
  - **Dissection Stroke Causation**
    - **Drug-Related and Toxic Causes**
      - Fluoroquinolones
      - Cocaine
      - Amphetamines or methamphetamine
      - Sympathomimetic agents
      - Excessive alcohol
      - Performance-enhancing drugs
      - Vasoconstrictive medication



Chiropractic & Manual Therapies

HYPOTHESIS — Open Access

Spontaneous cervical artery dissection: a fluoroquinolone induced connective tissue disorder?

James S. Demetrious

Abstract

Background: Spontaneous cervical artery dissections more often manifest in young people and have been associated with catastrophic consequences. Some indeterminate risk factors have been identified, making the diagnosis of developing dissections quite difficult. Fluoroquinolone antibiotics have been recognized for their degradative effects on connective tissue. Recent studies have implicated fluoroquinolones in the genesis of aortic artery aneurysms. It is the purpose of this paper to provide reasoning for a testable hypothesis of whether fluoroquinolones constitute a risk factor associated with cervical artery dissections.

Methods: A PubMed search was conducted to investigate whether cervical artery dissection has been associated with fluoroquinolone use. An assessment of risk factors was made of hereditary connective tissue disorders, infection, and seasonal predisposition related to cervical artery dissection. These factors were considered in conjunction with reports of connective tissue toxicity associated with fluoroquinolone medications.

Results: It appears that no reported cases of cervical artery dissection have previously been correlated with fluoroquinolone use. Heritable connective tissue disorders, infection, seasonal predisposition and condition latencies are associated with fluoroquinolone medications. Several recent articles have implicated fluoroquinolones with aortic dissections and aneurysm.

Conclusion: A causal relationship of fluoroquinolone antibiotics to cervical artery dissection is plausible. The suppositions developed in this paper are insufficient to suggest that fluoroquinolones currently represent an established risk factor in the development of cervical artery dissections. Fluoroquinolones may indeed be a novel and previously unrecognized cause of cervical artery dissections.

Keywords: Cervical artery dissection, Fluoroquinolone, Carotid, Vertebral, Stroke, Infarct, Connective tissue, Collagen, Aneurysm

Introduction

The primary objective of this paper is to provide a testable hypothesis whether fluoroquinolone antibiotics constitute a risk factor associated with spontaneous cervical artery dissections.

Epidemiology

Spontaneous cervical artery dissections are a common cause of stroke in young adults, with a mean age of occurrence of approximately 45 years and a slight gender predisposition favoring males 48–55% [1, 2]. During a 17-year study period, Lee et al. reported a mean annual incident rate of 2.6 to 3.1 per 100,000 population [3]. A seasonal variation has been reported with cervical artery dissection more likely to occur in the winter [4].

Congenital risk factors

Heritable disorders such as Ehlers-Danlos syndrome, Marfan syndrome, osteogenesis imperfecta type 1, autosomal dominant polycystic kidney disease, and fibromuscular dysplasia have been reported as risk factors for cervical artery dissection [2]. While only 1–5% of patients with these connective tissue disorders have been identified with spontaneous vertebral artery dissection,

Correspondence: dr.demetrious@gmail.com
Wilmington, USA

BMC

433

Demetrious CeAD-R³ Clinical DDX Algorithm

- **Predictor Domain 5**
  - **Non-Dissection Stroke Causation**
    - **Hematologic Disorders**
      - Polycythemia
      - Essential thrombocythemia
      - Severe anemia
      - Leukemia
      - Myeloproliferative disorders
      - Paroxysmal nocturnal hemoglobinuria

434

Demetrious CeAD-R³ Clinical DDX Algorithm

- **Predictor Domain 5**
  - **Non-Dissection Stroke Causation**
    - **Other Stroke Mechanisms**
      - Cerebral venous sinus thrombosis
        - Cerebral venous sinus thrombosis (CVST) is a rare type of stroke that happens when a blood clot forms in the brain's venous sinuses, blocking blood from draining out of the brain. This blockage builds up pressure, which can cause brain swelling or bleeding.
      - Reversible cerebral vasoconstriction syndrome (RCVS)
      - Intracranial aneurysm with thromboembolism
      - Intracranial atherosclerotic disease
      - Septic emboli
      - Fat embolism
      - Air embolism

435

Demetrious CeAD-R³ Clinical DDX Algorithm

Predictor Domain 5 - Non-Dissection Stroke Causation

Clinical Pearl

This domain should be used to broaden the differential diagnosis and identify competing or coexisting causes of cerebral ischemia, ensuring that vascular imaging and additional investigations are appropriately directed.

Zhang et al. Cerebral Infarction: Epidemiology, Classification, Mechanisms, Diagnosis, and Management. 2026 Apr 1;7(4):e70704. doi: 10.1002/mco2.70704

436

Demetrious CeAD-R³ Clinical DDX Algorithm

- **Predictor Domain 6**
  - **Neurologic Findings:**
    - Transient Ischemic Symptoms
    - Cognition
    - Cranial Nerve / Neuro-ophthalmologic Findings
    - Vestibular
    - Brainstem Symptoms
    - Ataxia

437

Demetrious CeAD-R³ Clinical DDX Algorithm

- **Predictor Domain 6**
  - **Neurologic Findings:**
    - **Transient Ischemic Symptoms**
      - Unilateral facial, arm, or leg weakness
      - Unilateral numbness or paresthesia
      - Dysarthria
      - Aphasia or language disturbance
      - Transient monocular vision loss (amaurosis fugax)
      - Diplopia
      - Vertigo accompanied by focal neurological symptoms
      - Limb incoordination or transient ataxia
      - Drop attacks
      - Symptoms resolving completely within minutes to hours
      - Recurrent stereotyped transient neurological episodes

438

Demetrious CeAD-R³ Clinical DDX Algorithm

- **Predictor Domain 6**
  - **Neurologic Findings:**
    - **Cranial Nerve / Neuro-ophthalmologic Findings**
      - Partial Horner syndrome (ptosis, miosis ± anhidrosis)
      - Diplopia Facial sensory loss
      - Facial weakness
      - Dysphagia
      - Dysarthria
      - Dysphonia/hoarseness
      - Tongue deviation or weakness
      - Reduced gag reflex
      - Palatal asymmetry
      - Hearing changes
      - Tinnitus
      - Multiple cranial nerve involvement

439

Demetrious CeAD-R³ Clinical DDX Algorithm

- **Predictor Domain 6**
  - **Neurologic Findings:**
    - **Vestibular / Brainstem Symptoms**
      - Severe vertigo
      - Persistent dizziness
      - Disequilibrium
      - Ataxia
      - Gait instability
      - Limb dysmetria
      - Dysdiadochokinesia
      - Central nystagmus
      - Nausea or vomiting associated with neurological findings
      - Dysphagia
      - Dysarthria
      - Diplopia
      - Crossed neurological findings
      - Altered level of consciousness
      - Respiratory or autonomic dysfunction (late/severe presentation)

440

Demetrious CeAD-R³ Clinical DDX Algorithm

- **Predictor Domain 6**
  - **Neurologic Findings:**
    - **Clinical Integration**
      - Transient or persistent
      - Progressive
      - Fluctuating
      - Sequentially evolving
      - Localizable to the anterior or posterior circulation
      - Consistent with embolic ischemia
      - Consistent with brainstem or cerebellar dysfunction
      - Objective versus subjective
      - Occurring in conjunction with new unilateral head or neck pain

441

Demetrious CeAD-R³ Clinical DDX Algorithm

Predictor Domain 6 – Neurologic Findings

Clinical Pearl

Neurological findings should not be interpreted in isolation. The probability of cervical artery dissection increases when transient ischemic symptoms, cranial neuropathies, neuro-ophthalmologic abnormalities, or vestibular–brainstem findings occur in combination with new unilateral head or neck pain, progressive symptom evolution, and underlying vascular susceptibility. Multiple converging neurological domains generally provide greater diagnostic value than any single neurological deficit alone.

Keser et al. Vascular Health and Risk Management 2022:18

442

Demetrious CeAD-R³ Clinical DDX Algorithm

- **Predictor Domain 7**
  - **Physical Examination**
    - General Assessment
    - Neurological Examination
      - Cranial Nerve Examination
      - Neuro-Ophthalmologic Examination
      - Vestibular Examination
      - Cerebellar Examination
    - Cervical Spine Examination
    - Vascular Examination
    - Connective Tissue Examination – Beighton Scale

443

Demetrious CeAD-R³ Clinical DDX Algorithm

Predictor Domain 7 – Physical Examination

Clinical Pearl

The physical examination should be viewed as an opportunity to identify objective neurological localization, recognize evolving ischemia, and distinguish benign musculoskeletal disorders from potentially life-threatening cerebrovascular pathology. A normal examination does not exclude cervical artery dissection, particularly in the early stages before objective neurological deficits have developed.

Yaghi et al. Stroke. 2024 Mar;55(3):e91-e106. doi: 10.1161/STR.0000000000000457.

444

Demetrious CeAD-R³ Clinical DDX Algorithm

- **Predictor Domain 8**
  - **Prior Interventions**
    - Seen a primary care physician
    - Consulted a neurologist
    - Been evaluated by a chiropractor
    - Seen another manual therapist
    - Visited an urgent care center
    - Been hospitalized for similar symptoms
    - Had multiple healthcare visits for the same complaint

445

Demetrious CeAD-R³ Clinical DDX Algorithm

- **Predictor Domain 8**
  - **Prior DX Tests**
    - Non-contrast CT brain
    - CTA head and neck
    - MRI brain MRA head and neck
    - Duplex carotid ultrasound
    - Echocardiography ECG or cardiac monitoring
    - Routine laboratory testing
    - Hypercoagulability evaluation
    - Lab tests:
      - Homocysteine
      - Heritable polymorphisms

446

Demetrious CeAD-R³ Clinical DDX Algorithm

Predictor Domain 8 – Prior Interventions

Clinical Pearl

Previous evaluations should inform, but not determine, the current diagnostic assessment. Early cervical artery dissection may be missed because symptoms precede objective neurological deficits or because vascular imaging was not performed, was incomplete, or was obtained before imaging abnormalities became apparent. Persistent clinical suspicion should prompt reconsideration of the diagnosis despite prior reassurance or negative investigations.

447

Demetrious CeAD-R³ Clinical DDX Algorithm

Predictor Domain 9 – Compounded Comorbidities

Clinical Pearls

- No single comorbidity is diagnostic of cervical artery dissection. Rather, clinical suspicion should increase as multiple susceptibility factors coexist.
- The interaction of hereditary predisposition, acquired vascular disease, inflammatory conditions, hypercoagulability, recent biological stressors, and mechanical exposures often provides greater diagnostic value than any isolated risk factor.
- A multivariable approach to compounded comorbidities better reflects the heterogeneous pathophysiology of cervical artery dissection and ischemic stroke in younger adults.

Jacobs et al. . *Stroke and Vascular Neurology*. 2025;:svn-2025-004186. https://doi.org/10.1136/svn-2025-004186

448

Demetrious CeAD-R³ Clinical DDX Algorithm

- **Predictor Domain 10**
  - **Alternative Diagnoses**
    - Primary Headache Disorders
    - Mechanical Cervical Disorders
    - Vestibular Disorders
    - Cranial / Neuro-Ophthalmologic Disorders
    - Intracranial Pathology
    - Inflammatory / Infectious Disorders
    - Cardiovascular Disorders
    - Peripheral Neurological Disorders
    - Systemic / Metabolic Disorders
    - Functional Disorders

449

Demetrious CeAD-R³ Clinical DDX Algorithm

- **Predictor Domain 10**
  - **Alternative Diagnoses - Diagnostic Concordance**
    - Determine whether the alternative diagnosis:
      - Explains the complete symptom complex
      - Explains the temporal progression
      - Accounts for objective neurological findings
      - Accounts for cranial nerve abnormalities
      - Explains vascular risk factors
      - Better fits available imaging findings
      - Is more or less probable than cervical artery dissection
      - May coexist with cervical artery dissection

450

Demetrious CeAD-R³ Clinical DDX Algorithm

Predictor Domain 10 – Alternative Diagnoses

Clinical Pearl

Alternative diagnoses should be actively considered throughout the diagnostic process. However, the presence of a plausible musculoskeletal, vestibular, or primary headache disorder should not prematurely exclude cervical artery dissection when the patient demonstrates evolving unilateral head or neck pain, transient ischemic symptoms, cranial neuropathies, neuro-ophthalmologic abnormalities, or posterior circulation findings. Diagnostic accuracy is optimized by comparing competing diagnoses against the entire multivariable clinical presentation rather than relying on a single symptom or presumed diagnosis.

Chaibi et al. Ann Med. 2019 Mar;51(2):118-127. doi: 10.1080/07853890.2019.1590627.

451

Demetrious CeAD-R³ Clinical DDX Algorithm

Referral and Follow Up

Clinical Pearls

- Patients with suspected cervical artery dissection should be managed according to their estimated risk of thromboembolic stroke rather than the certainty of diagnosis.
- Because arterial thrombus formation and distal embolization may precede, accompany, or follow vessel dissection, any patient with evolving **neurological** symptoms, recurrent transient ischemic attacks, progressive unilateral head or neck pain, or objective neurological deficits should be treated as potentially harboring an unstable cerebrovascular lesion until timely vascular imaging and specialist evaluation exclude the diagnosis.

Prabhakaran. Stroke. 2026;57:e316–e436. DOI: 10.1161/STR.0000000000000513
Debette et al. European Stroke Journal 2021, Vol. 6(3) XXXIX–LXXXVIII

452

Demetrious CeAD-R³ Clinical DDX Algorithm

New 2023

American College of Radiology
ACR Appropriateness Criteria®
Cerebrovascular Diseases-Stroke and Stroke-Related Conditions

Variant: 11 Adult. Suspected cervical vascular dissection or injury. Initial imaging.

Procedure	Appropriateness Category	Relative Radiation Level
MRA neck without and with IV contrast	Usually Appropriate	O
MRA neck without IV contrast	Usually Appropriate	O
CT head without IV contrast	Usually Appropriate	☢☢☢
CTA neck with IV contrast	Usually Appropriate	☢☢☢
MRA head without IV contrast	May Be Appropriate	O
MRI head without IV contrast	May Be Appropriate	O
CTA head with IV contrast	May Be Appropriate	☢☢☢
US duplex Doppler carotid artery	Usually Not Appropriate	O
US duplex Doppler transcranial	Usually Not Appropriate	O
Arteriography cervicocerebral	Usually Not Appropriate	☢☢☢
MRA head without and with IV contrast	Usually Not Appropriate	O
MRI head perfusion with IV contrast	Usually Not Appropriate	O
MRI head without and with IV contrast	Usually Not Appropriate	O
MRV head without and with IV contrast	Usually Not Appropriate	O
MRV head without IV contrast	Usually Not Appropriate	O
CT head perfusion with IV contrast	Usually Not Appropriate	☢☢☢
CT head with IV contrast	Usually Not Appropriate	☢☢☢
CT head without and with IV contrast	Usually Not Appropriate	☢☢☢
CTV head with IV contrast	Usually Not Appropriate	☢☢☢

- **Variant 11: Adult. Suspected cervical vascular dissection or injury.**
  - Initial imaging. L. MRA neck without IV contrast MRA of the neck is useful in the initial screening examination for suspected cervical vascular dissection owing to high tissue contrast, especially incorporating fat-saturated T1-weighted sequences, which may be helpful in the delineation of subtle intramural hematomas, improving visibility to the examiner.
  - The sensitivity of MRI neck is similar to CTA neck for cervical carotid dissections.
  - However, the sensitivity for the detection of cervical vertebral artery dissections is significantly reduced compared with CTA neck to as low as 60%, with some variability depending on the technique and sequences employed [129].
  - Limitations of MRA neck include longer acquisition times and lower spatial resolution, which may delay care or miss subtle intimal irregularities associated with suspected cervical vascular dissections, particularly those involving the vertebral artery.
  - Additionally, an unenhanced MRA of the neck may also overestimate the degree of stenosis in more severe dissections, and the anatomic definition of the surrounding structures may be inadequate for treatment planning in some cases depending on the sequences used.
  - Contrast administration can reduce the degree of overestimation of the degree of stenosis in many cases [132].

453

CeAD-R³ Clinical Differential Diagnostic Algorithm



454

POSTGRADDC
EVIDENCE BASED, CLINICALLY INTUITIVE CE

Chiropractic Standard of Care

James Demetrious, DC, DABCO
Diplomate, American Board of Chiropractic Orthopedists

www.PostGradDC.com

455

Class Syllabus

- Duty and Diligence
- What is SoC?
- Application to CAD
- Informed Consent

456

Purpose...Diligence and Duty



"We are what we repeatedly do. Excellence, then, is not an act, but a habit."
— Aristotle, Nicomachean Ethics

457

A Big Problem

A BIG PROBLEM

Increasing judgments against insured.

458

Nuclear Verdicts


Inside Medical Liability
First Quarter 2021
COVER STORY
Nuclear Verdicts Escalate
Verdicts rise as more awards exceed $100M
BY AMY BUTTELL

- Data from the MPL Association Data Sharing Project shows that the **number of awards of more than $1 million has gradually increased over time, reaching 12% of verdicts** between 2016 and 2018.
- Additional data shows that the **50 largest verdicts remained within a band of $15 to $20 million** between 2001 and 2015.[1]
- However, beginning in 2016, the **average verdict severity rose by 50% between 2016 and 2019 to an average of $23 million.[2]**

"An Overview of Medical Malpractice Verdict Awards," 2020 Aon/ASHRM Hospital and Physician Professional Liability Benchmark Analysis, 2020.

459

Nuclear Verdicts...Harmful Viral Responses

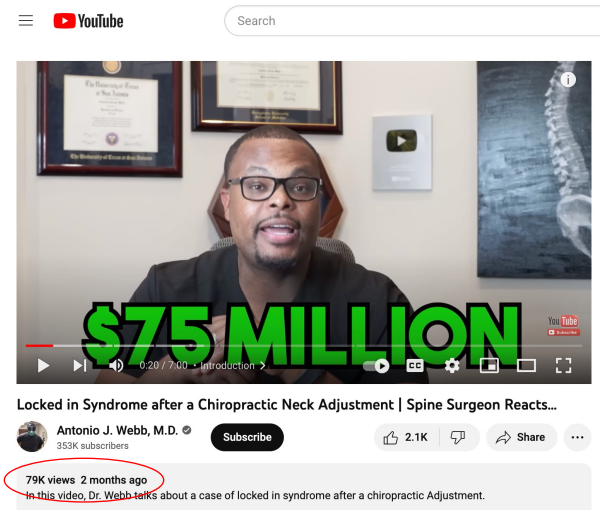

460

Malpractice Litigation

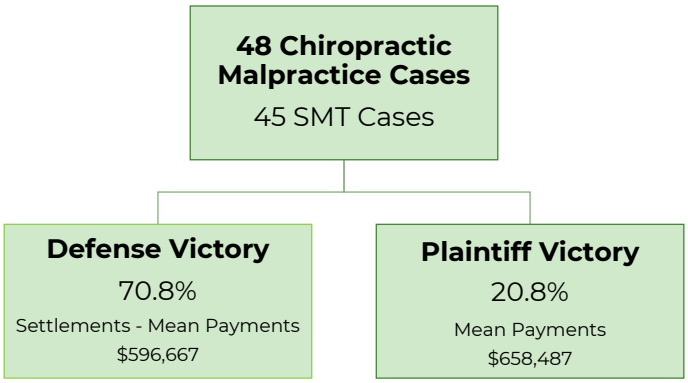

Malpractice Litigation Involving Chiropractic Spinal Manipulation
World Neurosurgery. Volume 149, May 2021, Pages e108-e115

461

Standard of Care Definition

- Care expected of a reasonably prudent chiropractor:
  - as taught in chiropractic schools,
  - from accredited post-graduate education,
  - as mandated in our jurisdictions
  - and as our peers conduct themselves.
- Under similar clinical circumstances
- Based on evidence, expertise, patient factors, and law

462

Standard of Care ≠ Cookbook Medicine

- Not fixed or universal
- Not dictated by isolated studies
- Requires clinical judgment

463

Seven Pillars

- Clinical Assessment
- Evidence-Informed Care
- Risk Recognition
- Informed Consent
- Appropriate Intervention
- Documentation
- Professional Ethics

464

Evidence-Informed Care

- Research + clinical expertise + patient values
- Hierarchy of evidence matters

465

Risk Recognition

- Identify contraindications
- Recognize neurologic deficits
- Modify care appropriately

466

Informed Consent

- Disclose risks, benefits, alternatives
- Based on reasonable patient standard

467

Appropriate Intervention

- Indicated care only
- Monitor outcomes
- Reassess continuously

468

Documentation

- Accurate and contemporaneous
- Reflects reasoning and consent
- Critical for legal defense

469

Clinical Assessment

- History and exam
- Identify red flags
- Use diagnostics when indicated

470

Professional Ethics

- Avoid misleading claims
- Maintain boundaries
- Prioritize patient welfare

471

Legal Framework

- As defined by our jurisdictions and case law
- Must meet evidentiary standards

472

What It Is NOT

- Not perfection
- Not hindsight-based
- Not dictated by low level evidence

473

Dynamic Nature

- Evolves with research and guidelines
- Context-dependent

474

Clinical Application

- What did you know?
- What should you have known?
- What would a reasonable chiropractor do?

475

Take-Home Model

- Think critically
- Act reasonably
- Document thoroughly
- Communicate clearly

476

Purpose…

conspicuity

Also found in: Dictionary, Thesaurus.

Related to conspicuity: conspicuity tape

con·spi·cu·i·ty (kon'spi-kyū'i-tē),

The visibility of a structure of interest on a radiograph, a function of the inherent contrast of the structure and the complexity (noise) of the surrounding image.

Can you see and recognize what others do not?

Qualified? – First to Discover and Publish FQ-CAD Cause



Demetrious *Chiropractic & Manual Therapies* (2018) 26:22
https://doi.org/10.1186/s12998-018-0193-z

Chiropractic & Manual Therapies

HYPOTHESIS Open Access

Spontaneous cervical artery dissection: a fluoroquinolone induced connective tissue disorder?

James S. Demetrious

Abstract

Background: Spontaneous cervical artery dissections more often manifest in young people and have been associated with catastrophic consequences. Some indeterminate risk factors have been identified, making the diagnosis of developing dissections quite difficult. Fluoroquinolone antibiotics have been recognized for their degradative effects on connective tissue. Recent studies have implicated fluoroquinolones in the genesis of aortic artery aneurysms. It is the purpose of this paper to provide reasoning for a testable hypothesis of whether fluoroquinolones constitute a risk factor associated with cervical artery dissections.

Methods: A PubMed search was conducted to investigate whether cervical artery dissection has been associated with fluoroquinolone use. An assessment of risk factors was made of hereditary connective tissue disorders, infection, and seasonal predisposition related to cervical artery dissection. These factors were considered in conjunction with reports of connective tissue toxicity associated with fluoroquinolone medications.

Results: It appears that no reported cases of cervical artery dissection have previously been correlated with fluoroquinolone use. Heritable connective tissue disorders, infection, seasonal predisposition and condition latencies are associated with fluoroquinolone medications. Several recent articles have implicated fluoroquinolones with aortic dissections and aneurysm.

Conclusion: A causal relationship of fluoroquinolone antibiotics to cervical artery dissection is plausible. The suppositions developed in this paper are insufficient to suggest that fluoroquinolones currently represent an established risk factor in the development of cervical artery dissections. Fluoroquinolones may indeed be a novel and previously unrecognized cause of cervical artery dissections.

Keywords: Cervical artery dissection, Fluoroquinolone, Carotid, Vertebral, Stroke, Infarct, Connective tissue, Collagen, Aneurysm

To Access Article:

Conclusion

A causal relationship of fluoroquinolone antibiotics to cervical artery dissection is plausible. Fluoroquinolones may indeed be a novel and previously unrecognized cause of cervical artery dissections. This hypothesis is insufficient to conclude that fluoroquinolones represent a current and established risk factor for the development of cervical artery dissections. An initial call for case reports and formal investigation is warranted. An extensive longitudinally observed population study might shed light upon this subject.



Use of fluoroquinolones and the risk of spontaneous cervical artery dissection

E. Del Zotto* and A. Pezzini*



Internal Medicine

[CASE REPORT]

Vertebral Artery Dissection after Exposure to Levofloxacin: A Report of Two Cases

Taku Harada[1*], Yukinori Harada[1] and Taro Shimizu[1]

Qualified?...Diagnosed a VAD Missed by Attending MDs



Cureus

Open Access Case Report

Recognition of Vertebral Artery Dissection in a High-Risk Postpartum Patient by a Chiropractic Physician

James Demetrious, Robert J. Trager, Stephen Voigt, Peter Tuchin, David Graber

Abstract

We report a case of vertebral artery dissection (VAD) in a patient with postpartum preeclampsia and underscore the contribution of chiropractic assessment in recognizing vascular pathology, facilitating neurovascular imaging, and expediting emergency intervention. A 36-year-old woman with a history of mixed connective tissue disease presented to the emergency department five days postpartum with facial and peripheral edema, recent onset of hypertension, acute severe neck pain, headache, lightheadedness, confusion, and gait instability. Magnetic resonance angiography (MRA) and magnetic resonance venography revealed a dissection of the left vertebral artery and bilateral cerebellar infarcts consistent with posterior stroke. The patient was admitted and treated for postpartum preeclampsia. Upon discharge, she followed up with a neurocerebrovascular specialist. Although the patient improved with preeclampsia management, concerning neurologic symptoms persisted. The patient later consulted a chiropractor, who suspected VAD. Emergent neck MRA was recommended and performed, confirming VAD 12 days after the initial emergency department visit. The patient was initiated on antithrombotic therapy, with subsequent resolution of symptoms and no evidence of ischemic stroke. This case underscores the importance of maintaining a high index of suspicion for VAD in postpartum patients presenting with new-onset neurological symptoms, particularly in the context of hypertensive disorders of pregnancy and underlying connective tissue disease. It further illustrates the potential role of chiropractic evaluations in the early clinical recognition of vascular pathology, which may facilitate timely diagnosis and intervention, and reduce the risk of stroke.

Introduction

Vertebral artery dissection (VAD) is a type of cervical artery dissection (CAD) involving a tear in the wall of the vertebral artery, resulting in hematoma formation. It may cause ischemic stroke, particularly in young adults, and has an incidence rate of approximately two per 100,000 person-years [1]. The clinical presentation of VAD can be highly variable, ranging from neck pain and headache to symptoms such as visual disturbances, dizziness, and gait abnormalities [2] that can be indicative of brain ischemia. Risk factors for VAD are increasingly understood, such as hypertension, migraine, and connective tissue disorders [3-5].

There is often a delay in the diagnosis of CeAD, with one study reporting a mean time to diagnosis for VAD of 9.4 days (standard deviation of 13.5 days) [6]. CeAD may also be misdiagnosed in the emergency department, with rates of misdiagnosis estimated from 1.2% to 5.4% [7]. Potential reasons for misdiagnoses or delays of VAD include the potentially nonspecific and variable clinical presentations, a low index of suspicion in young patients, cognitive error (e.g., anchoring; premature closure), and diagnostic overshadowing by more common conditions (e.g., migraine, musculoskeletal neck pain, or tension headache) [4,6,7].

Pregnancy is an increasingly recognized risk factor for CeAD and VAD. One study reported that pregnant women had approximately two times the risk of VAD compared to non-pregnant controls, with an elevated incidence of VAD during a one-year window including pregnancy and postpartum of 5.9 (95% confidence intervals [CI]: 3.7-8.1) per 100,000 person-years [8]. Similarly, a case-control study identified a two-fold increase in CeAD risk associated with pregnancy [9]. In that study, the risk of CeAD was greatest during the postpartum period, with an incidence rate ratio of 3.1 (95% CI: 2.6-11.7) [9]. Despite this increased risk, CeAD and VAD may be particularly underrecognized in postpartum women, given the nonspecific symptoms such as headache and neck pain [10].

Patients often present to chiropractic physicians for evaluation of head and neck pain. Accordingly, these clinicians may be positioned to identify red flags suggestive of vascular pathology [11]. In this case report,

How to cite this article

Demetrious J, Trager R J, Voigt S, et al. (August 18, 2025) Recognition of Vertebral Artery Dissection in a High-Risk Postpartum Patient by a Chiropractic Physician. Cureus 17(8): e85388. DOI 10.7759/cureus.85388

To Access Article:

POSTGRADDC
EVIDENCE BASED, CLINICALLY INTUITIVE CE

479

Qualified?...Entered in Successful Defense...



JOURNAL OF CONTEMPORARY CHIROPRACTIC

Commentary on Informed Consent
Wilder, Demetrious, Conway et al.

INFORMED CONSENT IN CHIROPRACTIC: COMMENTARY ON BROWN & LEHMAN'S "INFORMED CONSENT REGARDING RISK OF STROKE FROM CERVICAL SPINE MANIPULATION"

Jeffrey Wilder, DC, DABCO[1], James Demetrious, DC, DABCO[2], Phillip Conway,BPE, DC, FCCPOR(C)[1], David Graber, DC, DACBSP[1], Peter Tuchin, DC, PhD[1]

ABSTRACT

Background: A recent article by Brown and Lehman (2025) advocates for the universal inclusion of cervical artery dissection (CAD) and stroke risk in informed consent for cervical spine manipulation (CSM). Their narrative review appears to rely on anecdotal and low-level evidence, raising concerns regarding its validity and potential impact on clinical and legal standards.

Objective: To critically evaluate the scientific, ethical, and legal foundations of Brown and Lehman's 2025 recommendations and to propose alternative recommendations based on current evidence-based standards and informed consent jurisprudence.

Methods: A detailed appraisal of the papers cited in Brown and Lehman's review was conducted. High-level evidence, including epidemiologic studies, systematic reviews, and biomechanical analyses, was contrasted against the narrative sources used by the authors. Legal and ethical standards surrounding informed consent across U.S. jurisdictions were also reviewed.

Results: Brown and Lehman's article may exhibit confirmation bias, selective citation, and a reliance on case reports, commentaries, and narrative reviews that do not support the concept of universal informed consent related to CSM, CAD, and stroke. Major epidemiological and biomechanical studies appear to contradict their claims. Their review did not include contrary evidence, may have misinterpreted key studies, and contained logical inconsistencies. Legal analysis reveals that informed consent standards vary by jurisdiction, with no legal mandate for blanket disclosure of statistically unproven risks such as CAD post-CSM.

Conclusion: The conclusions presented in the Brown-Lehman review article appear to be based primarily on low-level evidence, including narrative reports, commentaries, and case series, which may not meet the threshold necessary to guide clinical standards or establish legal norms. Their recommendation for universal disclosure of CAD risk in informed consent, despite the absence of causative evidence, raises important considerations regarding clinical relevance and medicolegal implications. Informed consent practices should be aligned with the best available evidence, applicable jurisdictional statutes, and professional standards. Chiropractors are encouraged to consult current clinical guidelines, review applicable laws and rules, and seek legal counsel when determining appropriate disclosures within the informed consent process. (*J Contemporary Chiropr 2025;8:259-265*)

Key Indexing Terms: Cervical spine manipulation, cervical artery dissection, informed consent, chiropractic, medico-legal standards, narrative review, causation, stroke risk

INTRODUCTION

Informed consent is a cornerstone of ethical and legal healthcare practice, empowering patients with the necessary information to make informed decisions

[1] Private Practice of Chiropractic, [2] PostGradDC

J Contemp Chiropr 2025, Volume 8

259

To Access Article:

POSTGRADDC
EVIDENCE BASED, CLINICALLY INTUITIVE CE

- **We identified and reported:**
  - Confirmation bias
  - Flawed reasoning
  - Reliance on low-level evidence
  - Selective citation and omission of contradictory evidence
  - Misreporting prior studies
  - Internal contradictions and logical incoherence
  - Conflict with current standards of care
  - Conflict with existing state regulations

480

The Plaintiff's Weaponization of the Plausible…

Some plaintiff "experts" are weaponizing and monetizing "the plausible" by invoking scientifically unsound claims rooted in:

Bias
Selective Citation
Flawed Reasoning
Low Level Case Reports
Inappropriate Standard of Care
Misapplications of Informed Consent

that contradict highly powered research and that which is taught in Chiropractic colleges.

481

The Plaintiff's Weaponization of the Plausible…



These strategies, too often amounts to very convincing bad air and substantial financial threat.

482

Challenging the "Expert"

- **Bias and Conflict of Interest**
  - **Reason:** Many plaintiff witnesses may have financial, ideological, or litigation-driven incentives to testify against chiropractors.
- **Reliance on Low-Level or Outdated Evidence**
  - **Reason:** Plaintiff experts often base opinions on case reports, anecdotal findings, or outdated studies that do not meet current evidentiary standards.
- **Lack of Advanced Training, Clinical Experience, or Current Practice**
  - **Reason:** Some plaintiff witnesses may be semi-retired academics or consultants with little recent hands-on patient care, board-certified specialization, or lab experience.
- **Speculative Causation and Failure to Apply Differential Diagnosis**
  - **Reason:** Plaintiff experts may assume a causal relationship between chiropractic adjustment and injury without ruling out other plausible causes (e.g., spontaneous cervical artery dissection).
- **Deviation from Standard of Care Definitions**
  - **Reason:** Plaintiff witnesses may misrepresent or misapply the chiropractic standard of care.

483

A Successful Response Strategy?

- Foundation of expertise
- Highlight, methodological weakness
- Expose confirmation bias
- Question biomechanical claims
- Probe conflicts of interest
- Testimony, consistency, and credibility

484

Evidence Hierarchy

Level	Type of Evidence	Description	
I	Systematic Reviews & Meta-Analyses of RCTs	Syntheses of multiple randomized controlled trials (RCTs); highest reliability when well-conducted.	Must be Cited
II	Randomized Controlled Trials (RCTs)	Experimental studies with random allocation; minimize bias and provide strong causal evidence.	
III	Cohort Studies	Observational, follow groups over time to assess outcomes; useful for prognosis and risk factors.	
IV	Case-Control Studies	Observational, compare patients with a condition to those without; good for rare diseases but prone to bias.	
V	Cross-Sectional Studies	Observational, analyze data at a single point in time; useful for prevalence but not causality.	
VI	Case Reports & Case Series	Descriptive accounts of individual or grouped patients; provide early insights but weak generalizability.	Must be Challenged
VII	Expert Opinion / Consensus	Based on clinical expertise without explicit research evidence, most prone to bias.	

485

Challenges, Medical Error, and Indices of Suspicion



- Unpredictable, spontaneous thromboembolic events
- Unknown, undiagnosed contributors
- Unknown compounded factors
- Asymptomatic presentations
- Transient ischemic findings
- Poor reporting by patients
- Poor communication
- Restrictive guidelines

- Commonality of symptoms
- Nonspecific and variable clinical presentation
- A low index of suspicion in young patients
- Cognitive error (e.g., anchoring, premature closure
- Diagnostic overshadowing by more common conditions (e.g., migraine, musculoskeletal neck pain, or tension headache)

486

What is a Reasonable Standard of Care?



What Do YOU See?

50-year-old asymptomatic female. Stable over time. Normal pupillary reactivity. No other neurologic S/S.

487

What is a Reasonable Standard of Care?

Category	Possible Causes	Key Clinical Features	Pupil Reactivity	Other Signs
Physiological	- Physiologic anisocoria (benign)	- Stable over time- <1 mm difference- No symptoms	Normal	None
Neurological (Efferent)	- Horner's syndrome- Third nerve palsy (CN III)- Adie's tonic pupil	- Ptosis, anhidrosis (Horner's)- Ophthalmoplegia, ptosis (CN III)- Slow light reaction, accommodation preserved (Adie's)	Horner: miosisCN III: mydriasisAdie: mydriasis	Horner: facial sweating changes CN III: diplopia, eye down/out
Pharmacologic	- Anticholinergics (e.g., scopolamine, atropine)- Sympathomimetics (e.g., cocaine, eye drops)	- Drug exposure history- No response to light or pilocarpine	Fixed (depending on drug)	Eye redness (if topical); systemic symptoms if ingested
Traumatic	- Iris sphincter tear- Angle closure glaucoma (acute)	- History of trauma- Acute painful red eye (glaucoma)	Poor light response (trauma)Fixed mid-dilated (glaucoma)	Corneal edema, high IOP, severe headache (glaucoma)
Inflammatory/Infectious	- Iritis / Uveitis	- Pain, photophobia- Small, irregular pupil	Sluggish or irregular	Ciliary flush, keratic precipitates
Neoplastic	- Mass compressing sympathetic or parasympathetic pathways (e.g., Pancoast tumor, aneurysm)	- Progressive symptoms- Possible pain	Depends on nerve affected	Horner's features, CN palsies, systemic malignancy signs
Congenital	- Congenital Horner's syndrome- Anisocoria present from birth	- Often with heterochromia (Horner's)- Asymptomatic	Horner: miosis	Lighter iris on affected side (Horner's)
Migraine-associated	- Benign episodic anisocoria associated with migraines	- Transient anisocoria during/after migraine attack	Normal after resolution	Headache, aura symptoms

Advanced Continuing Education is VITAL!

488

What is a Reasonable Standard of Care?



Revised 2022

American College of Radiology
ACR Appropriateness Criteria®
Headache

Variant 1: **Sudden onset severe headache that reaches maximal severity within one hour. Initial imaging.**

Procedure	Appropriateness Category	Relative Radiation Level
CT head without IV contrast	Usually Appropriate	☢☢☢
CTA head with IV contrast	May Be Appropriate	☢☢☢
Arteriography cervicocerebral	Usually Not Appropriate	☢☢☢
MRA head with IV contrast	Usually Not Appropriate	O
MRA head without and with IV contrast	Usually Not Appropriate	O
MRA head without IV contrast	Usually Not Appropriate	O
MRI head with IV contrast	Usually Not Appropriate	O
MRI head without and with IV contrast	Usually Not Appropriate	O
MRI head without IV contrast	Usually Not Appropriate	O
MRV head with IV contrast	Usually Not Appropriate	O
MRV head without and with IV contrast	Usually Not Appropriate	O
MRV head without IV contrast	Usually Not Appropriate	O
CT head with IV contrast	Usually Not Appropriate	☢☢☢
CT head without and with IV contrast	Usually Not Appropriate	☢☢☢
CTV head with IV contrast	Usually Not Appropriate	☢☢☢

TRIAL TESTIMONY
WRIGHT V. REDFIELD
65

that this was a patient that did not have ischemic symptoms, and the standard of care would have been for Dr. -- to eliminate his liability, according to your blog, is to send him to the ER but some ER docs won't order the test that they would need to diagnose it. Right?

A. Right.

Q. Okay. So are you telling me that the ER doc physicians across the country are deviating from the standard of care if you're sending a patient like that?

A. I can't comment on the standard of care for ER docs sufficiently because I'm not an ER doc, but yes, they should do those CTAs.

R

Variant 4: **Headache with features of intracranial hypertension (eg, papilledema, pulsatile tinnitus, visual symptoms worse on Valsalva). Initial imaging.**

Procedure	Appropriateness Category	Relative Radiation Level
MRI head without and with IV contrast	Usually Appropriate	O
MRI head without IV contrast	Usually Appropriate	O
CT head without IV contrast	Usually Appropriate	☢☢☢
MRV head with IV contrast	May Be Appropriate	O
MRV head without and with IV contrast	May Be Appropriate	O
MRV head without IV contrast	May Be Appropriate	O
CTV head with IV contrast	May Be Appropriate	☢☢☢
Arteriography cervicocerebral	Usually Not Appropriate	☢☢☢
MRA head with IV contrast	Usually Not Appropriate	O
MRA head without and with IV contrast	Usually Not Appropriate	O
MRA head without IV contrast	Usually Not Appropriate	O
MRI head with IV contrast	Usually Not Appropriate	O
CT head with IV contrast	Usually Not Appropriate	☢☢☢
CT head without and with IV contrast	Usually Not Appropriate	☢☢☢
CTA head with IV contrast	Usually Not Appropriate	☢☢☢

489

What is a Reasonable Standard of Care?

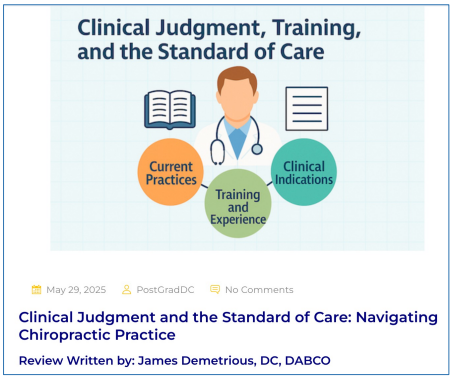

https://postgraddc.com/standard-care-chiropractic-postgraddc-demetrious/

PostGradDC Summary Assessment for CAD/Stroke

Clinical History & Predisposition Screening

- Recent neck or head trauma (e.g., MVC, falls, sports)
- Connective tissue disorders, loose joint syndrome
- Fibromuscular dysplasia
- Fluoroquinolone, oral contraceptive, and blood thinner use
- Arteriopathy
- Family, past personal history of stroke, coagulopathies, PFO, Afib, etc.

Red Flag Symptoms

- Sudden, severe, unilateral, anterior or posterior neck pain or headache
- Visual disturbances (diplopia, vision loss), CN abnormalities
- Horner's syndrome (ptosis, miosis, anhidrosis)
- Dysarthria, dysphagia, vertigo, ataxia
- Focal neurologic deficits (weakness, numbness)

Physical/Complete Neurological Exam

- Vitals
- Cranial and peripheral nerve examination
- Cerebellar function, gait, and balance
- Extremity motor, reflex, and sensory testing
- Auscultation of carotid/vertebral bruits
- Beighton scale

Emergent Medical Referral

- Refer and communicate with emergency services
- Convey diagnosis and emergent need for CTA, MRA of neck, MRI brain
- Document
- Follow-up

490

Purpose...Diligence and Duty





491

Purpose...

"Informed consent is not just the signing of a form. Informed consent is about a thorough process of communication between patient and provider."

Aaron Fink, MD
Emory University School of Medicine

492

Informed Consent

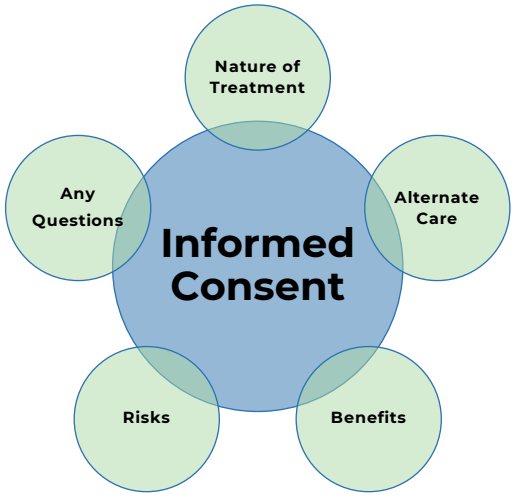

493

Definition - Informed Consent

The Joint Commission

"Stated simply, informed consent in medical care is a process of communication between a clinician and a patient that results in the patient's authorization or agreement to undergo a specific medical intervention (see sidebar box for The Joint Commission's glossary definition)."

Informed consent: *Agreement or permission accompanied by full notice about the care, treatment, or service that is the subject of the consent. A patient must be apprised of the nature, risks, and alternatives of a medical procedure or treatment before the physician or other health care professional begins any such course. After receiving this information, the patient then either consents to or refuses such a procedure or treatment.*

Source: The Joint Commission. 2016. Comprehensive Accreditation Manual glossary.

494

CMAJ REVIEW

Informed consent for clinical treatment

Daniel E. Hall MD MDiv, Allan V. Prochazka MD MSc, Aaron S. Fink MD

KEY POINTS

- Informed consent means different things in different contexts, is variably practised and rarely achieves the theoretical ideal.
- Simple consent entails that a patient (or surrogate) with decision-making capacity freely authorizes a treatment plan aimed at a mutually acknowledged treatment goal.
- The authorization is "informed" when the physician discloses and the patient understands the diagnosis, the relevant options for treatment (including no treatment) and any respective risks and benefits.
- The informed consent process should be documented thoroughly, using an electronic medical record, procedure-specific consent forms, patient education materials and other options whenever possible.

CMAJ, March 20, 2012, 184(5) 533

495

CMAJ REVIEW

Informed consent for clinical treatment

Daniel E. Hall MD MDiv, Allan V. Prochazka MD MSc, Aaron S. Fink MD

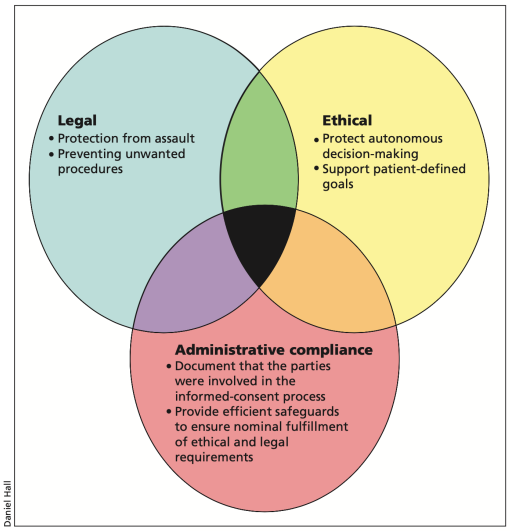

Figure 1: Venn diagram showing the multiple overlapping purposes of informed consent.

496

What is the Standard of Care?

Table 2. Historical development of the Standard of Care

Initial Definition
Based on custom
That which is typically done is what is considered standard
The 20th Century Definition (*Helling v. Carey; The TJ Hooper*)
That which is customarily done plus anything that seems reasonable even if not typically done
The Modern Definition (*Hall v. Hilburn; McCourt v. Abernathy; Johnston v. St. Francis Medical Center*)
That which a minimally competent physician in the same field would do under similar circumstances

The Standard of Care: Legal History and Definitions: the Bad and Good News
West J Emerg Med. 2011 Feb; 12(1): 109–112.

497

What is the Standard of Care?

Chief Justice C.J. Robertson stated:

- "Medical malpractice is a legal fault by a physician or surgeon. It arises from the failure of a physician to provide the quality of care required by law. When a physician undertakes to treat a patient, he takes on an obligation enforceable at law to use minimally sound medical judgment and render minimally competent care in the course of services he provides. A physician does not guarantee recovery... A competent physician is not liable per se for a mere error of judgment, mistaken diagnosis or the occurrence of an undesirable result." 11

11. Hall v. Hilburn, 466 So. 2d 856 (Miss. 1985).

The Standard of Care: Legal History and Definitions: the Bad and Good News
West J Emerg Med. 2011 Feb; 12(1): 109–112.

498

What is the Standard of Care?

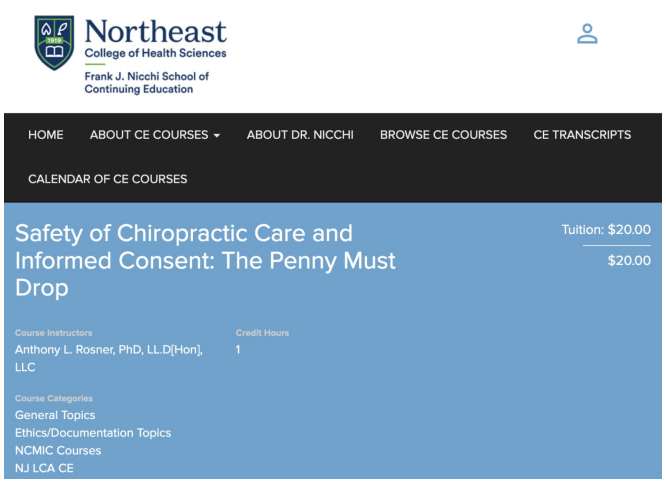

499

What is the Standard of Care?


Northwestern Health Sciences University

CHIROPRACTIC INFORMED CONSENT

I hereby give my consent to the performance of diagnostic tests and procedures and chiropractic treatment or management of my condition(s).

I understand that the treatment I receive at this clinic may be performed by advanced chiropractic interns under the supervision of a licensed Doctor of Chiropractic. I also understand that this is a teaching clinic and that student observers may be present during treatment.

Chiropractic treatment or management of conditions almost always includes the chiropractic adjustment, a specific type of joint manipulation. Like most health care procedures, the chiropractic adjustment carries with it some risks. Unlike many such procedures, the serious risks associated with the chiropractic adjustment are extremely rare. **Following are the known risks: Temporary soreness or increased symptoms or pain.** It is not uncommon for patients to experience temporary soreness or increased symptoms or pain after the first few treatments.

Dizziness, syncope, flushing: These symptoms are relatively rare. It is important to notify the chiropractor if you experience these symptoms during or after your care.

Fractures When patients have underlying conditions that weaken bones, like osteoporosis, they may be susceptible to fracture. It is important to notify your chiropractor if you have been diagnosed with a bone weakening disease or condition. If your chiropractor detects any such condition while you are under care, you will be informed and your treatment plan will be modified to minimize risk of fracture.

Disc herniation or prolapse: Spinal disc conditions like bulges or herniations may worsen even with chiropractic care. It is important to notify your chiropractor if symptoms change or worsen.

Stroke. A certain extremely rare type of stroke has been associated with chiropractic care. Although there is an association between this type of stroke and chiropractic visits, there is also an association between this type of stroke and primary care medical visits. According to the most recent research, there is no evidence of excess risk of stroke associated with chiropractic care. The increased occurrence of this type of stroke associated with both chiropractic and medical visits is likely explained by patients with neck pain and headache consulting both doctors of chiropractic and primary care medical doctors before or during their stroke.

Other risks associated with chiropractic treatment include rare burns from physiotherapy devices that produce heat.

Bruising: Instrument assisted soft tissue manipulation may result in temporary soreness or bruising.

I understand that the practice of chiropractic, like the practice of all healing arts, is not an exact science, and I acknowledge that no guarantee can be given as to the results or outcome of my care.

• PATIENT PLEASE REVIEW • PRINT & SIGN NAME •

I have read or had read to me this informed consent document. I have discussed or been given the opportunity to discuss any questions or concerns with my chiropractor and have had these answered to my satisfaction prior to my signing this informed consent document. I have made my decision voluntarily and freely.

PATIENT'S NAME (Print)_____ DATE OF BIRTH_____

(PATIENT | GUARDIAN SIGNATURE) (DATE) (TRANSLATOR | INTERPRETER SIGNATURE) (DATE)

CLINICIAN ONLY

Based on my personal observation and the patient's history, I conclude that throughout the informed consent process the patient was:

☐ OF LEGAL AGE ☐ APPEARED UNDERAGED ☐ ACCOMPANIED THROUGH GUARDIAN ☐ INTERNS PRESENT - INITIAL_____

☐ ORIENTED X3 ☐ FLUENT IN ENGLISH ☐ ASSISTED BY A TRANSLATOR OR INTERPRETER ☐ INTERNS NOT PRESENT

_____, D.C. _____

(D.C. SIGNATURE) (DATE)

Northwestern Health Sciences University • 2501 W. 84th St. • Bloomington, MN 55431 • 952-886-7388

500

What is the Standard of Care?

Guidelines for the Practice of Chiropractic in North Carolina

III. Informed Consent (added July 2008)

A. A chiropractic physician is legally and ethically obligated to obtain informed consent from his patient prior to the start of treatment. Consent cannot be considered informed unless, at a minimum, the physician orally explains the risks associated with the proposed course of treatment, answers any questions the patient may have, and obtains the patient's permission to treat.

B. The physician shall note in the patient's clinical record the date of the informed consent consultation, the matters discussed, and the authorization to treat given by the patient. A standardized form may be used only as a written acknowledgment by the patient that the consultation occurred and that consent was given. A form cannot replace the face-to-face discussion between physician and patient contemplated by this guideline.

C. If the patient is a minor or an incompetent adult, the informed consent consultation shall include the patient's parent or legal guardian.

501

BOARD of CHIROPRACTIC EXAMINERS STATE OF CALIFORNIA

BUSINESS, CONSUMER SERVICES AND HOUSING AGENCY • GAVIN NEWSOM, GOVERNOR
DEPARTMENT OF CONSUMER AFFAIRS • CALIFORNIA BOARD OF CHIROPRACTIC EXAMINERS
1625 N. Market Blvd., Suite N-327, Sacramento, CA 95834
P (916) 263-5355 | Toll-Free (866) 543-1311 | F (916) 327-0039 | www.chiro.ca.gov

SEPTEMBER 2022 ENFORCEMENT ACTIONS

ACCUSATIONS FILED

Name and City	License No.	Date Filed	Alleged Violation(s)
[redacted] Park City, UT		9/23/2022	• CCR 317(k) – Unprofessional Conduct: Acts Involving Dishonesty • CCR 317(q) – Unprofessional Conduct: Fraud or Misrepresentation • CCR 317(l) – Unprofessional Conduct: Making or Signing Documents with False Statements • CCR 317(b) – Unprofessional Conduct: Repeated Acts of Negligence • CCR 317(d) – Unprofessional Conduct: Excessive Treatment or Diagnostic Procedures • CCR 317(e) – Unprofessional Conduct: Conduct That Endangers or is Likely to Endanger the Public • CCR 318(b) – Accountable Billings • CCR 319.1 – Lack of Informed Consent • CCR 318 – Failure to Maintain Complete Chiropractic Patient Records

DISCIPLINARY ACTIONS

Name and City	License No.	Action	Effective Date	Violation(s)
[redacted] Bend, OR		Public Reproval	9/8/2022	• CCR 317(m), 318(a)(7), and 319.1 – Failure to Maintain Signed Written Informed Consent

502

Preventable Error?

- **Case Deficits:**
  - DC failure to perform a thorough history and examination.
  - DC failure to request prior medical records.
  - Failure to obtain informed consent.
  - No documentation of informed consent discussion.

503

Informed Consent

The Joint Commission

Elements of Informed Consent

- The Joint Commission requires documentation of all the elements of informed consent "in a form, progress notes or elsewhere in the record."[2] The following are the elements needed for documentation of the informed consent discussion:
  - the nature of the procedure;
  - the risks and benefits of the procedure;
  - reasonable alternatives;
  - risks and benefits of alternatives; and
  - assessment of the patient's understanding of elements 1 through 4.

504

Informed Consent

- **Means to Ensure IC:**
  - Compliance Policy
  - Discussion
  - Visible Clarity:
    - Intake
    - Countertop
    - Website
    - Documents for Home
  - Documentation

505

The Informed Consent Discussion

What is Teach-back?

- A way to make sure you—the health care provider—explained information clearly. It is not a test or quiz of patients.
- Asking a patient (or family member) to explain **in their own words** what they need to know or do, in a caring way.
- A way to check for understanding and, if needed, re-explain and check again.
- A research-based health literacy intervention that improves patient-provider communication and patient health outcomes[1].

[1] Schillinger, 2003

506

The Informed Consent Discussion

Always Use Teach-back!

10 Elements of Competence for Using Teach-back Effectively

1. Use a caring tone of voice and attitude.
2. Display comfortable body language and make eye contact.
3. Use plain language.
4. Ask the patient to explain back, using their own words.
5. Use non-shaming, open-ended questions.
6. Avoid asking questions that can be answered with a simple yes or no.
7. Emphasize that the responsibility to explain clearly is on you, the provider.
8. If the patient is not able to teach back correctly, explain again and re-check.
9. Use reader-friendly print materials to support learning.
10. Document use of and patient response to teach-back.

507

The Informed Consent Discussion



This is a suggested sample for use in developing an informed consent form and is for reference purposes only. This document does not establish a standard of care. It is intended for use as a tool to reduce malpractice risk and should be edited to fit your practice and to meet the legal requirements of your individual state(s). It also intended to improve communication with patients so they may better understand the treatment recommended. **NCMIC does not tell chiropractors what to document, but instead advises all chiropractors to use their clinical judgment in determining the need for informed consent and the content of such a form.**

Informed Consent Document

PATIENT NAME: _____

To the Patient: Please read this entire document prior to signing it. It is important that you understand the information contained in this document. Please ask questions before you sign if there is anything that is unclear.

The nature of the chiropractic adjustment.
The primary treatment used by doctors of chiropractic is spinal manipulative therapy. I will use that procedure to treat you. I may use my hands or a mechanical instrument upon your body in such a way as to move your joints. That may cause an audible "pop" or "click," much as you have experienced when you "crack" your knuckles. You may feel a sense of movement.

Analysis / Examination / Treatment
As a part of the analysis, examination, and treatment, you are consenting to the following procedures:
___ spinal manipulative therapy ___palpation ___ vital signs
___ range of motion testing ___orthopedic testing ___ basic neurological testing
___ muscle strength testing ___ postural analysis testing
___ ultrasound ___hot/cold therapy ___ EMS
___ radiographic studies
___ Other (please explain)

_____
_____
Patient should initial each procedure they are consenting to.

The risks inherent in chiropractic adjustment.
As with any healthcare procedure, there are certain complications which may arise during chiropractic manipulation and therapy. These complications include but are not limited to: fractures, disc injuries, dislocations, muscle strain, cervical myelopathy, costovertebral strains and separations, and burns. Some types of manipulation of the neck have been associated with injuries to the arteries in the neck leading to or contributing to serious complications including stroke. Some patients will feel some stiffness and soreness following the first few days of treatment. The Doctor will make every reasonable effort during the examination to screen for contraindications to care; however if you have a condition that would otherwise not come to the Doctor's attention it is your responsibility to inform the Doctor.

The probability of those risks occurring.
Fractures are rare occurrences and generally result from some underlying weakness of the bone which we check for during the taking of your history and during examination and X-ray. Stroke and /or arterial dissection caused by chiropractic manipulation of the neck has been the subject of ongoing medical research and debate. The most current research on the topic is inconclusive as to a specific incident of this complication occurring. If there is a causal relationship at all it is extremely rare and remote. Unfortunately, there is no recognized screening procedure to identify patients with neck pain who are at risk of arterial stroke.



This is a suggested sample for use in developing an informed consent form and is for reference purposes only. This document does not establish a standard of care. It is intended for use as a tool to reduce malpractice risk and should be edited to fit your practice and to meet the legal requirements of your individual state(s). It also intended to improve communication with patients so they may better understand the treatment recommended. **NCMIC does not tell chiropractors what to document, but instead advises all chiropractors to use their clinical judgment in determining the need for informed consent and the content of such a form.**

The availability and nature of other treatment options.
Other treatment options for your condition may include:
- Self-administered, over-the-counter analgesics and rest
- Medical care and prescription drugs such as anti-inflammatory, muscle relaxants and pain-killers
- Hospitalization
- Surgery

If you chose to use one of the above noted "other treatment" options you should be aware that there are risks and benefits of such options and you may wish to discuss these with your primary medical physician.

The risks and dangers attendant to remaining untreated.
Remaining untreated may allow the formation of adhesions and reduce mobility which may set up a pain reaction further reducing mobility. Over time this process may complicate treatment making it more difficult and less effective the longer it is postponed.

CONSENT TO TREATMENT (MINOR)

I hereby request and authorize (*insert your name*) to perform diagnostic tests and render chiropractic adjustments and other treatment to my minor son/daughter: _____. This authorization also extends to all other doctors and office staff members and is intended to include radiographic examination at the doctor's discretion.

As of this date, I have the legal right to select and authorize health care services for the minor child named above. (If applicable) Under the terms and conditions of my divorce, separation or other legal authorization, the consent of a spouse/former spouse or other parent is not required. If my authority to so select and authorize this care should be revoked or modified in any way, I will immediately notify this office.

DO NOT SIGN UNTIL YOU HAVE READ AND UNDERSTAND THE ABOVE. PLEASE CHECK THE APPROPRIATE BLOCK AND SIGN BELOW

I have read [ ] or have had read to me [ ] the above explanation of the chiropractic adjustment and related treatment. I have discussed it with *(insert your name)* and have had my questions answered to my satisfaction. By signing below I state that I have weighed the risks involved in undergoing treatment and have decided that it is in my best interest to undergo the treatment recommended. Having been informed of the risks, I hereby give my consent to that treatment.

Dated: _____ **Dated:** _____

_____ _____

Patient's Name **Doctor's Name**

_____ _____

Signature **Signature**

_____

Signature of Parent or Guardian (if a minor)

508

The Informed Consent Discussion



James Demetrious, DC, DABCO
Diplomate, American Board of Chiropractic Orthopedists
4837 Carolina Beach Road, Suite 205 • Wilmington, NC 28412 • Telephone: 910-790-8020

Informed Consent Document

Patient's Name: _____

It is our goal to help you to the best of our ability. Please read this entire document before signing it. It is important that you understand the information contained in this document. Please ask questions before you sign if there is anything unclear.

What to Expect

With your permission, Dr. Demetrious will carefully assess your health. He will talk with you about your health history, examine you, and consider and order necessary tests based on standards of practice and his clinical experience. He will develop a differential diagnosis and make care recommendations. With your consent, he will provide you care to the best of his ability.

Chiropractic Care

The primary treatment offered by Dr. Demetrious is chiropractic adjustments. He may use his hands or a mechanical instrument upon your body in such a way as to move your joints. That may cause a "pop" or "crack" sensation. You may feel a sense of movement. If you feel discomfort with any adjustment, please inform Dr. Demetrious.

The most common side effect of chiropractic care is soreness and stiffness following the first few days of treatment. Sometimes patients experience headaches. This is usually short-term discomfort that is followed by relief.

Risks Inherent to Chiropractic Care

Disc herniations, pinched nerves, arthritic change, and spinal biomechanical issues are very common in many people. Many patients without symptoms have these problems and then aggravate their conditions through their activities of daily living causing them to seek chiropractic care.

Rarely complications from chiropractic care include but are not limited to fractures, disc injuries, dislocations, muscle strain, spinal cord injury, rib, and joint pain. Arterial dissections and strokes are rare and can lead to death and paralysis. The most current research reveals that chiropractic care does not cause arterial dissections or strokes and further research is necessary. It has been reported that patients with arterial dissections experience neck pain, headache, and neurologic symptoms that cause them to see chiropractic care. We do our best to ensure that you do not have a developing dissection or stroke.

Please inform us of any risk factors or health issues before and during your care:

___ Connective tissue disorder, loose joints, Ehlers-Danlos, or Marfan syndrome?
___ Recent head or neck trauma?
___ Worst headache of your life?
___ Elevated homocysteine?
___ Recent infection?
___ Fluoroquinolone medication in the past (Cipro, Levaquin, Levofloxacin, Noroxin, Avelox, etc.)?
___ Trouble seeing or blurred vision?
___ Dizziness?
___ Difficulty talking, difficulty swallowing?
___ Nausea?
___ Numbness or loss of sensation?
___ Change in bladder or bowel function?
___ Weakness of face, arm, or leg?
___ Difficulty walking?
___ Atrial fibrillation or atrial septal defect?
___ Coagulation disorders or medicine?
___ Past history of rib or chest injury or pain?
___ Osteopenia or osteoporosis?
___ Have you been diagnosed with cancer?

Please inform us of all medical procedures and medications you have taken in the past year:

_____
_____
_____
_____

I will instruct my medical providers to send this office my medical records and inform Dr. Demetrious of my health history.

Medical Referral

Dr. Demetrious strongly suggests that you advise your primary medical practitioners that you are seeking chiropractic care for your complaint. He may refer you to your medical doctor or other practitioners who may offer alternative care. Please advise Dr. Demetrious of any hospitalizations, changes in treatment, medication, or surgeries.

Underlying medical issues may not be initially apparent or may seem to be a musculoskeletal problem that does not. Heart problems, kidneys, infections, fractures, cancer, etc., can cause spinal pain. Sometimes, these problems are very difficult to diagnose early on. Symptoms may be very slight and may not be severe enough to warrant testing or referral.

I will honestly and regularly inform the doctor of new symptoms, and worsening symptoms, and let him know if you are not progressively improving. If you have an underlying condition and discontinue care without consulting Dr. Demetrious, he may not be able to provide you with proper medical referrals.

Discontinuing Care

If you decide to discontinue care in our office, please advise Dr. Demetrious. You may have a more severe condition that is not responding and may require further medical care and he will make medical referrals specific to help you.

Reporting New Problems

If you experience any new injury, illness, medical care, medication, surgeries, or any other changes in your medical history, please inform Dr. Demetrious.

Home Care

Dr. Demetrious may make recommendations for activities of daily living, and home exercises. If any recommendation produces discomfort during or after activities, please stop immediately and discuss your concerns with Dr. Demetrious.

Consent to Treat Minor

I hereby request and authorize Dr. James Demetrious to perform diagnostic tests and render chiropractic adjustments and other treatments to my minor son/daughter.

Consent

I have read the above explanation of chiropractic chiropractic care and related treatment. I have discussed it with Dr. Demetrious and have had my questions answered to my satisfaction. By signing below, I state that I have weighed the risks involved in undergoing treatment and have decided that it is in my best interest to undergo the treatment recommended. Having been informed of the risks, I hereby give my consent to examinations and treatment.

Date: _____

_____
Patient's Signature

_____
Doctor's Signature

_____
Signature of Parent or Guardian

This Document is a work in progress. Improvements are necessary.

Not to be used without consultation with your Legal Counsel
Not to be used without consultation with your Legal Counsel

509

The Informed Consent Discussion

James Demetrious, DC, DABCO
Diplomate, American Board of Chiropractic Orthopedists
4837 Carolina Beach Road, Suite 205 • Wilmington, NC 28412 • Telephone: 910-790-8020

Informed Consent Document

Patient's Name: _____

It is our goal to help you to the best of our ability. Please read this entire document before signing it. It is important that you understand the information contained in this document. Please ask questions before you sign if there is anything unclear.

Not to be used without consultation with your Legal Counsel

510

The Informed Consent Discussion

What to Expect

With your permission, Dr. Demetrious will carefully assess your health. He will talk with you about your health history, examine you, and consider and order necessary tests based on standards of practice and his clinical experience. He will develop a differential diagnosis and make care recommendations. With your consent, he will provide you care to the best of his ability.

511

The Informed Consent Discussion

Chiropractic Care

The primary treatment offered by Dr. Demetrious is chiropractic adjustments. He may use his hands or a mechanical instrument upon your body in such a way as to move your joints. That may cause a "pop" or "crack" sensation. You may feel a sense of movement. If you feel discomfort with any adjustment, please inform Dr. Demetrious.

The most common side effect of chiropractic care is soreness and stiffness following the first few days of treatment. Sometimes patients experience headaches. This is usually short-term discomfort that is followed by relief.

512

The Informed Consent Discussion

Risks Inherent to Chiropractic Care

Disc herniations, pinched nerves, arthritic change, and spinal biomechanical issues are very common in many people. Many patients without symptoms have these problems and then aggravate their conditions through their activities of daily living causing them to seek chiropractic care.

513

The Informed Consent Discussion

Rarely complications from chiropractic care include but are not limited to fractures, disc injuries, dislocations, muscle strain, spinal cord injury, rib, and joint pain. Arterial dissections and strokes are rare and can lead to death and paralysis. The most current research reveals that chiropractic care does not cause arterial dissections or strokes and further research is necessary. It has been reported that patients with arterial dissections experience neck pain, headache, and neurologic symptoms that cause them to see chiropractic care. We do our best to ensure that you do not have a developing dissection or stroke.

514

The Informed Consent Discussion

- Please inform us of any risk factors or health issues before and during your care:

____ Connective tissue disorder, loose joints, Ehlers-Danlos, or Marfan syndrome?
____ Recent head or neck trauma?
____ Worst headache of your life?
____ Elevated homocysteine?
____ Recent infection?
____ Fluoroquinolone medication in the past (Cipro, Levaquin, Levofloxacin, Noroxin, Avelox, etc.)?
____ Trouble seeing or blurred vision?
____ Dizziness?
____ Difficulty talking, difficulty swallowing?
____ Nausea?
____ Numbness or loss of sensation?
____ Change in bladder or bowel function?
____ Weakness of face, arm, or leg?
____ Difficulty walking?
____ Atrial fibrillation or atrial septal defect?
____ Coagulation disorders or medicine?
____ Past history of rib or chest injury or pain?
____ Osteopenia or osteoporosis?
____ Have you been diagnosed with cancer?

515

The Informed Consent Discussion

Please inform us of all medical procedures and medications you have taken in the past year:

_____

_____

_____

_____

516

The Informed Consent Discussion

I will instruct my medical providers to send this office my medical records and inform Dr. Demetrious of my health history.

517

The Informed Consent Discussion

Medical Referral

Dr. Demetrious strongly suggests that you advise your primary medical practitioners that you are seeking chiropractic care for your complaint. He may refer you to your medical doctor or other practitioners who may offer alternative care. Please advise Dr. Demetrious of any hospitalizations, changes in treatment, medication, or surgeries.

Underlying medical issues may not be initially apparent or may seem to be a musculoskeletal problem that does not. Heart problems, kidneys, infections, fractures, cancer, etc., can cause spinal pain. Sometimes, these problems are very difficult to diagnose early on. Symptoms may be very slight and may not be severe enough to warrant testing or referral.

I will honestly and regularly inform the doctor of new symptoms, and worsening symptoms, and let him know if you are not progressively improving. If you have an underlying condition and discontinue care without consulting Dr. Demetrious, he may not be able to provide you with proper medical referrals.

518

The Informed Consent Discussion

Discontinuing Care

If you decide to discontinue care in our office, please advise Dr. Demetrious. You may have a more severe condition that is not responding and may require further medical care and he will make medical referrals specific to help you.

519

The Informed Consent Discussion

Reporting New Problems

If you experience any new injury, illness, medical care, medication, surgeries, or any other changes in your medical history, please inform Dr. Demetrious.

520

The Informed Consent Discussion

Home Care

Dr. Demetrious may make recommendations for activities of daily living, and home exercises. If any recommendation produces discomfort during or after activities, please stop immediately and discuss your concerns with Dr. Demetrious.

521

The Informed Consent Discussion

Consent to Treat Minor

I hereby request and authorize Dr. James Demetrious to perform diagnostic tests and render chiropractic adjustments and other treatments to my minor son/daughter.

522

The Informed Consent Discussion

Consent

I have read the above explanation of chiropractic chiropractic care and related treatment. I have discussed it with Dr. Demetrious and have had my questions answered to my satisfaction. By signing below, I state that I have weighed the risks involved in undergoing treatment and have decided that it is in my best interest to undergo the treatment recommended. Having been informed of the risks, I hereby give my consent to examinations and treatment.

Date: _____

_____
Patient's Signature

_____
Doctor's Signature

_____
Signature of Parent or Guardian

ation
th your
Counsel

523

The Informed Consent Countertop Aid



524

The Informed Consent Countertop Aid



Please Inform the Doctor ASAP...

YES NO Have you experienced recent severe head or neck, pain, blurred vision, difficulty speaking or swallowing, confusion, ringing in your ears, dizziness, difficulty holding objects or walking?

YES NO Do you or a family member have a connective tissue disorder or loose joint syndrome?

YES NO Do you have a history of taking fluoroquinolone antibiotics (Cipro, Avelox, Levaquin, Floxin, Factive, Noroxin)?

YES NO Do you or a family member have a history of stroke or aneurysms?

YES NO Do you or your family members have artery problems or heart conditions or bleeding disorders? Do you take blood thinners?

YES NO Have you been sick recently? Have you tested positive for Covid?

YES NO Have you been diagnosed with cancer, diabetes, or arthritis?

YES NO Do you have bone-weakening conditions or do you take medication like prednisone? Have you ever fractured a rib or have weak ribs?

YES NO Have you suffered recent trauma?

YES NO Have you experienced weakness, bladder or bowel problems?

Demetrious Chiropractic Orthopedics

525

A Standard of Care

Why is Informed Consent So Important?

POSTGRADDC
EVIDENCE BASED, CLINICALLY INTUITIVE CE

- College mandated
- Regulatory mandates
- Peers
- Malpractice concerns
- Civil concerns

526

Thank you!

POSTGRADDC
EVIDENCE BASED, CLINICALLY INTUITIVE CE

PostGradDC.com

527