The Cranial Component of Neonatal and Infant Subluxation Patterns

Palmer 2026

Lora Tanis, DC, DICCP



Next 2 Hours

- Describe newborn cranial anatomy
- Neurological development
- Recognize normal birth-related molding
- Perform a structured cranial, cervical and neurological screening examination
- Assess cranial nerve and primitive-reflex findings relevant to newborn function
- Distinguish common positional presentations from findings requiring medical referral
- Explain safe, developmentally appropriate principles for low-force chiropractic care of newborns and infants.
- Clinical hands- on practice for Occiput adjusting and cranial therapy occiput

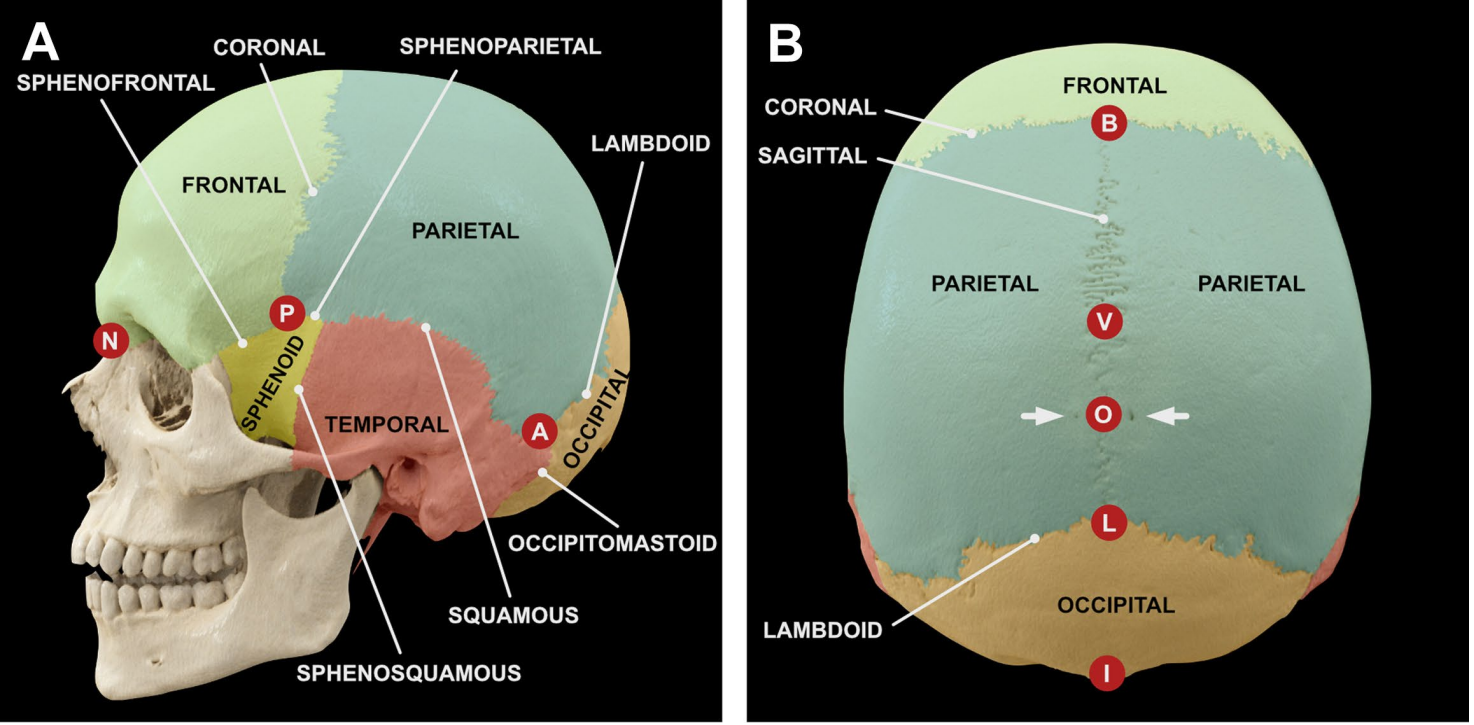

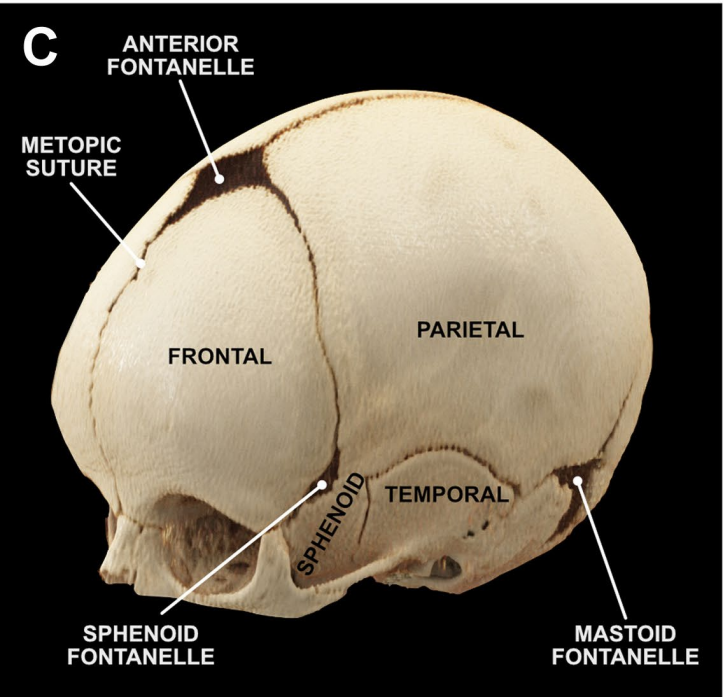

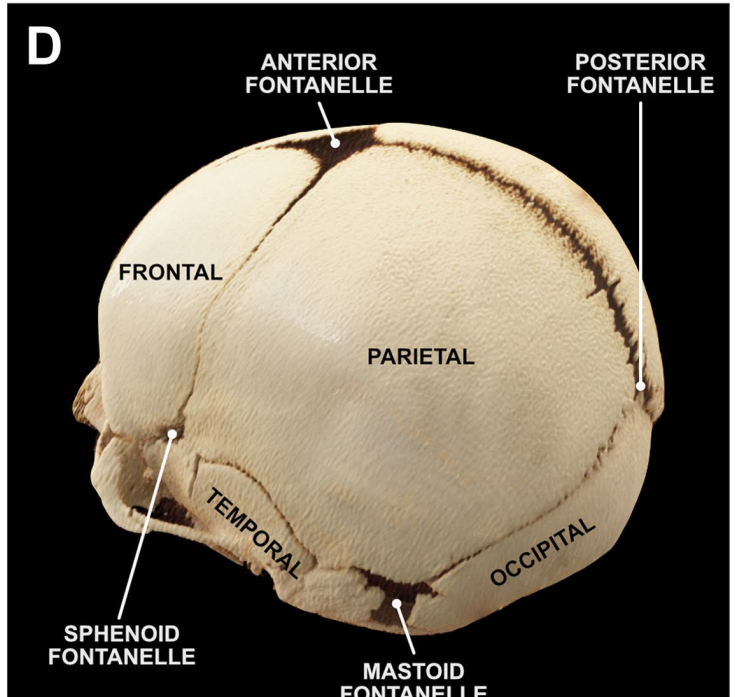

Cranial Anatomy

Sutures

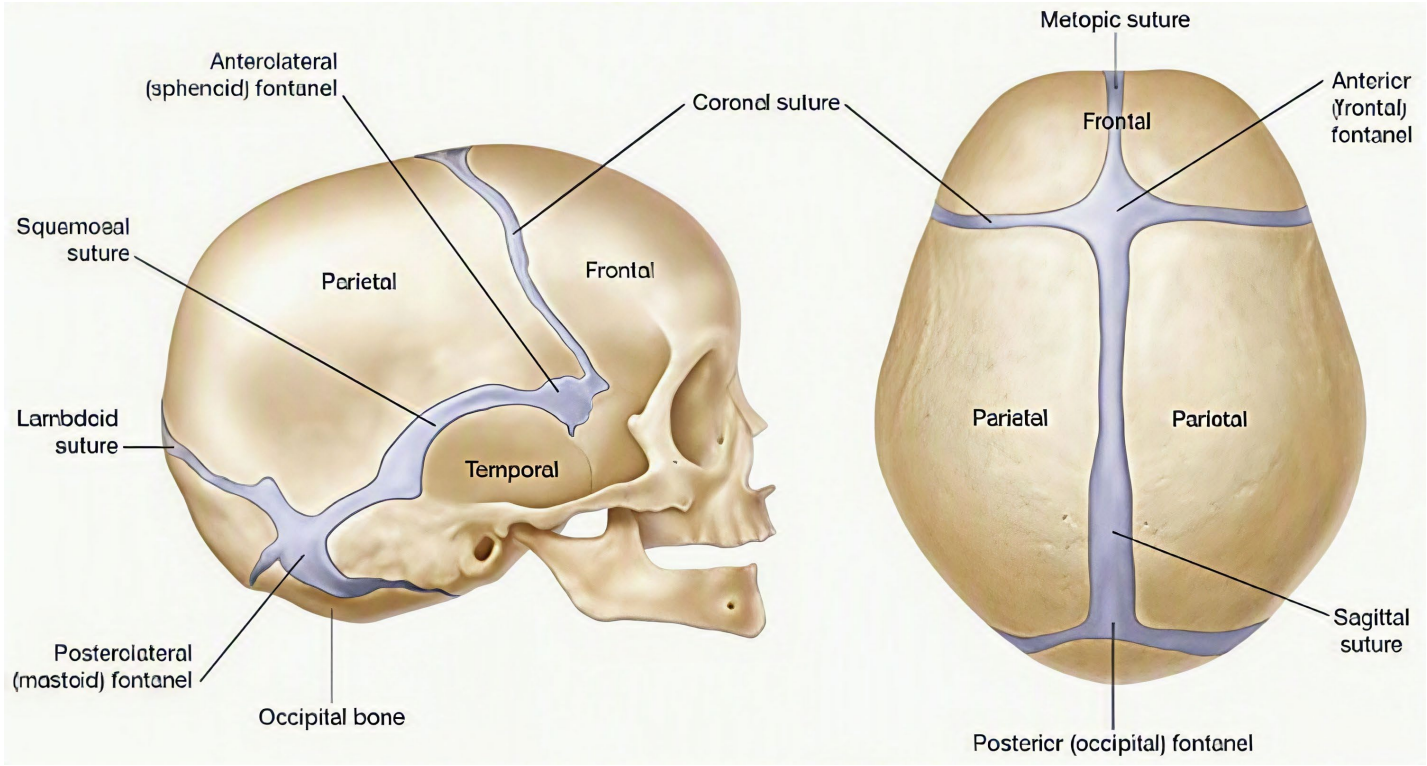
Anterolateral
(sphencid) fontanel
Coronal suture
Squamosal
suture
Parietal
Frontal
Lambdoid
suture
Temporal
Posterolateral
(mastoid) fontanel
Occipital bone
Metopic suture
Anterior
(frontal)
fontanel
Frontal
Parietal
Parietal
Sagittal
suture
Posterior (occipital) fontanel

Infant Cranial Bones and Sutures

The infant skull is made up of multiple bones separated by flexible sutures and fontanelles, allowing for brain growth and development.

Superior View
(Top of head)

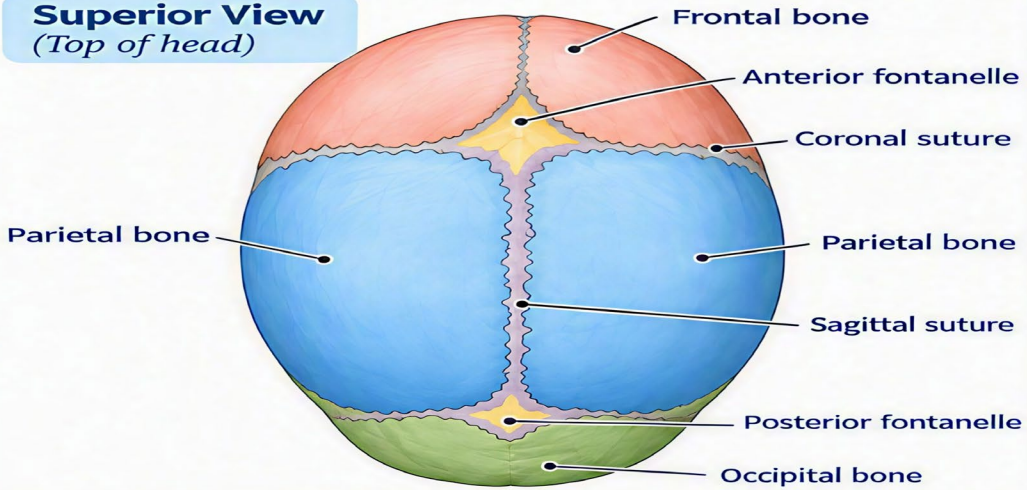

Lateral View
(Side of head)

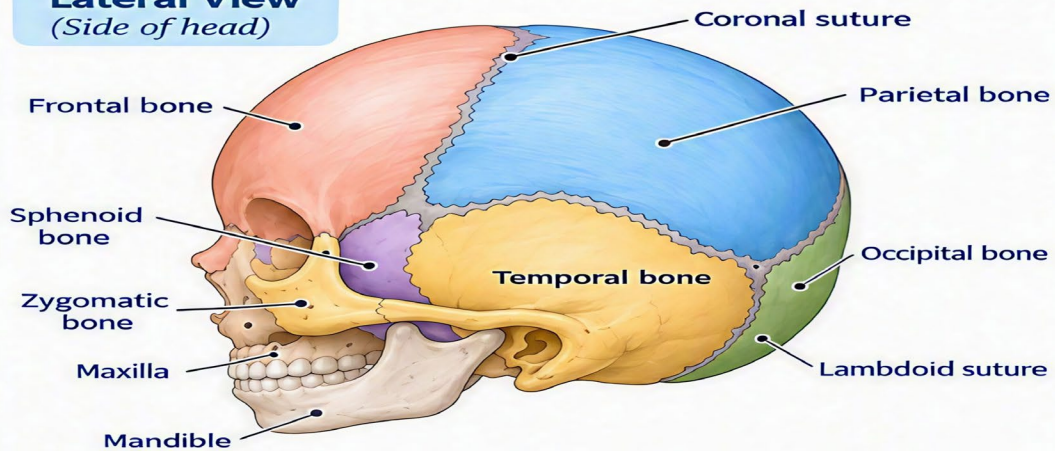

Anterior View
(Front of head)

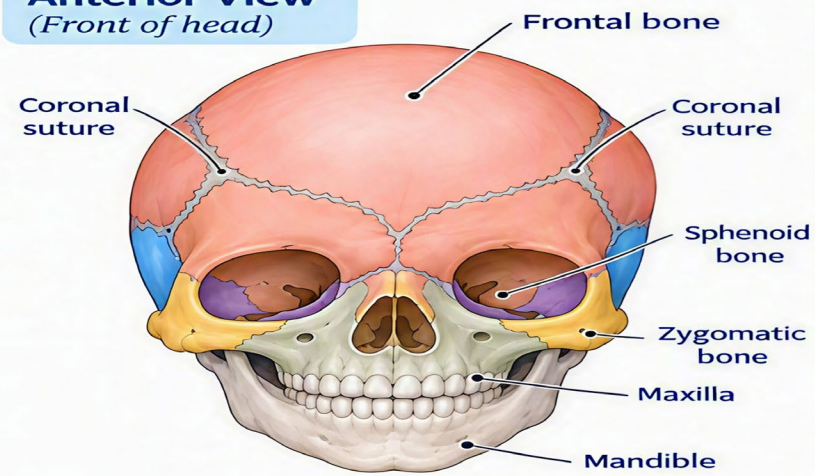

Inferior View
(Bottom of skull)

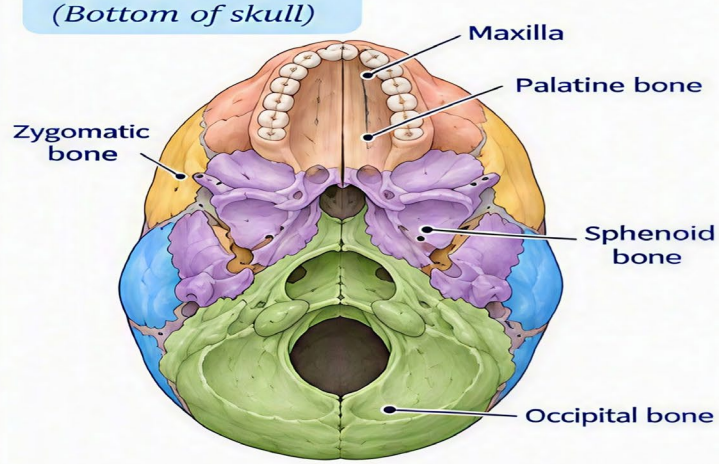

Cranial Bones (Infant)

- Frontal (1)
- Parietal (2)
- Temporal (2)
- Occipital (1)
- Sphenoid (1)
- Zygomatic (2)
- Maxilla (2)
- Mandible (1)

Sutures

- Suture (fibrous connection)
- Fontanelle (soft spot)

Neurological development

- Neonatal neurological development represents a period of rapid maturation and organization of the central and peripheral nervous systems. At birth, many essential functions are primarily supported by the brainstem and subcortical structures, while cortical pathways continue to mature throughout infancy and childhood.
- **Myelination**: Myelination begins prenatally and progresses rapidly after birth
- **Brainstem function**: The brainstem supports vital neonatal functions including respiration, cardiovascular regulation(heart rate, blood pressure) arousal, swallowing, sucking, gagging,airway protection eye movements and many cranial nerve functions.
- **Primitive reflexes:** Reflexes such as the **Moro, rooting, sucking, palmar grasp, plantar grasp and asymmetric tonic neck reflex (ATNR)** reflect early nervous-system organization.
- **Cranial nerve development:** Cranial nerves are functional at birth but continue to mature.
- **Sensory development:** Touch, vestibular input, proprioception, hearing and taste are relatively well developed at birth.
- **Motor development:** Neonatal movement initially consists largely of spontaneous generalized movements and reflex-mediated responses. With increasing **cortical maturation, myelination, synaptic development and sensory experience**, movement progressively becomes more purposeful and coordinated.

Clinical Key Point

- Neurological assessment of the newborn should therefore consider behavioral state, posture and tone, spontaneous movement, symmetry, primitive reflexes, cranial nerve function and developmental progression rather than relying on any single neurological finding.
- **The newborn nervous system is functional but immature; early behavior is strongly influenced by brainstem and subcortical systems, while progressive cortical maturation transforms reflex-dominated activity into increasingly voluntary sensorimotor control.”**



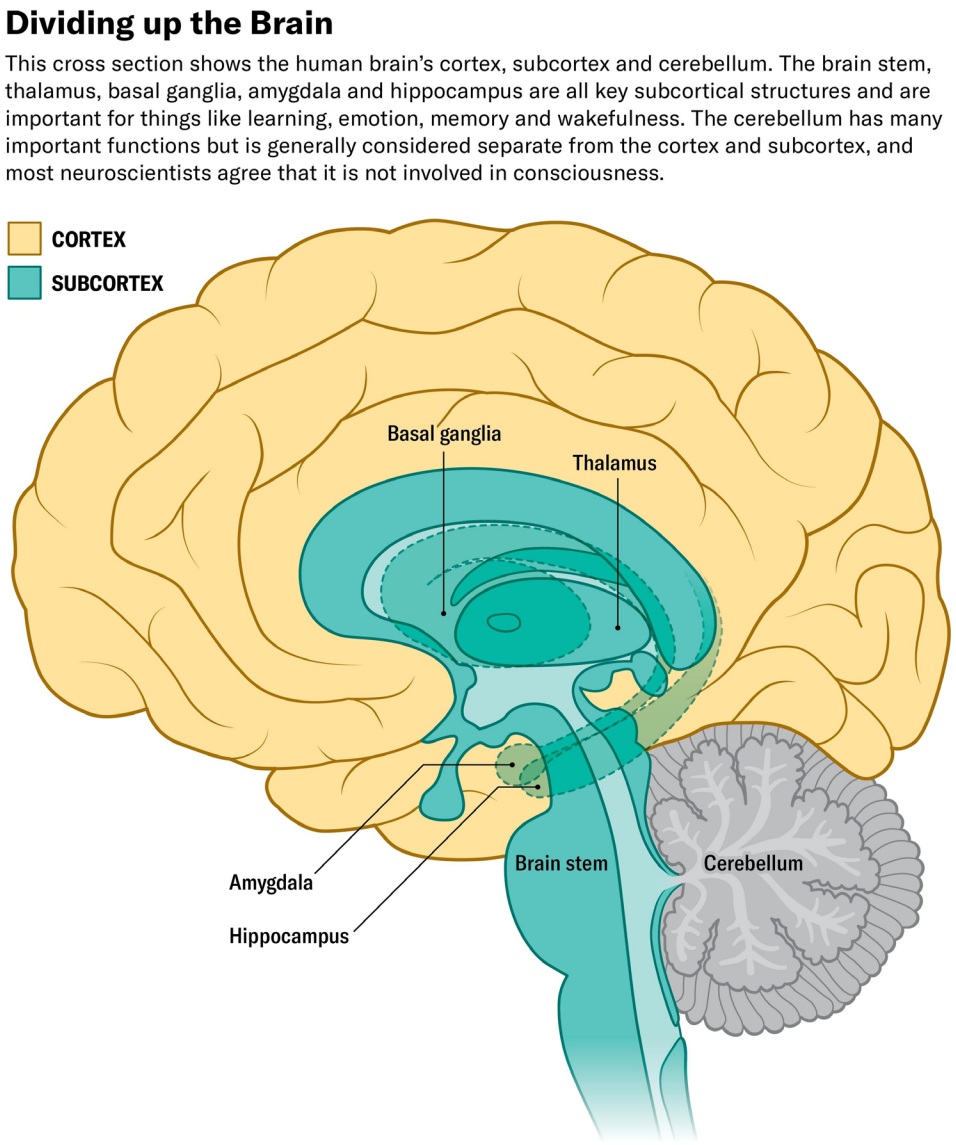

Subcortical System

- brainstem, thalamus, hypothalamus, basal ganglia, limbic structures, cerebellum, and their extensive connections with the spinal cord and developing cerebral cortex.



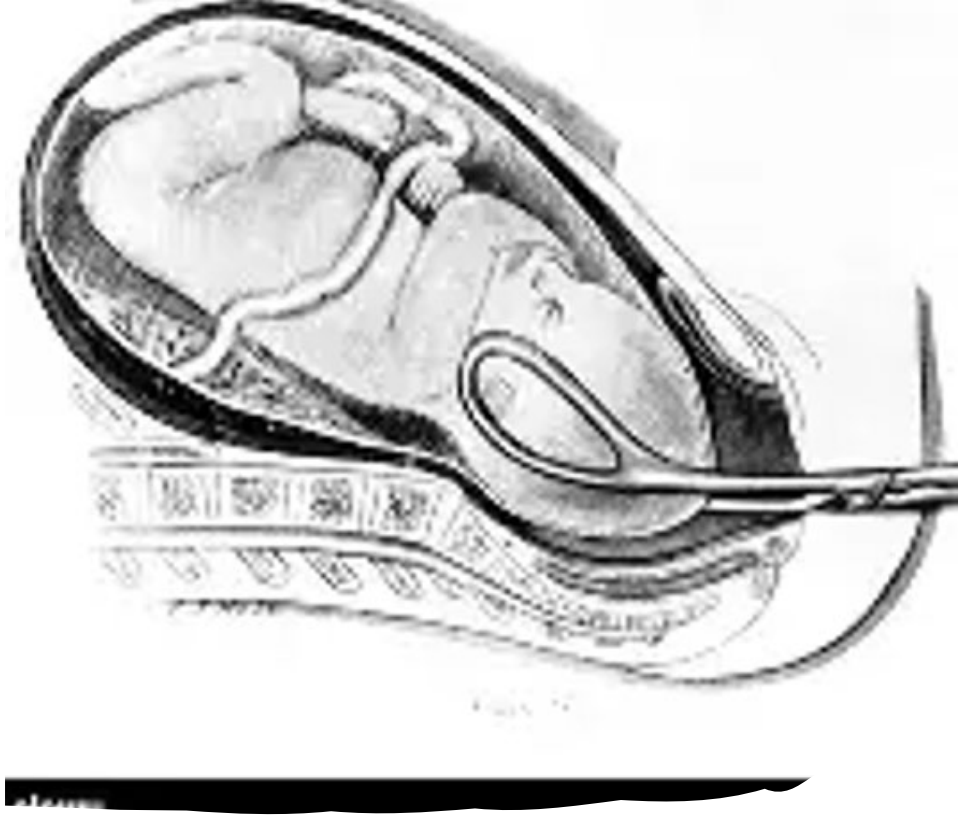

Birth Related molding

Birth Related Molding



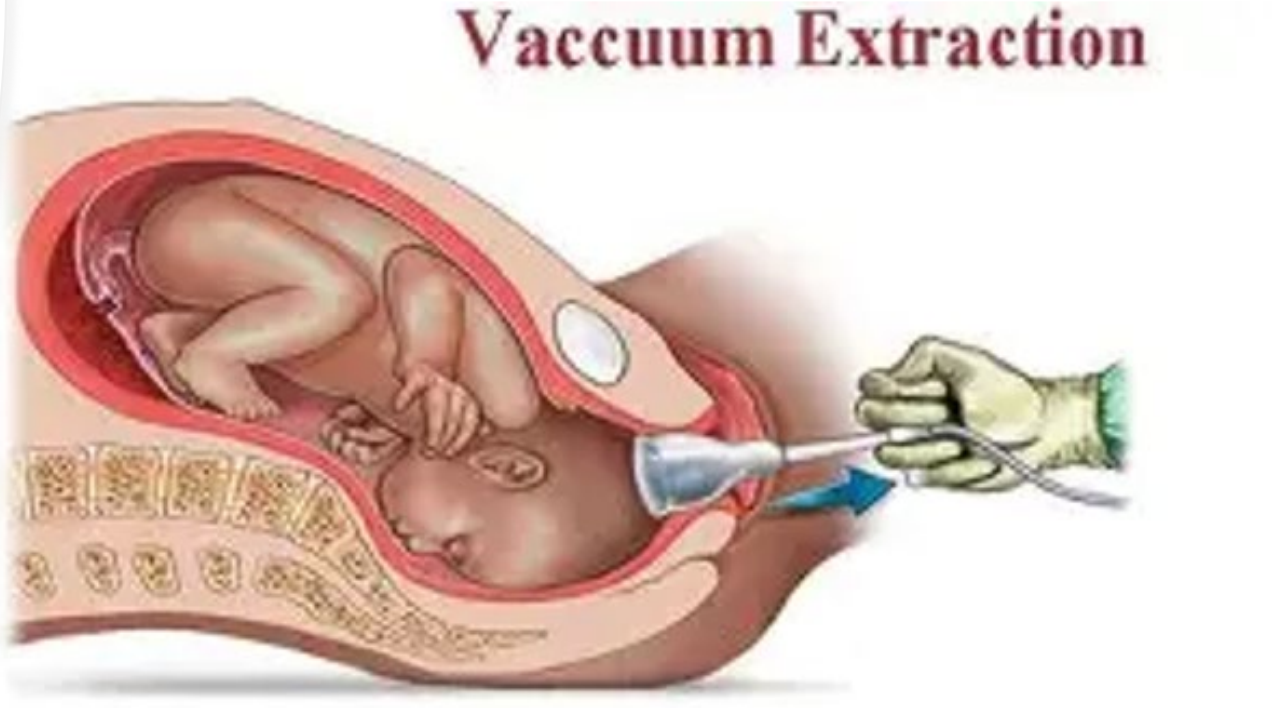

	CAPUT SUCCEDANEUM	CEPHALOHEMATOMA
	Swelling of the scalp itself, not involving bleeding under the skull	A collection of blood between baby's scalp and skull
	 CAPUT SUCCEDANEUM (C.S) C.S=Cross Suture Lines	
CAUSE	Caused by prolonged pressure being exerted on baby's head during delivery by a dilated cervix or vaginal walls **Using forceps or extraction tools can increase chances	Commonly caused by blood vessels that were damaged during labor and delivery **May be damaged from difficult delivery, forceps, or vacuum extraction
LOCATION	Extends across suture lines; not well defined	Well defined by suture; gradually developing, hard edge
SIZE	Size largest at birth, gradually subsides within 48 hours	Becomes larger after birth, then disappears within 6-8 months
SYMPTOMS	• Puffiness/bulging around affected area • Bruising of baby's scalp • Increased molding (elongation) of baby's head • Newborn jaundice (not always)	• Accumulation of blood under the scalp and above baby's skull, causing bulging **Because of its location under the periosteum, you will probably not see any cut or bruise on the surface of the skin over the bulge
DAMAGE	Typically no underlying skull bone fracture	May have underlying skull bone fracture
TREATMENT	Almost always goes away on its own within a few days **If jaundice, light therapy	Let the body naturally reabsorb the collected fluid; will resolve within a few months **If complications arise, drain the blood

3D MRI Images Show How a Baby's Head Shape Changes During Labor in Incredible Detail

www.newsweek.com May 16, 2019

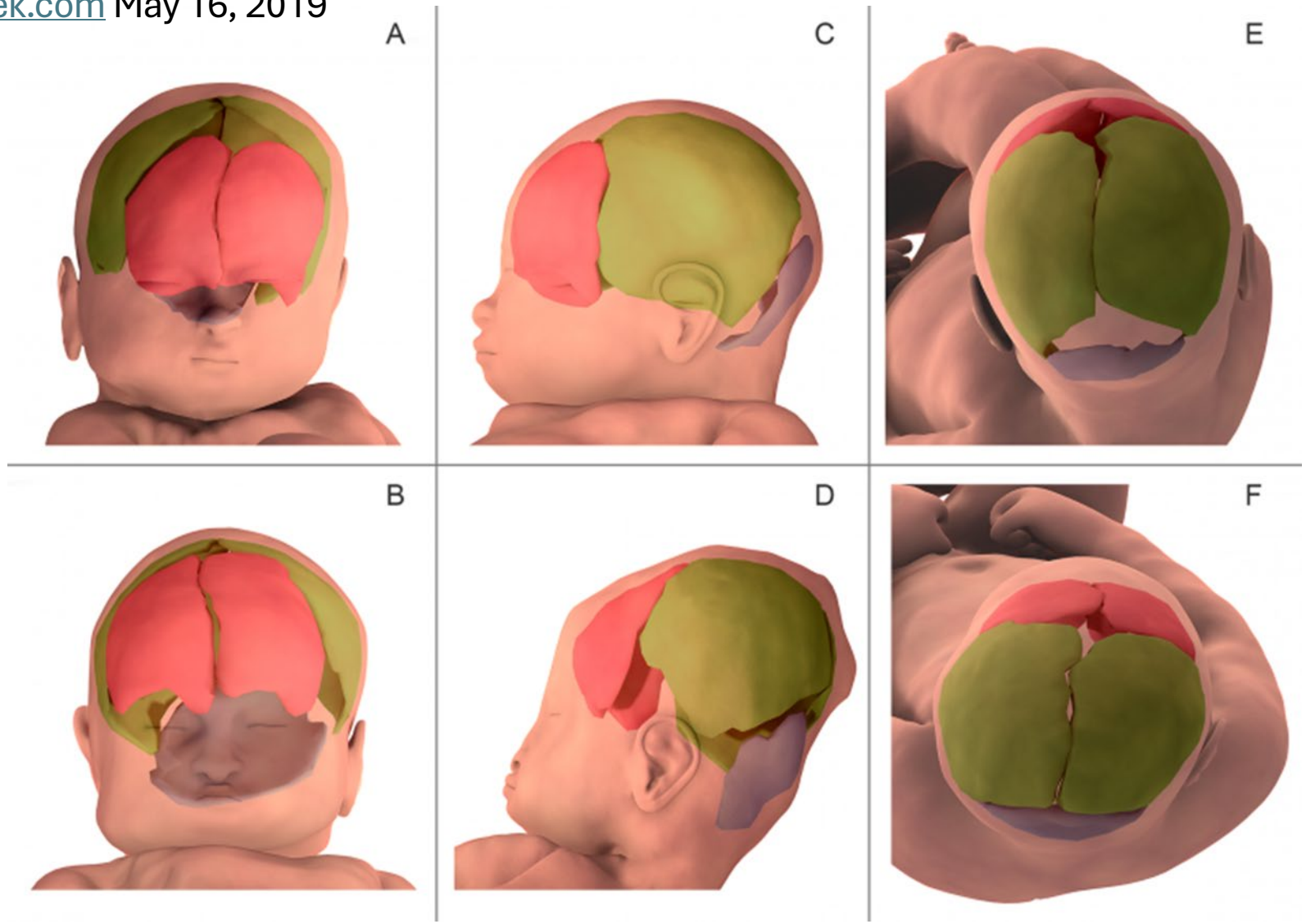

Three-dimensional fetal brain MRI reconstruction before labor (shown in purple in A, C, E) and during the second stage of labor (shown in orange in B, D, F). **PLOS ONE**

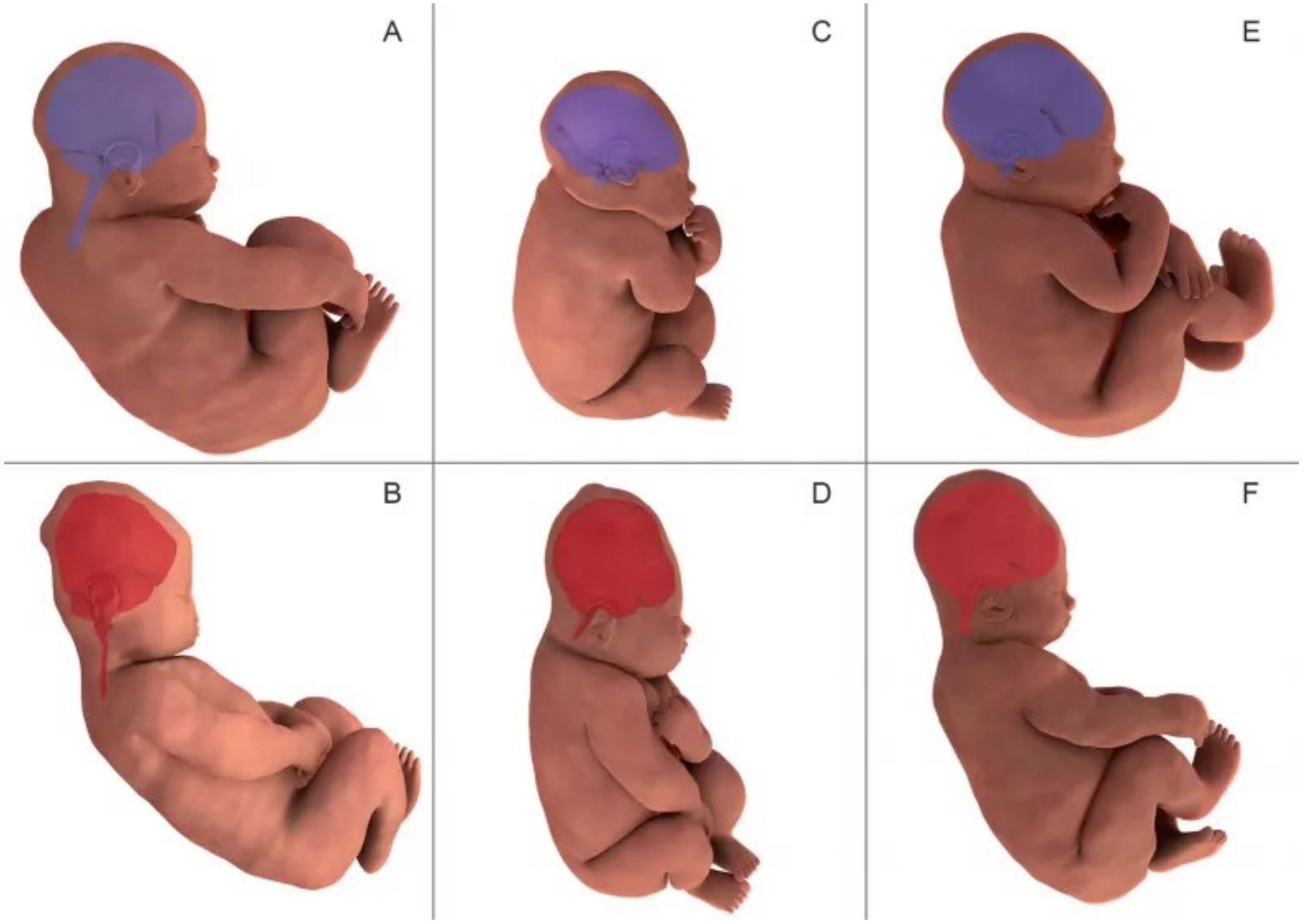

HEAD SHAPE

- **During the birth, the baby's head is compressed and the cranial plates overlap.**
- **This process is called molding**
- **Note depressed frontal bone**





Perform a Cranial Exam

- General observation before touching
- Head position and spontaneous movement
- Facial symmetry
- Resting posture and tone
- Alertness/state regulation
- Quality and symmetry of cry
- Observe feeding if appropriate



Newborn Skull

Newborn	24-48 hours	2 weeks
• During vaginal birth the cranium is deformed resulting in an elongated head shape	• The cranial bones slowly glide back into place leaving the infant with a more rounded head	• NO visible displacement of the cranial bones

Head shape and cranial symmetry

- View from anterior, posterior, lateral, and superior perspectives
- Assess for plagiocephaly/brachycephaly
- Frontal and occipital symmetry
- Ear position
- Facial/orbital symmetry
- Measure head circumference when indicated



Scalp, sutures, and fontanelles

- Inspect/palpate scalp
- Anterior and posterior fontanelles
- Sagittal, coronal, lambdoid, and metopic sutures
- Look for unusual ridging, widening, overlapping, swelling, or asymmetry
- Distinguish positional molding from findings warranting medical evaluation

Cervical and craniovertebral assessment

- Resting head rotation
- Active cervical movement
- Gentle passive ROM when appropriate
- Upper cervical symmetry
- SCM tone and symmetry
- Screen for torticollis





Eyes and visual responses — CN II, III, IV, VI

- Pupil size/symmetry and light response
- Eye position
- Fixation
- Tracking appropriate to developmental age
- Conjugate eye movements
- Observe for persistent strabismus or nystagmus



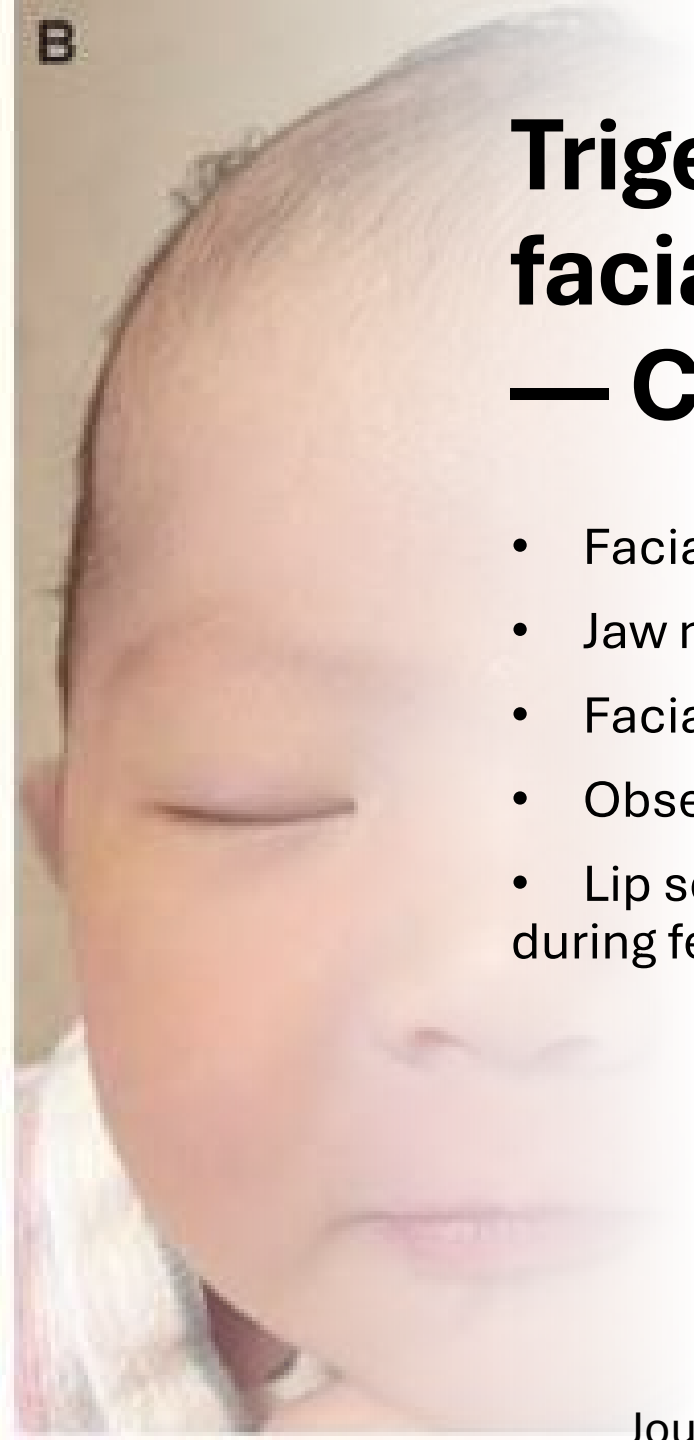

Trigeminal and facial function — CN V & VII

- Facial response to light touch
- Jaw movement
- Facial symmetry at rest
- Observe during crying
- Lip seal and facial movement during feeding

Journal of Pediatrics

Auditory/vestibular function — CN VIII

- Response to sound
- Startle/orienting response as developmentally appropriate
- Observe head/eye responses and balance in older infants



Oral cavity and feeding examination — CN V, VII, IX, X & XII

- Palate and oral structures
- Tongue position and movement
- Suck strength and rhythm
- Suck–swallow–breathe coordination
- Gag when clinically indicated rather than routinely provoking it
- Voice/cry quality
- Signs of coughing, choking, fatigue, or aspiration during feeds



Primitive reflexes and neurologic integration

- Rooting
- Suck
- Moro
- Palmar grasp
- Plantar grasp
- ATNR
- Galant and stepping




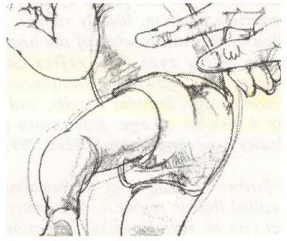



Final neurologic and musculoskeletal integration

- Muscle tone
- Symmetry of spontaneous movement
- Upper/lower extremity movement
- Head control appropriate for age
- Sensory responsiveness
- Compare right versus left
- Correlate cranial findings with cervical, neurologic, feeding, and developmental findings





Cranial adjusting vs Craniosacral technique

Effects Sensory, Mechanical, autonomic mechanisms and neurophysiology	Reduction in Muscle guarding
Alter sensory input from skin and fascia	Changes in breathing and relaxation
Modulation in pain perception	Autonomic nervous system changes

- Developed from cranial osteopath (W. Sutherland)
- Dura Mater- Mechanical connection surrounding the brain and spinal cord and continues down spinal canal to sacrum.
- SOT-DeJarnette
- Dynamic Body Balancing
- Upledger

Neurophysiology of Pediatric Chiropractic Care

Restoring Function Through the Nervous System

DYSFUNCTION PATHWAY
(After Intrauterine Constraint / Birth Stress)

MECHANICAL CONSTRAINT
Sustained pressure and limited fetal movement

↓

JOINT RESTRICTION
Reduced motion in cervical, thoracic, or pelvic joints

↓

MUSCLE HYPERTONICITY
Protective guarding and muscle imbalance

↓

ALTERED SENSORY INPUT
Abnormal input from joints, muscles, and fascia

↓

ALTERED NEURAL PROCESSING
Changes in proprioceptive processing and motor output

↓

CLINICAL OUTCOMES
- Head preference / torticollis
- Limited range of motion
- Feeding difficulties
- Positional plagiocephaly
- Delayed or asymmetric motor development

NEUROPHYSIOLOGICAL MECHANISMS

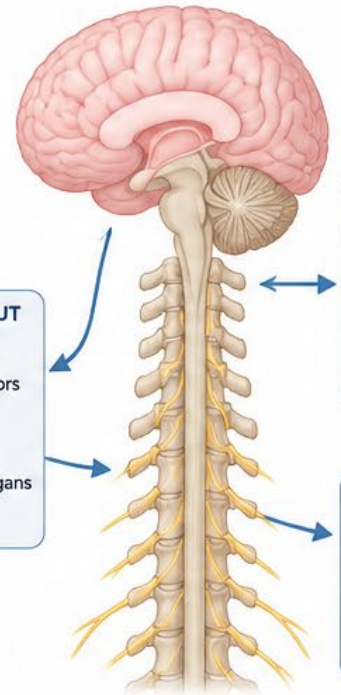

SENSORY INPUT (AFFERENT)
- Mechanoreceptors
- Proprioceptors
- Muscle spindles
- Golgi tendon organs
- Joint receptors

CENTRAL PROCESSING (BRAIN & CNS)
- Integration
- Modulation
- Motor planning
- Autonomic regulation

MOTOR OUTPUT (EFFERENT)
- Somatic (muscles)
- Autonomic (viscera, blood flow, glands)
- Postural control

NEUROMUSCULAR RESPONSE
- Muscle activation and tone
- Joint stability and mobility
- Postural adaptation
- Coordinated movement

CHIROPRACTIC EFFECTS
(Proposed Mechanisms)

RESTORED JOINT MOBILITY
Improved joint motion reduces abnormal mechanical stress

↓

NORMALIZED SENSORY INPUT
Improved afferent feedback from joints, muscles, and fascia

↓

IMPROVED NEURAL PROCESSING
Enhanced integration and motor control in the CNS

↓

REDUCED MUSCLE HYPERTONICITY
Decreased guarding and improved muscle balance

↓

IMPROVED CLINICAL OUTCOMES
- Symmetrical head movement
- Improved range of motion
- Better feeding and comfort
- Enhanced motor development
- Improved overall function

KEY CONCEPT Gentle chiropractic care aims to reduce mechanical interference, restore normal joint motion, and support optimal nervous system function to promote improved neuromuscular outcomes.

→ Normal Neurophysiological Pathway
- - → Dysfunction Pathway
- - → Proposed Effect of Chiropractic Care

Dural Attachments – The Craniosacral Connection

The dura mater is a continuous membrane that connects the cranium, spinal canal and sacrum, providing a mechanical link within the craniosacral system.

1. Cranial Attachments

The dura mater attaches to the cranial bones at specific sites, forming folds and reflection points.

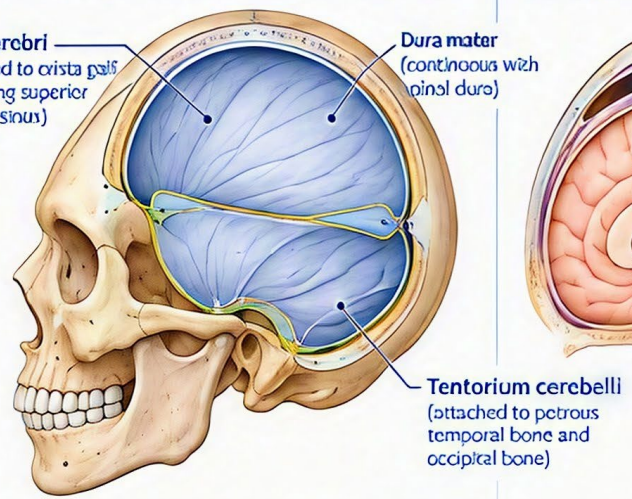

2. Meningeal Layers and Dural Folds

The dura mater forms key folds that provide stability and help maintain CSF circulation.

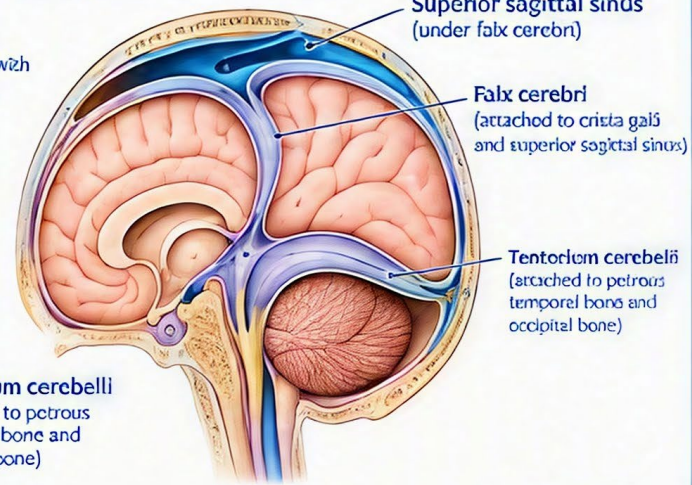

3. Spinal Dural Attachments

The spinal dura mater is anchored along the vertebral column and extends from the foramen magnum to the sacrum, where it continues as the filum terminale.

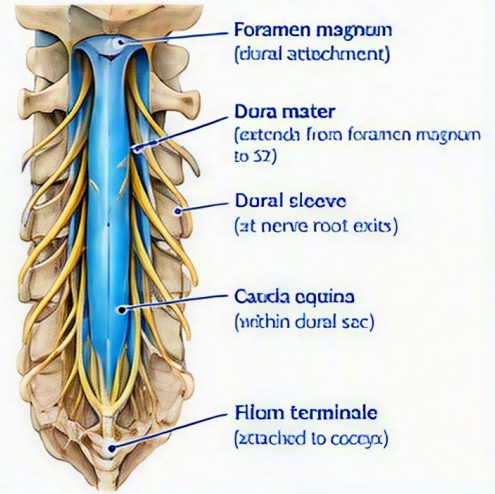

Dural Attachments Summary

- **Cranium**
  - Falx cerebri: crista galli and superior sagittal sinus
  - Tentorium cerebelli: petrous temporal bone and occipital bone
  - Dura mater: adheres to inner table of cranial bones (e.g., frontal, parietal, occipital)
- **Spine**
  - Foramen magnum (cranial end)
  - Vertebral canal (along vertebral bodies and posterior elements)
  - Nerve root sleeve (at each level)
  - Continues as filum terminale to sacrum
- **Sacrum**
  - Attaches to periosteum of sacral canal and coccyx

4. Sacral Attachments

The dura mater continues to the level of the sacrum, where it anchors to the sacral canal and coccyx.

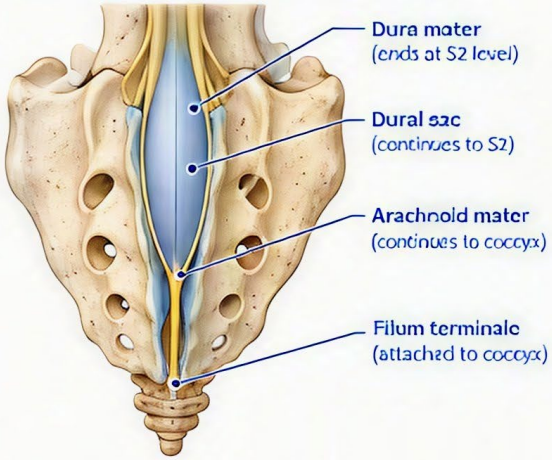

5. Continuity of the Dura

The dura forms a continuous pathway from the cranium to the sacrum, linking the entire craniosacral system.

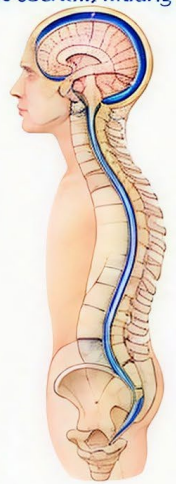

Cranium
(falx & tentorium)
↓
Spinal canal
(dura mater)
↓
Sacrum
(dural attachment)
↓
Coccyx
(filum terminale)

Cross-section: Meninges and Dural Attachments

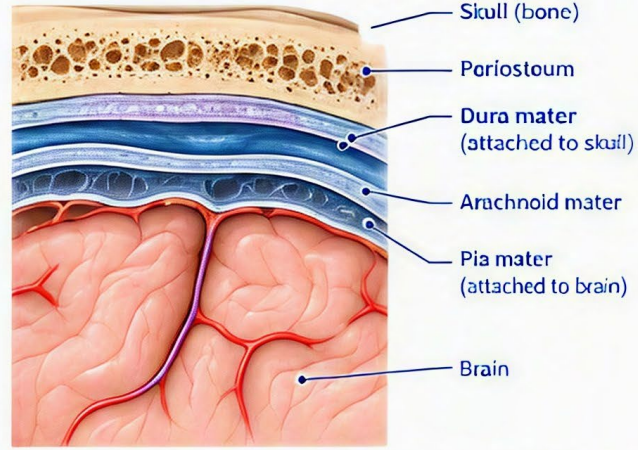



CLINICAL APPROACH

Observe → Screen → Palpate → Differentiate → Decide → Intervene conservatively → Reassess

Just a reminder…



- We are big, they are small.
- Be aware of how much area one finger covers on the fetal skull!
- Move slowly, respectfully, cautiously and gently

Sometimes it is difficult to assess pain in children who are non-verbal. The FLACC Pain Scale is a system that can help parents and professionals assess pain levels in children who have limited or no expressive communication. The diagram shows the categories for scoring. Zero, one or two points are given to each of the five categories: Face, Legs, Activity, Cry and Consolability.

Interpreting the Behaviour Score
Each category is scored on the 0-2 scale, which results in a total score of 0-10

0	relaxed and comfortable	4-6	moderate pain
1-3	mild discomfort	7-10	severe discomfort of pain or both

Categories ▼	Score Zero ▼	Score One ▼	Score Two ▼
Face F	No particular expression or smile	Ocasional grimace or frown, withdrawn, disinterested	Frequent to constant quivering chin, clenched jaw
Legs L	Normal position or relaxed	Uneasy, restless, tense	Kicking or legs drawn up
Activity A	Lying quietly, normal position moves easily	Squirming, shifting back and forth, tense	Arched, rigid or jerking
Cry C	No crying (awake or asleep)	Moans or whimpers, occasional complaint	Crying steadily, screams or sobs, frequent complaints
Consolability C	Content, relaxed	Reassured by occasional touching, hugging or being talked to, distactable	Difficult to console or comfort

If a child is showing these behaviours, it doesn't necessarily mean that they are in pain, as some of the behaviours measured by the FLACC scale can happen for other reasons. However, parents are advised to follow up high scores with a professional



Chiro Fun Fact #1

- The occiput is in how many pieces at birth
  - 1,
  - 2
  - 3
  - 4



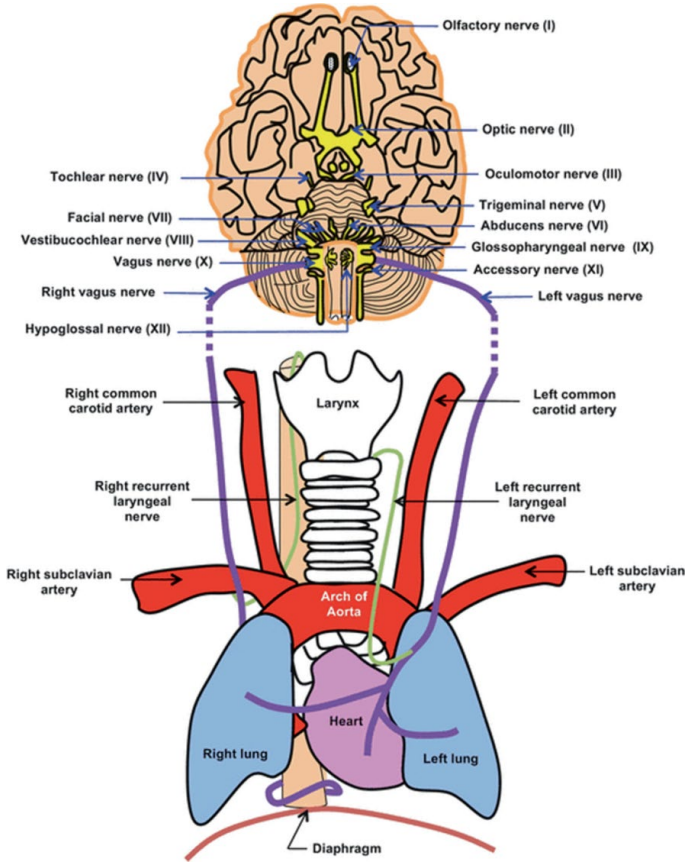



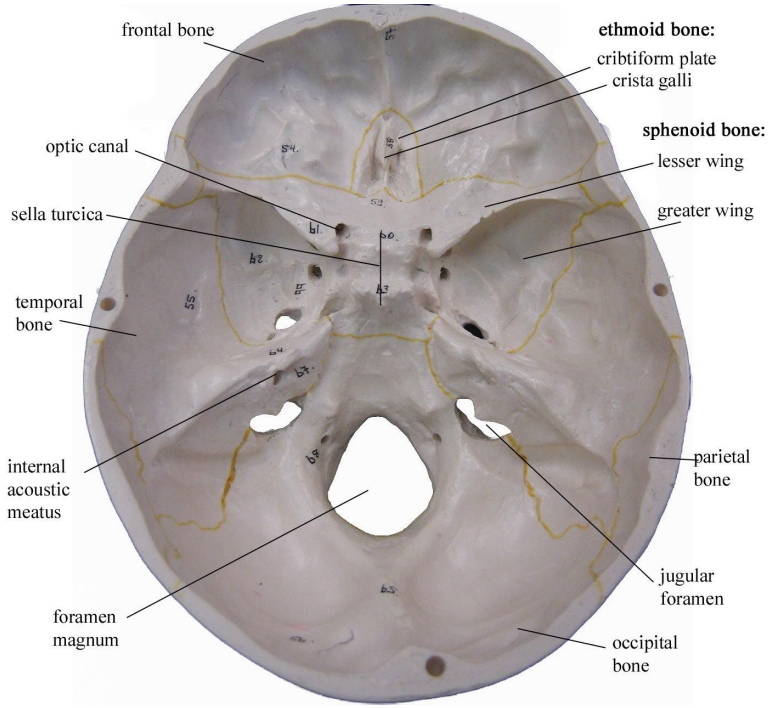

Brain Stem-Vagus Nerve-Cranial Vault-Chiropractic



Why chiropractic and What do we look for ?

- Suck-swallow-breathe: Vagus , Hypoglossal, Glossopharyngeal
- Heart and respiratory rate-Vagus Nerve
- Location-Jugular foramen, Occiput
- Medulla Oblingata-

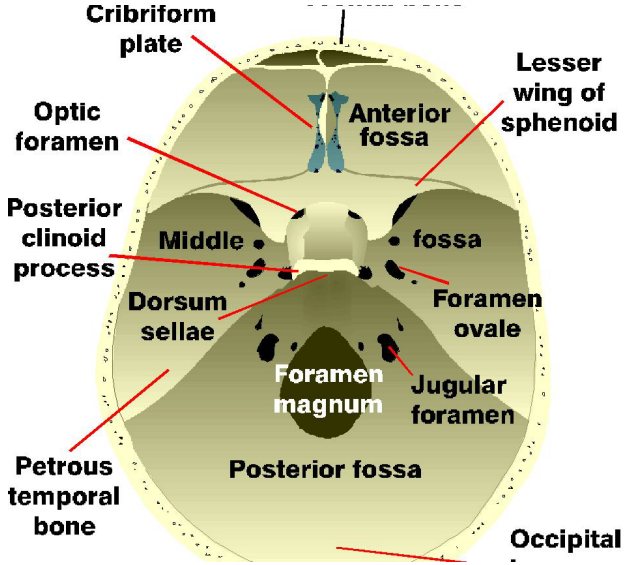

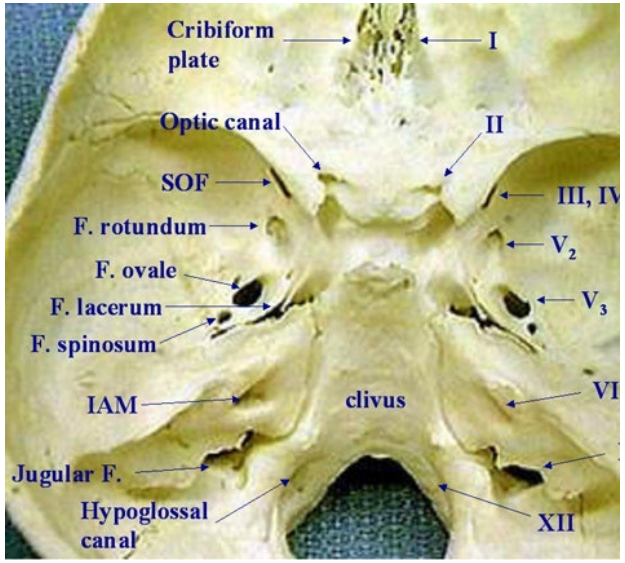

Foramen magnum	• Spinal cord
Hypoglossal canal	• Hypoglossal nerve (motor to the tongue)
Jugular foramen	• Glossopharyngeal, Vagus and Spinal accessory

Autonomic Nervous System

- Parasympathetic: Regulates respiratory rhythm, heart rate, airway tone, swallowing, GI function

- Sympathetic (T1-T5) Influences Bronchodilation, pulmonary vasculature, cardiac output, airway stability

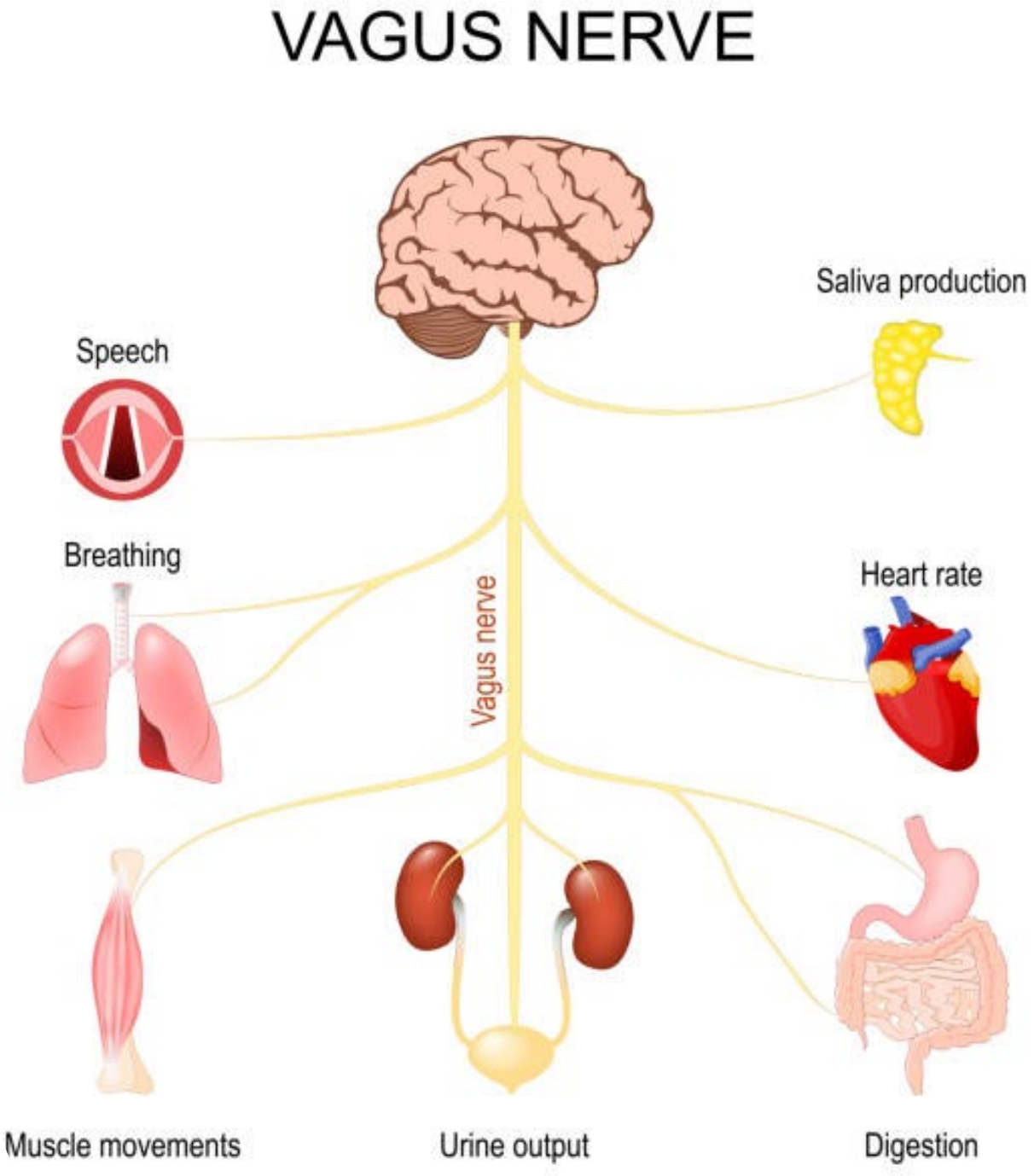

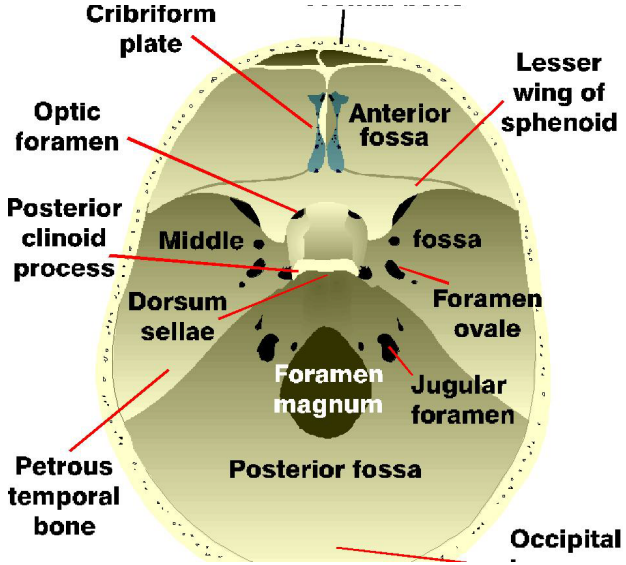

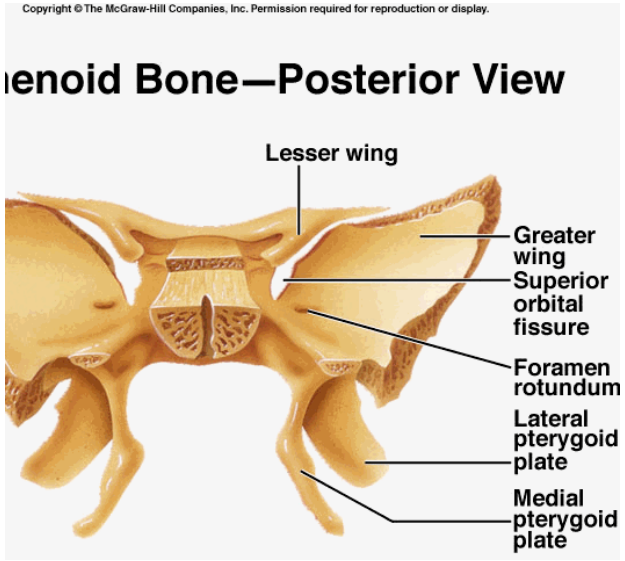

Superior orbital fissure	Oculomotor, trochlea, abducent and ophthalmic division of trigeminal
Optic canal	Optic nerve
Foramen rotundum	Maxillary division of trigeminal nerve
Foramen ovale	Mandibular division of trigeminal nerve

CRANIAL NERVE	FORAMEN	NEONATAL REFLEX
V Trigeminal	V1. Ophthalmic Exits with eye muscle group (superior orbital fissure, through orbit to superior orbital notch/foramina) V2. Maxillary Exits foramen rotundum through wall of maxillary sinus to inferior orbital foramina) V3. Mandibular Exits foramen ovale to mandibular foramen to mental foramen	Phasic Bite, Rooting, Suckling
VII Facial	Internal Auditory Meatus with VIII	Rooting, Suckling
IX Glossopharyngeal	Jugular Foramen	Gag, Suckling
X Vagus	Jugular Foramen	Cough, Gag, (reflux, vomiting)
XI Accessory	Jugular Foramen	Rooting
XII Hypoglossal	Hypoglossal Canal (occipital)	Lateralization and protrusion of tongue, rooting and suckling

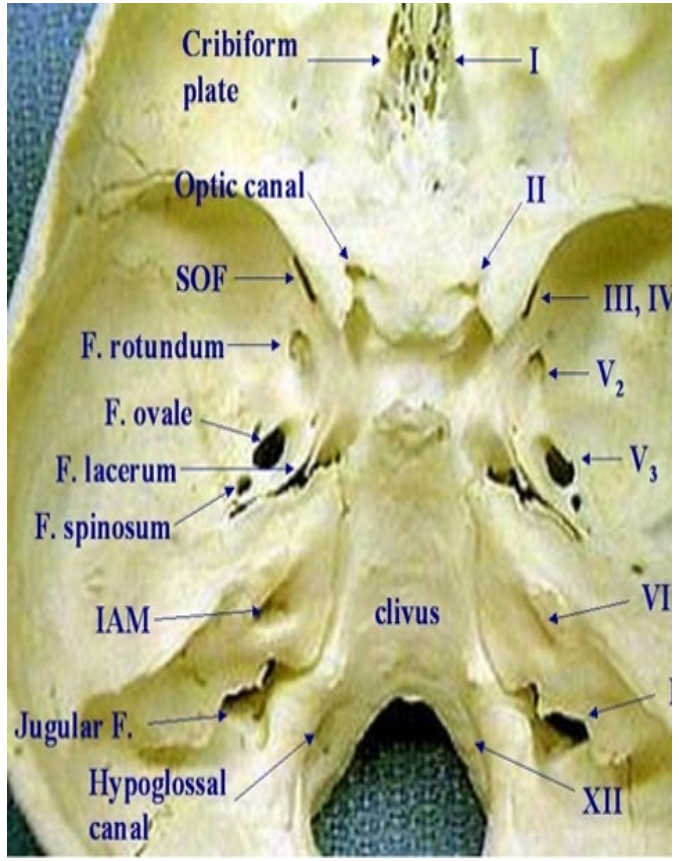

Infant Spine

Infant Spine – Anatomy and Normal Alignment

The infant spine is more flexible, with unique anatomical features that support growth and development.

Lateral View – Infant Spine

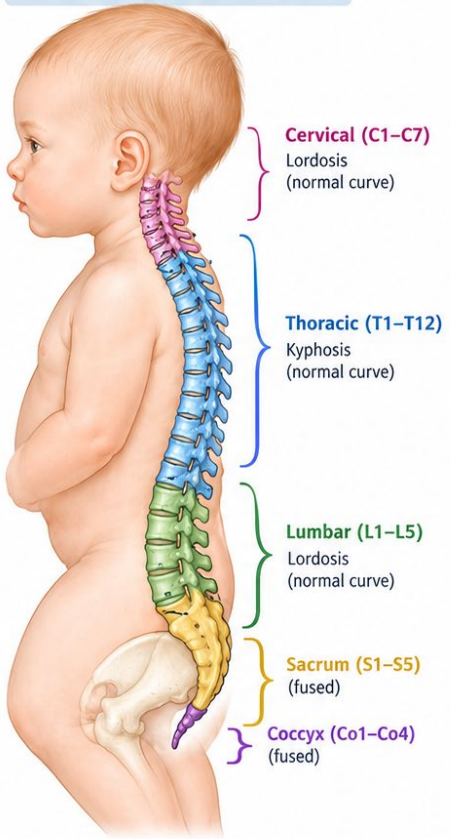

Close View – Vertebral Column

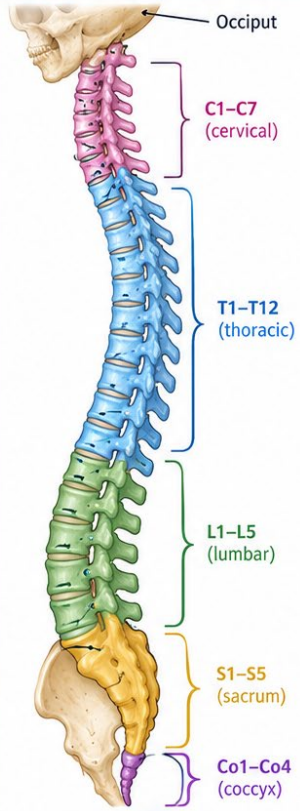

Key Features of the Infant Spine

- **Increased flexibility**
  Ligaments are more elastic, allowing for greater movement and adaptation.
- **Larger head-to-body ratio**
  The head is proportionally larger, influencing spinal alignment and posture.
- **Less developed curvature**
  Curves are present but less pronounced than in adults.
- **More cartilage**
  Growth plates (epiphyseal plates) are open, allowing for continued growth.
- **Higher risk of injury**
  The spine is more vulnerable to trauma and requires gentle handling and support.

Infant vs. Adult Vertebrae

Infant Vertebra



- Less ossified (more cartilage)
- Larger, rounder vertebral body
- More horizontal facet joints
- Thinner neural arch
- Greater flexibility

Adult Vertebra



- More ossified bone
- Larger, more rectangular vertebral body
- More vertical facet joints
- Thicker neural arch
- Less flexible

Key Takeaways

- The infant spine has natural curvatures, but they are less pronounced.
- Flexibility and mobility are greater than in adults.
- Growth plates are open, supporting ongoing development.
- Gentle handling and proper support are essential for healthy spinal development.

Anatomy

- Atlas ossifies from three centers.
- One in each lateral mass at 7 weeks and gradually extends the length of the posterior arch until fusion occurs at 3-4 years of age.
- The third ossification center appears in the anterior arch at year one and fuses with the lateral masses between 6-8 years of age.
- ***The first vertebra to ossify***

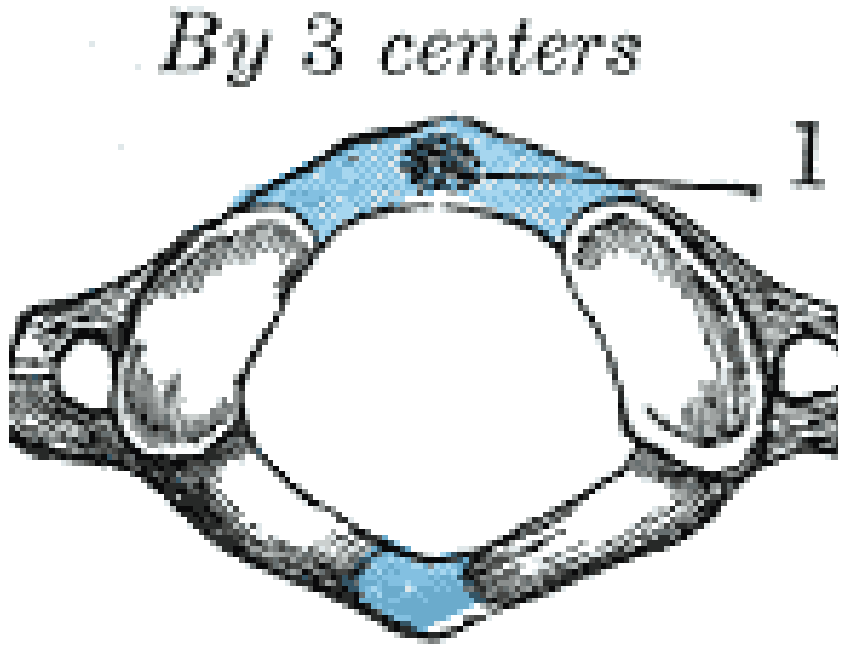

Biomechanics – Latero-flexion

H Biedermann. Manual Therapy in Children, 2004.

- Adults and bigger children atlas moves under the occiput toward the concave side of the head



- Small children (before verticalization) Atlas moves to the “upper” or convex side



Biomechanical Features

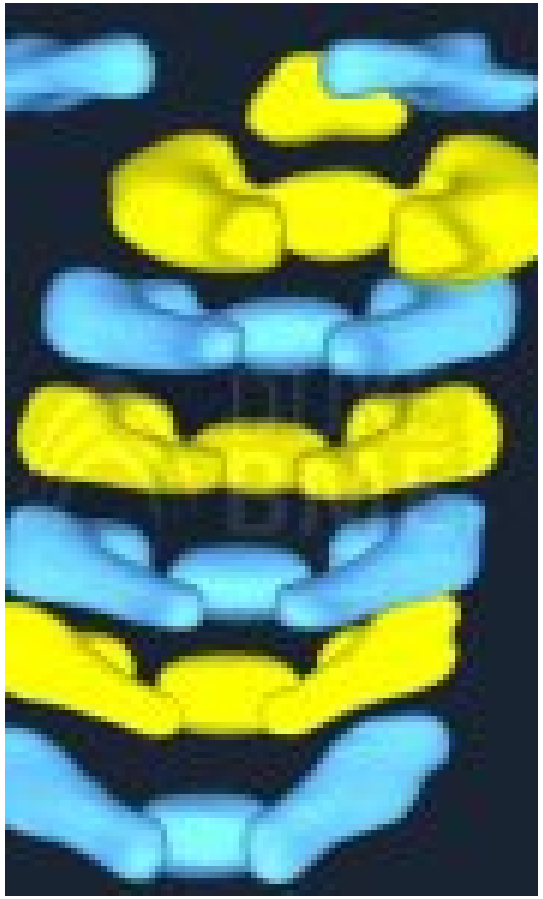

On lateroflexion (frontal plane) the atlas does not move into the concavity as it does in adults, but it moves in the convexity (Biedermann 1999)

The infant cervical spine appears much more extended in the saggital plane

- (von Kortzfleisch1993)

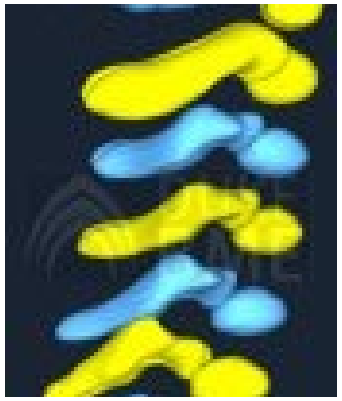

Incomplete uncinate processes and wedge-shaped vertebra, lax ligaments and developing muscles result in greater instability within the cervical spine

The spinal cord is 8 times more vulnerable to stretch/traction forces as compared to the postural soft tissue structures

Allowing for subluxation and or spinal cord injuries

Seated Occipital Glide

Gently support the infant's head

Guide the occiput P-A diagonally though the condyle





Photo Dr O'Neill

Seated Occipital Glide





Photo Dr. O'neill

Seated Occipital Glide (right)



Photo Dr. O'Neill

- Light traction
- Fingertips guide the occiput A-P as the superior hand helps guide the head into flexion



If a thrust is introduced to correct the AS Occ (Gonstead) you must stabilize the C1 posterior arch.

Photo Dr. O'Neill





Cranial therapy of the Occiput



Cranial therapy of the Occiput

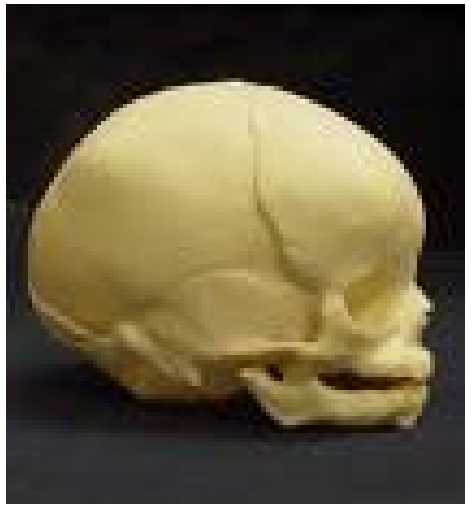

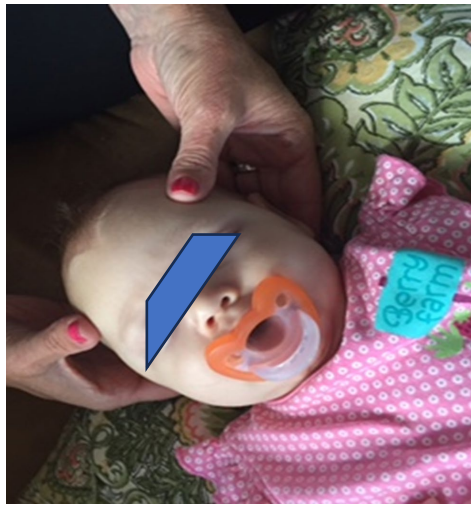

Occiput


Berry farm



Thank you

