Identification of High Risk Patients for Chiropractic Care…
How to Avoid a Catastrophic Event

JOHN D. LOCKENOUR DC, DABCO, DABCA



CONTRAINDICATIONS TO AND COMPLICATIONS OF ADJUSTIVE THERAPY

Dysfunction may be associated with, or concomitant with, conditions that contraindicate various forms of manual therapy. **A complication is defined as a problem that occurs after the application of a procedure**. A contraindication is a problem identified before a procedure is applied that would make application of the treatment inadvisable because of its potential to cause harm or delay appropriate treatment. **Manual therapy is contraindicated when the procedure may produce an injury, worsen an associated disorder, or delay appropriate curative or life-saving treatment**. Although certain conditions may contraindicate thrusting forms of manual therapy, they may not prohibit other forms of manual therapy or adjustments to other areas.

Serious injuries resulting from adjustive therapy are very uncommon. Suitable adjustive therapy is less frequently associated with iatrogenic complications than many other health care procedures. **The majority of spinal manipulation complications arise from misdiagnosis or improper technique. In nearly all situations, injury can be avoided by sound diagnostic assessment and awareness of the complications of and contraindications to manipulative therapy.** Conditions that contraindicate or require modification to spinal manipulation will be discussed. The most serious complications arise from cervical manipulation and damage to the vertebral artery or in the lumbar spine as a complication of midline disc herniations.

57. PG Shekelle, AH Adams: In The appropriateness of spinal manipulation for low-back pain: Project overview and literature review. 1991, RAND, Santa Monica, Calif.58. JP Ladermann: Accidents of spinal manipulations. Ann Swiss Chiro Assoc. 7, 1981, 161.59. DA Brewerton: Conservative treatment of painful neck. Proc R Soc Med. 57, 1964, 16.60. AM Kleynhans: Complications of and contraindications to spinal manipulative therapy. In S Haldeman (Ed.): Modern developments in the principles and practice of chiropractic. 1980, Appleton-Century-Crofts, East Norwalk, Conn.

Although the incidence of injury from manipulation is extremely low, mild associated transitory discomfort is not unusual. Adverse reactions to and complications of spinal thrust manipulation run the gamut from mild increased local discomfort to permanent neurologic complications or death. Senstad, Leboeuf-Yde, and Borchgrevink, using a prospective clinic-based survey, studied the frequency and characteristics of side effects of spinal manipulative therapy (SMT). Information regarding any unpleasant reactions after SMT was collected on 580 patients and 4712 spinal manipulative treatments by Norwegian chiropractors. The researchers report that at least 1 reaction was reported by 55% of the patients some time during the course of a maximum of 6 treatments. The most common reactions were local discomfort, headache, tiredness, or radiating discomfort. The patients rated the reactions as mild or moderate in 85% of the cases, with 64% of reactions appearing within 4 hours and 74% disappearing within 24 hours.

Medicare General Contraindications for Adjusting



Contraindications for adjusting the lumbar spine and pelvis

- Hypermobility of the articulation (joint)
- Bone destroying pathology (cancer)
- Inability of the patient to assume the adjusting position.



Cautions for adjusting the lumbar spine and pelvis

- Congenital anomalies
- Recent surgery
- Trauma
- Disc herniation
- Degenerative joint disease
- Certain medications



Medicare Relative Contraindications

- Dynamic thrust is the therapeutic force or maneuver delivered by the physician during manipulation in the anatomic region of involvement. A relative contraindication is a condition that adds significant risk of injury to the patient from dynamic thrust, but does not rule out the use of dynamic thrust. The doctor should discuss this risk with the patient and record this in the chart. The following are **relative contraindications** to dynamic thrust:
- • Articular hyper mobility and circumstances where the stability of the joint is uncertain;
- • Severe demineralization of bone;
- • Benign bone tumors (spine);
- • Bleeding disorders and anticoagulant therapy; and
- • Radiculopathy with progressive neurological signs.

Medicare Absolute Contraindications

- Dynamic thrust is **absolutely contraindicated** near the site of demonstrated subluxation and proposed manipulation in the following:
- • Acute arthropathies characterized by acute inflammation and ligamentous laxity and anatomic subluxation or dislocation; including acute rheumatoid arthritis and ankylosing spondylitis;
- • Acute fractures and dislocations or healed fractures and dislocations with signs of instability;
- • An unstable os odontoideum;
- • Malignancies that involve the vertebral column;
- • Infection of bones or joints of the vertebral column;
- • Signs and symptoms of myelopathy or cauda equina syndrome;
- • For cervical spinal manipulations, vertebrobasilar insufficiency syndrome; and
- • A significant major artery aneurysm near the proposed manipulation.

Causes of Claims

- 26% Adjustment causing injury to disc
- 15% Adjustment causing fracture
- 5% Adjustment causing CVA
- 4% P.T. burns or injury
- 6% Failure to diagnosis Cancer
- 6% Failure to diagnosis misc. medical conditions
- 7% Aggravation of pre-existing condition

Causes of Complications and Adverse Events

- Lack of knowledge
- Misdiagnosis
- Insufficient examination
- Poor clinical judgement
- Poor interprofessional cooperation
- Inappropriate technique application
- Lack of rational attitude and technique
- Unnecessary or excessive use of manipulation
- Cervical manipulation
- Presence of a herniated nucleus pulposus
- Presence of arteriosclerotic disease
- Presence of coagulation dyscrasias

Sources: Shekelle et al. (1991); Henderson (1992); Refshauge et al. (2002)

Red Flags for Spinal Manipulation

- Previous diagnosis of vertebrobasilar insufficiency
- •Signs and symptoms of spondylitis and spondylolisthesis
- •Previous history of joint or segment surgery
- •Facial/intra-oral anesthesia or paranesthesia
- •History of long-term steroid therapy
- •History of traumatic event suffering
- •Women at post-menopause
- •Patients with psychogenic complaints
- •Patients with nystagmus
- •Presence of osteopenia
- •Presence of scoliosis

- Diplopia or other visual disturbances
- •Ataxia of gait, coordination
- Dizziness/vertigo/giddiness/lightheadedness
- •Blurred vision
- Nausea
- •Sudden fall without loss of consciousness or drop attack
- •Sensation of ringing or buzzing in the ears
- •Presence of dysarthria
- •Signs of difficulty swallowing or dysphagia
- Aggravation of any of the above symptoms during manipulation
- •No improvement or worsening of symptoms following multiple manipulations

Sources: World Health Organization (2005); Puentedura et al. (2012)

Basic Rules for the Application of Manipulation

1. It is better not to adjust than to adjust incorrectly
2. It is more important to know when NOT to adjust than when to adjust
3. Be careful not to over adjust
4. Select the most specific technique for the problem
5. Position the patient for comfort
6. Articular and tissue slack should be taken up before thrust is applied
7. The doctor should visualize what you intend to accomplish
8. *Primo non nocerum* – first do no harm



Bergmann TF, Peterson DH, Lawrence D. Chiropractic Technique: Principles and Procedures. New York: Churchill Livingstone, 1993:51-122

Pre-Existing Contraindications for L-Spine

1. Cauda Equina Syndrome
2. Spinal Fracture
3. Osteomyelitis
4. Metastatic Cancer
5. Instability
6. Unstable Spondylolisthesis
7. Unstable AAA

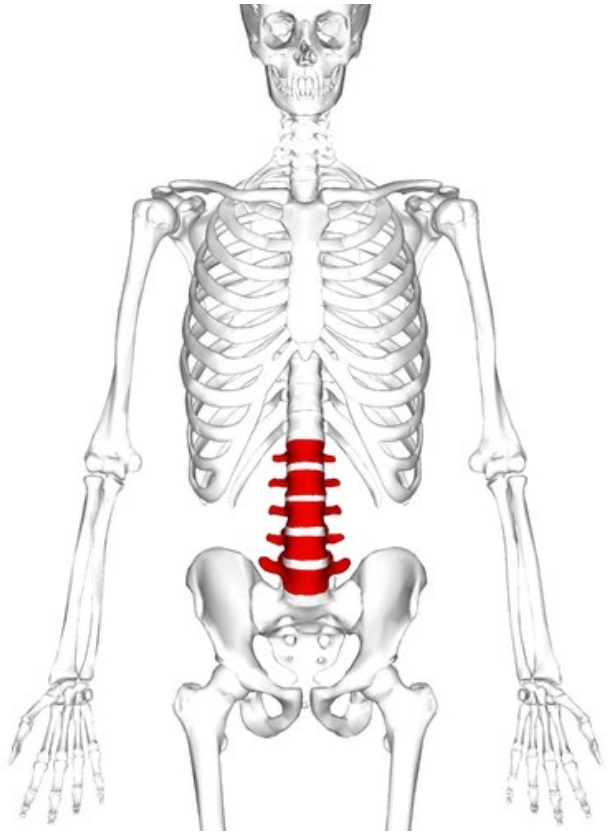

Recommendations for Lumbar Spine

SIDE POSTURE ADJUSTMENTS

1) Avoid Lumbar Rotation when doing Side Posture
   - In shear stress applied to the intervertebral Joint, 2/3rds of the stress is borne by the disc and 1/3 by the facets
   - Normal IVD fail completely at 22.6 degrees of rotation in cadavers.
     1) Farfan H, Cossette J, Robertson GH, The Effects of torsion on the lumbar spine. J Bone Joint Surg AM 1970, 52-: 468-497
2) Pre-Load the Joint before applying a dynamic thrust

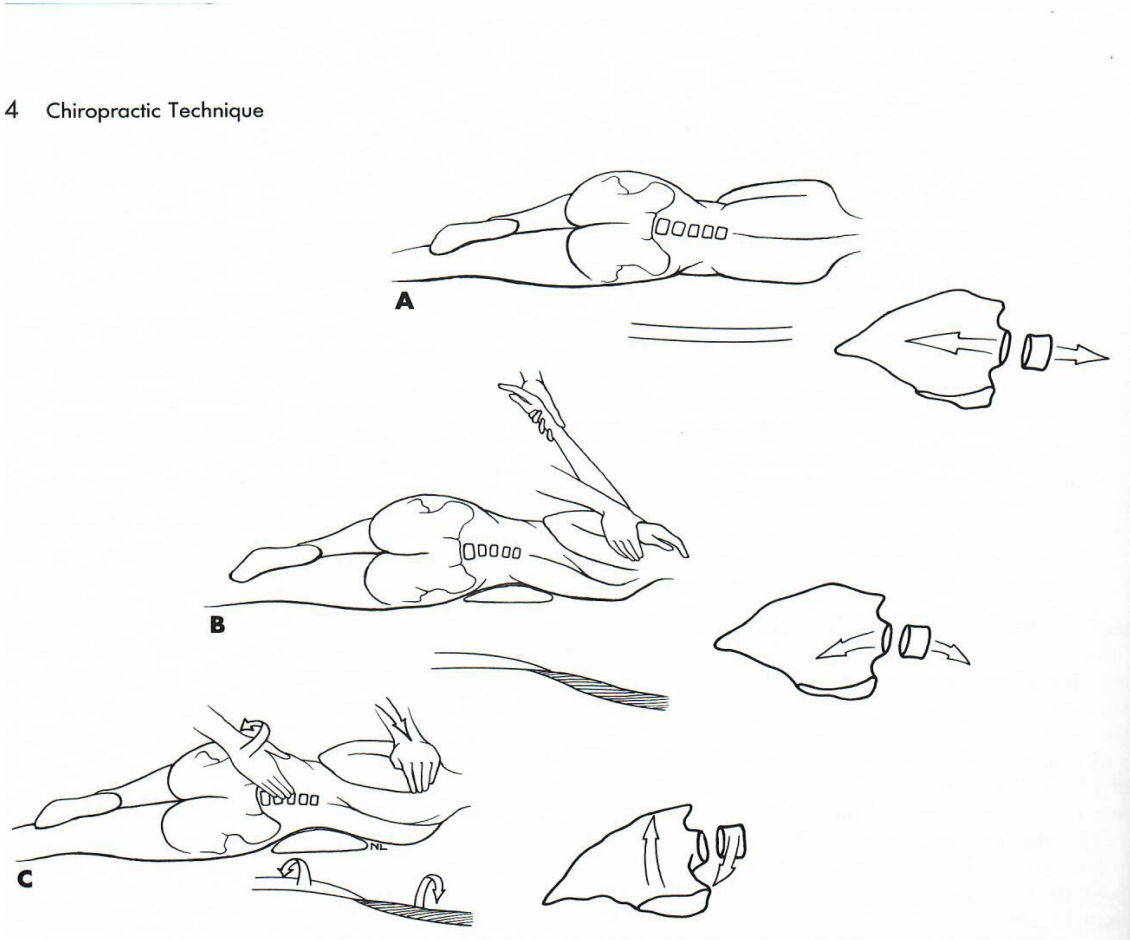

Recommendations for Lumbar Spine

3. Consider Imaging when treating Disc Syndromes
4. Recommend Trial Treatment 2-4 weeks



James Cox, DC, DABCR

- Disc Bulge 95% Response
- Disc Herniation 75% Response
- Sequestered Disc 50% Response

When Does a Patient Become a Surgical Candidate?

1. Incapacitation pain in leg below the knee
2. MRS Signs are Positive (getting worse)
3. Failure of Conservative Treatment 4-8 weeks
4. Positive MRI with Poor Response to Treatment

Treatment of the Osteoporotic Patient



Chiropractic Considerations

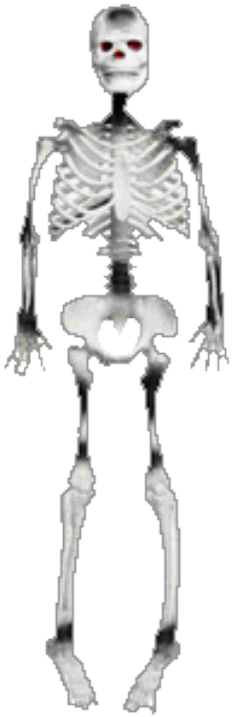

Assess all patients

Be aware of risky areas

*Ribs

*Mid-back

*Hip





When the Unexpected Happens: Managing Rib Fractures in Your Practice

WHAT YOU NEED TO KNOW

- Thoracic adjustments are an integral part of care, and while rib injuries are rare, they are not unheard of, particularly in patients with pre-existing conditions or comorbidities.
- Having informed consent, thorough documentation, and a clear, professional explanation of care can significantly reduce exposure and help effectively resolve such situations.
- Responding promptly, explaining care in accessible terms, and offering a willingness to collaborate can often transform adversarial situations into opportunities for resolution.

Thoracic adjustments are an integral part of care, and while rib injuries are rare, they are not unheard of, particularly in patients with pre-existing conditions or comorbidities. Navigating allegations of causing a rib fracture is tricky, but being willing to communicate directly with patients, having informed consent, and thorough documentation are the foundation to doing so successfully. In one case, a patient sought care following an auto accident, complaining of stiffness in their neck and back. During a prone adjustment, the doctor applied slightly more pressure than usual (admittedly) due to the patient's body type.

From the chiropractor's perspective, the adjustment appeared routine, with no immediate indication of harm. The patient didn't express discomfort following the adjustment, and the documentation reflected nothing out of the ordinary or abnormal.

However, a few days later, the patient visited the emergency room with rib pain and shortness of breath. X-rays revealed non-displaced fractures on both sides of the rib cage. The patient alleged that the adjustment caused the injuries, although medical records suggested the fractures could have resulted from another event.

The chiropractor's willingness to engage with the patient and address their concerns directly played a key role in resolving the claim quickly. While this instance escalated to a lawsuit, it's worth noting that having informed consent, thorough documentation, and a clear, professional explanation of care can significantly reduce exposure and help effectively resolve such situations.



The patient alleges that you fractured three ribs during the adjustment, causing pain and inability to work, and now they're seeking compensation, saying your care was negligent.

In a situation like this, it's important to address the complaint head-on rather than dismissing or avoiding it. Start by reviewing the patient's records to re-familiarize yourself with their history and care. Was there anything abnormal or unusual noted during their last visit? Was informed consent documented?

Once you've reviewed their file, call the patient to address their concerns empathetically and transparently. Explain your findings and offer to review their timeline of care together. Encourage them to share any relevant medical records from providers they've seen since their last visit.

This collaborative approach helps demonstrate your commitment to hearing their concerns and addressing their claim while maintaining professionalism.

Empathy is key. Patients who feel heard and respected are far less likely to escalate their concerns into formal claims. Responding promptly, explaining care in accessible terms, and offering a willingness to collaborate can often transform adversarial situations into opportunities for resolution.

Asking for supporting documentation, such as medical records, not only informs your response, but can also reinforce your diligence in addressing their concerns.



©2025 Dynamamic Chiropractic™

Recommendations for Low Bone Density Patients

1. Consider a DEXA Scan
2. Treat all Geriatric Patients as if they have Osteoporosis
3. Alter Adjusting Procedures to match the patient's condition
    1. Always use Drop Away Thoracic
    2. Avoid side posture "kick" manipulations
    3. Use Shallow depth with adjustments



Cerebral Vascular Issues

It is estimated that in the US over 100 million chiropractic visits occur annually. If it is assumed that one or more cervical adjustments occurs in half of these visits, then in the US there would be 62.5 million visits each year. This indicates that VBS is an extremely rare complication as compared with other therapeutic procedures.

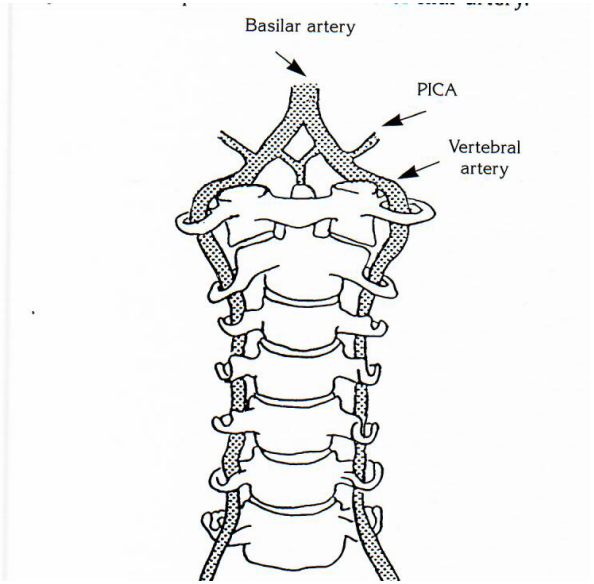

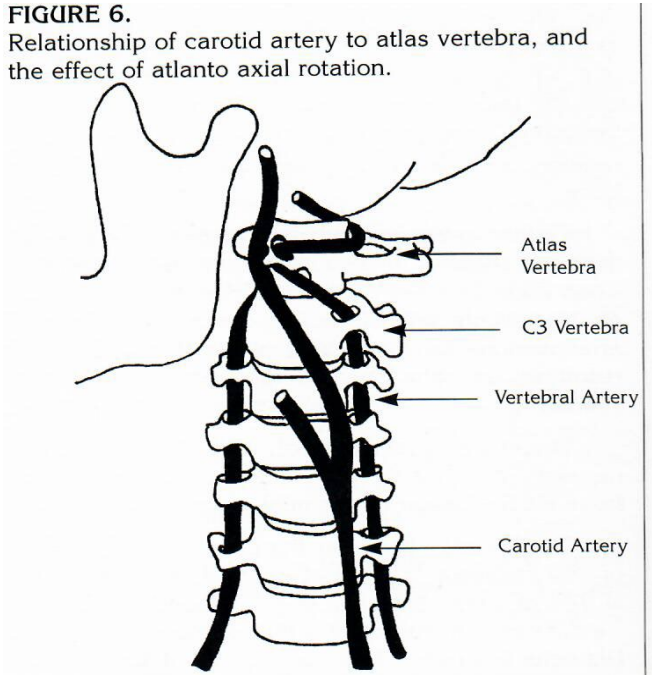

Onset of Signs and Symptoms

Analysis of 183 cases reveals time between SMT and onset of symptoms

- 69% during SMT
- 3% within minutes of SMT
- 9% within 1 hour of SMT
- 8% 1-6 hours of SMT
- 5% 7-24 hours after SMT
- 6% 24 hours or more after SMT

5 Ds and 3 Ns: Signs and Symptoms of Vertebrobasilar Ischemia

- Dizziness, vertigo, giddiness, light-headedness
- Drop attacks, loss of consciousness
- Diplopia, other visual disturbances
- Dysarthria
- Dysphagia Ataxia of gait, walking difficulties, incoordination of extremities
- Nausea, vomiting
- Numbness on one side of the face or body
- Nystagmus

- From Terrett AGJ: Current concepts in vertebrobasilar complications following spinal manipulation, West Des Moines, 2001, NCMIC Group.

VA Dissection is More Common with Covid-19

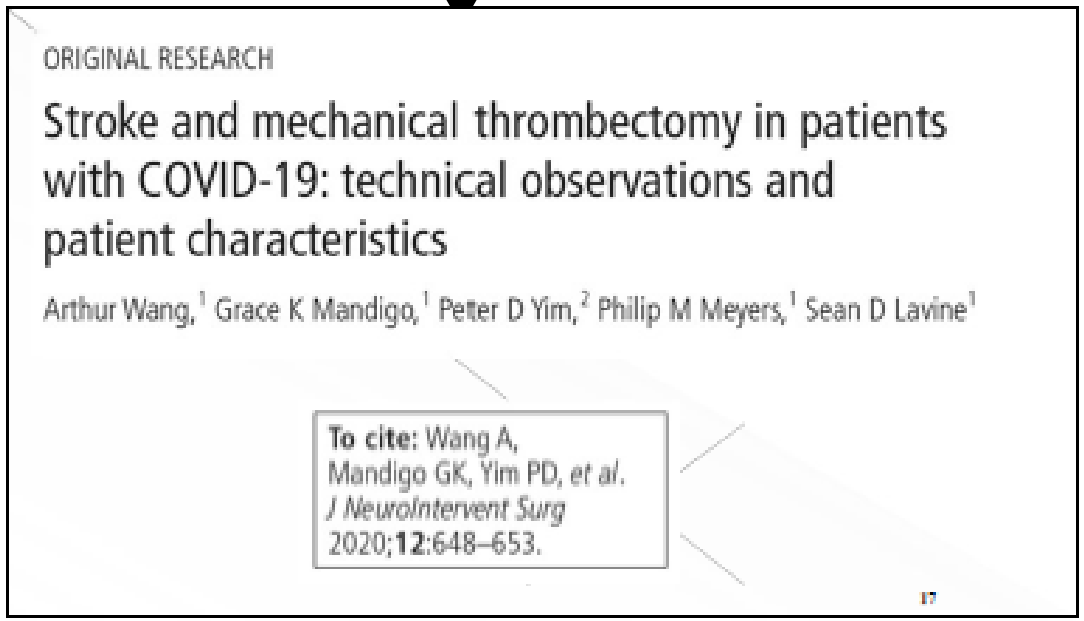

ORIGINAL RESEARCH

Stroke and mechanical thrombectomy in patients with COVID-19: technical observations and patient characteristics

Arthur Wang,[1] Grace K Mandigo,[1] Peter D Yim,[2] Philip M Meyers,[1] Sean D Lavine[1]

To cite: Wang A, Mandigo GK, Yim PD, *et al*. *J NeuroIntervent Surg* 2020;**12**:648–653.

17

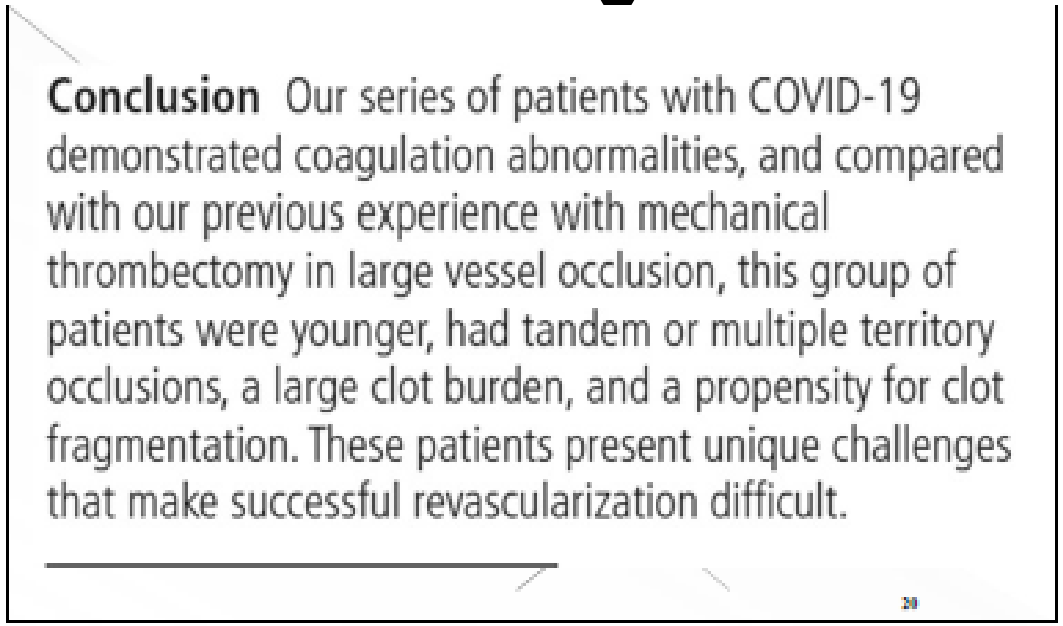

Conclusion Our series of patients with COVID-19 demonstrated coagulation abnormalities, and compared with our previous experience with mechanical thrombectomy in large vessel occlusion, this group of patients were younger, had tandem or multiple territory occlusions, a large clot burden, and a propensity for clot fragmentation. These patients present unique challenges that make successful revascularization difficult.

20

Major Presenting Complaint of Patients Who Subsequently had an SMT Induced VBS

- 47.4% Neck Pain and Stiffness
- 20% Neck Pain / Stiffness and Headache
- 16.3% Headache
- 6% Torticollis
- 2.2% L/B pain
- 1.5% Scoliosis, Head Cold, Thoracic Pain

High Risk Patients

- TIA
- Bruits
- Tobacco Use
- Oral Contraceptive
- Osteoarthritis
- Postpartum
- Migraine Headaches
- Dizziness
- Sudden Insidious Severe Head or Neck Pain
- Covid-19



Pre-Existing Contraindications for C-Spine

1. Down Syndrome
2. R.A.
3. Upper Cervical Hypermobility
4. Atlanto-Dental Space over 3mm
5. Fracture
6. Arnold-Charri Malformation
7. Basilar Invagination
8. Metastatic Cancer
9. Cerebral Palsy
10. History of Previous Complications to SMT

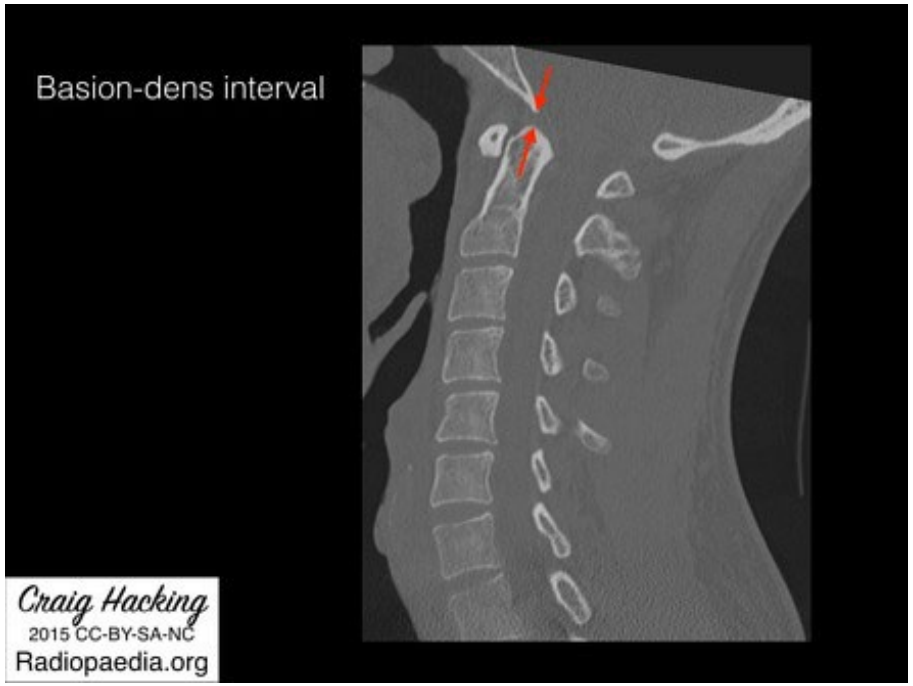

Examination to Prevent Accidents

1. Blood Pressure Measurement
2. Neck Auscultation
3. Does Cervical Rotation or Extension cause S/S

Emergency Care

1. DO NOT Re-Manipulate the Patient's Neck
2. Observe the Patient – Vital Signs
3. Call 911 if S/S do not subside



c

Recommendations for Cervical Spine SMT

- Avoid Risky Procedures
  - Eliminate Cervical Spine Extension and Rotation
- Screen High Risk Patients
- Screen for Previous Complications to SMT

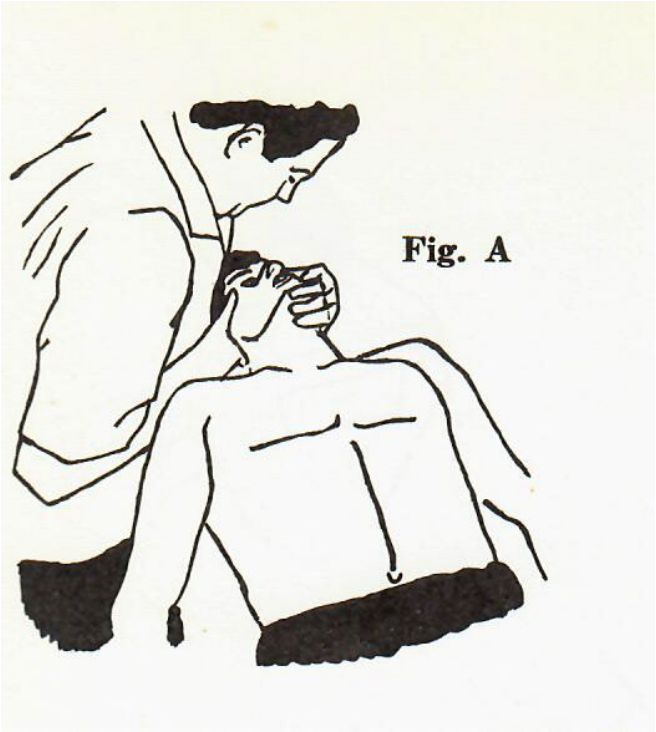

Post Surgery Cases and SMT

1. **Extremities:** Shoulder Rotator Cuff Repair, Carpel Tunnel, Knee Meniscus or Cruciate Ligament
   - Wait 2-3 months before utilizing SMT
   - Utilize "light force" and Physical Therapies: EMS, Laser, PEMF
2. **Abdominal**
   - Wait 4-6 weeks before utilizing SMT
3. **Spinal**

- Wait 3-6 months before utilizing SMT
  Laminectomy – 2-3 months
  Fusion 4-6 months
  - **Review Imaging before Utilizing SMT**

_____Can You Adjust other areas of the spine or Extremities ?

Spinal Injury and SMT

1. **Strain** – Safe to use SMT with Light to Moderate Force
2. **Sprain** – Use "Light Force" for 2-3 months

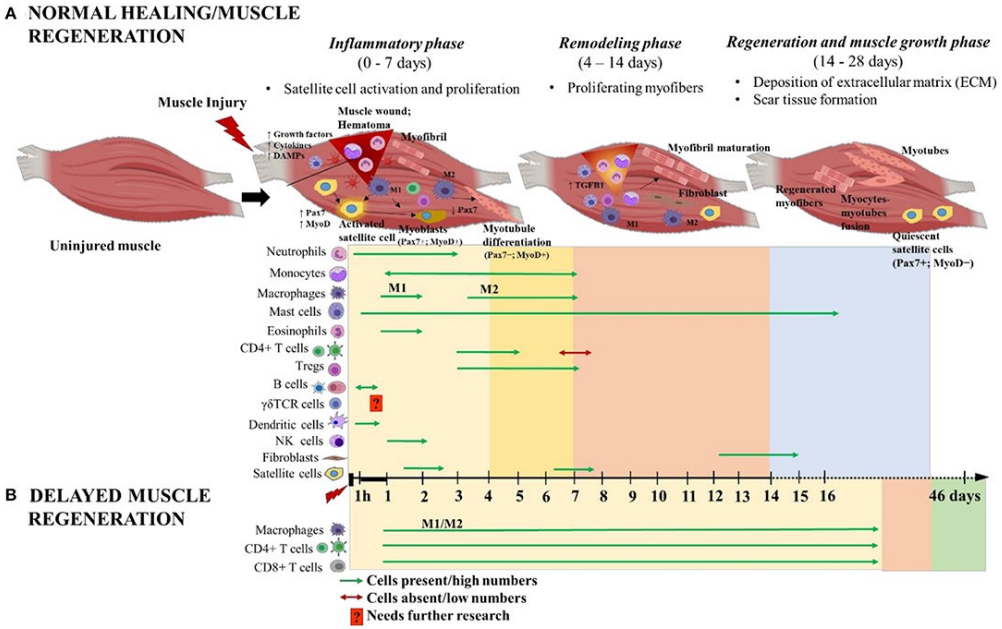

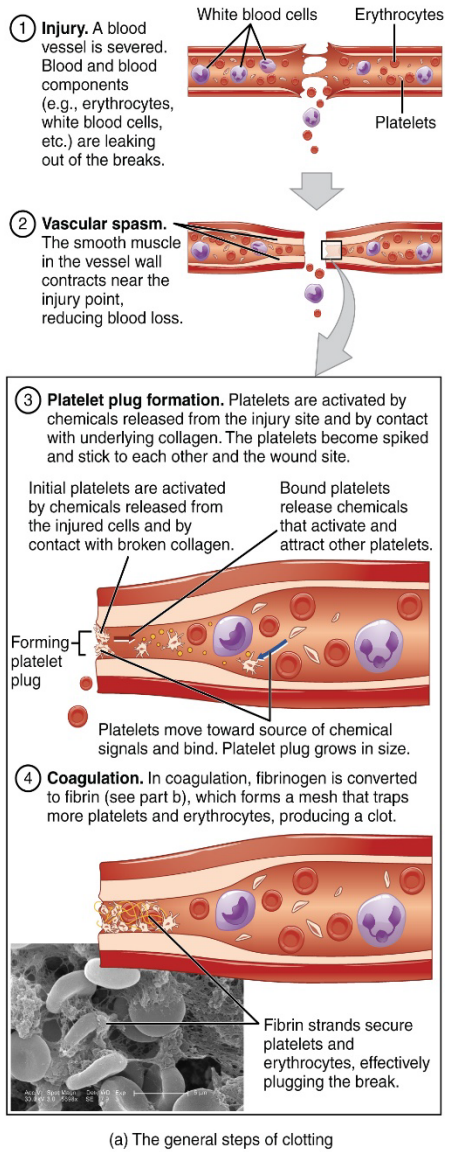

(a) The general steps of clotting

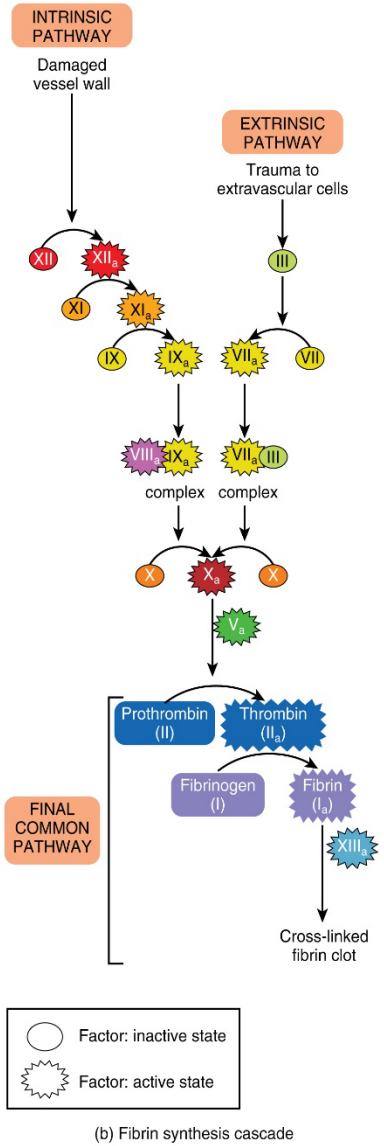

(b) Fibrin synthesis cascade

It's not Force,
It's Finesse that
counts…..

- John Lockenour DC



Key Takeaways

ONE:
It is better not to adjust than to adjust incorrectly

TWO:
It is more important to know when NOT to adjust than when to adjust

THREE:
Avoid Rotation when utilizing SMT

FOUR:
Based your Technique On the Patient's Needs

FIVE:
Know who the High Risk Patients Are

SIX:
First, Do No Harm



Questions ?

